



RESEARCH ARTICLE

EFFECT OF ALISKIREN ON RENAL USING UO MMP-3/TIMP-2 MODEL

1,*Ngueji Kakubu Olivier, ¹Wang Li Min, ²Tshibadi Kushadi Michel, ¹Wang Shu jing,
¹Wang Wen Juan and ²Mufuta Ntambwe Simon

¹Departement of Pediatrics unit II, Fist Affiliated Hospital of Jiamusi University, Jiamusi, China

²Kintambo, General Reference Hospital, Democratic Republic of Congo, Kinshasa, DR. Congo

ARTICLE INFO

Article History:

Received 23rd March, 2017

Received in revised form

04th April, 2017

Accepted 16th May, 2017

Published online 20th June, 2017

Key words:

Renal interstitial fibrosis,
Matrix metalloproteinase-3,
Tissue inhibitor of metalloproteinase -2.

ABSTRACT

Objective: To investigate the effect of aliskiren by expression of matrix metalloproteinase- 3 (MMP-3); Tissue Inhibitor of Metalloproteinase-2 (TIMP-2) on kidney of rats with unilateral ureteral obstruction (UUO). In addition, to explore its action in the process of renal interstitial Fibrosis.

Materials and Methods: 60 male SD rats were randomly divided into sham operation group, model group and treatment group. Model group and treatment group were ligated and the left ureter transection induced the unilateral ureteral obstruction (UUO) model group began treatment after surgery, Aliskiren administered 50mg / kg oral treatment once a day and sham operation group and model group were given the same amount of physiological saline gavage.

After 1 week, 2 weeks; 10 rats of each group were sacrificed respectively, left kidney specimens, do Hematoxylin Oesin (HE) and Masson staining, and by immunohistochemically SABC method to detect renal tissue expression of MMP-3, TIMP-2.

Results: HE and Masson staining: the degree of tubular damage in treated rats was less than model group (P <0.05). Immunohistochemistry showed that in the UUO rat model of renal tissue, the expression of the treatment group with a time point of MMP-3 was higher than the model group, and the expression of TIMP-2 is lower than the model group (P <0.05).

Conclusion: Aliskiren by regulation of the renal tissue MMP-3 / TIMP-2 ratio imbalance may play a renal protective effect in renal interstitial fibrosis process.

Copyright©2017, Ngueji Kakubu Olivier et al. This is an open access article distributed under the Creative Commons Attribution License, which permits unrestricted use, distribution, and reproduction in any medium, provided the original work is properly cited.

Citation: Ngueji Kakubu Olivier, Wang Li Min, TshibadiKushadi Michel, Wang Shu Jing, Wang Wen Juan and Mufuta Ntambwe Simon, 2017. "Effect of Aliskiren on renal using UUO mmp-3/timp-2 model", *International Journal of Current Research*, 9, (06), 51947-51951.

INTRODUCTION

Renal interstitial fibrosis (RIF) is a variety of chronic kidney disease progress to end-stage renal failure, which is a common disease process. Its pathogenesis still unclear, and there is no specific treatment for the renal interstitial fibrosis (RIF) however the existing long course of treatment options are very controversial with many side effects and a poor patient compliance, is a serious threat to children health. Many studies showed that the accumulation of extracellular matrix (ECM) is also the accumulation of fibroblasts, which eventually leads to the formation of fibrosis, the pathological damage of renal interstitial fibrosis and the expression of MMP-3/TIMP-2 in rats after unilateral ureteral obstruction model was related (ZHAO Li-jun et al., 2013). Aliskiren is specific potent renin inhibitors, which can significantly reduce the ang I and reduce plasma renin activity (PRA) (Wu Hongyi et al., 2013).

The renin angiotensin system (RAS) has a role in promoting cell proliferation, inflammation and fibrosis, and plays a significant role in the process of kidney disease, especially in the CKD (Ni Jie et al., 2013). A new RAS inhibitor aliskiren clinical research on renal protection (Angeli et al., 2012 Rashikh et al., 2012) is mainly conducted in diabetic patients. Some studie showed that aliskiren combined with losartan therapy can reduce kidney damage in diabetic patients; the protective effect on the kidneys with aliskiren is independent of its blood pressure lowering effect beyond (Wu Hongyi and Zhou Jingmin, 2013). In recent years, the renin inhibitor, aldosterone receptor antagonist and the effect of multi-drug combination therapy, although have drawn more attention, but aliskiren is a new direct renin inhibitor (DRI), working mainly through the inhibition of the renin catalytic active center, blocking RAS activation from the source. But their clinical data on renal protective effect and its mechanism is not sufficient Clair. The over expression of Tissue Inhibitor of Metalloproteinase-1 (TIMP-1) and the low expression of Matrix Metallo-Protease-9 (MMP-9) are directly involved in the fibrosis of glomeruli and tubule-interstitial (Lee et al., 2006). The recent study of MMP-2, MMP-3, Tissue inhibitor

*Corresponding author: Ngueji Kakubu Olivier,
Departement of Pediatrics unit II, Fist Affiliated Hospital of Jiamusi University, Jiamusi, China.

of metalloproteinase-2 (TIMP-2) pointed out that, the renal rats with unilateral ureteral obstruction (UUO) model occur after interstitial fibrosis and renal tissue damage or may show Matrix Metallo-Protease-3 (MMP -3), Matrix Metallo-Protease-2 (MMP-2) and Tissue Inhibitor of Metalloproteinase-2 (TIMP - 2) expression imbalances (Azizi *et al.*, 2006). Authors Studies indicated that renal interstitial fibrosis (RIF) is the essence of the extracellular matrix (ECM) in glomeruli and renal interstitial, with I, III, IV collagen, fibronectin (FN), laminin (LN) and other abnormal accumulation lead to kidney damage. In addition, the TGF- β 1-Smad signaling pathway, ERK/p38 MAPK signal transduction pathway, controlled proteolytic signaling pathways, such as Wnt, Hedgehog, Notch, NF-KB and other signaling pathways, can use the differentiated cells by affecting neighboring and participate progression of renal fibrosis (Lee *et al.*, 2006) Likewise studies shows, the Reactive Oxygen Species (ROS) through activation of Protein Kinase C (PKC) pathway, causing activation of Transforming Growth Factor- β 1 (TGF- β 1), and Mitogen-Activated Protein Kinase (MAPK) pathway so that NF-KB, AP-1-phosphate, destroy the balance of synthesis and degradation of ECM remodeling caused by renal Extra-Cellulaire Matrix (ECM), causing renal fibrosis imbalances (Azizi *et al.*, 2006). The functional disorder of Tissue Inhibitor of Metalloproteinase (TIMPs) / Matrix Metallo-Protease (MMPs) in renal fibrosis is caused by different causes. The imbalance of the proportion can promote the development of renal fibrosis. We use unilateral ureteral obstruction (UUO) rat models, to observe the effect of aliskiren on Matrix Metalloproteinase-3 (MMP-3) and Tissue Inhibitor of Metalloproteinase-2 (TIMP-2), to find out its impact, to explore its mechanism of protective effect in the process of renal interstitial fibrosis which has not yet been reported and to provide a new treatment method for the treatment of renal fibrosis.

MATERIALS AND METHODS

Animals and Grouping

In 4 week, 60 old male SD juvenile rats, weighing (150 ± 50 g), provided by the Laboratory Animal Science Department of Harbin Medical University, experimental animal license number: SCXK (black) -2013-0001. The Feeding room temperature control at 20~22°C, keep the feeding room quiet, clean and ventilated, given daily rat standard feed and water. Were randomly divided into three groups such as sham group, model group and treatment group, each group had 20 rats. The sham group was looking at the left ureter after free treatment only, without doing ligation and transection. But in the model and treatment groups intraperitoneal injection of anesthesia were done with 10% of chloral hydrate (0.4ml / 100g), at fixed position on the operating plate respectively, using iodine and 75% of alcohol conventional disinfection, under sterile condition on the back left side of the spine 1.5cm. At the lower left rib cage 1cm longitudinal incision was made, turned skin incision, subcutaneous tissue, blunt dissection of muscle was cut after opening the peritoneum, along the lower pole of the left kidney looking at left ureter, with a glass minute lift left ureter and hold free, under the left kidney pole close to the proximal ureter ligation, ligated distal ureteral disarticulation from the middle was sutured and disinfected. From the beginning after every treatment group were given by Aliskiren 50mg/kg oral treatment, sham operation group and model group were given the same amount of normal saline.

Respectively after 1 week, 2 weeks, in each group were sacrificed 10 young rats, left kidney specimens, with 10% neutral formalin fixed after fully embedded in paraffin and set aside.

Reagents and Pathology staining

Rabbit of polyclonal anti-rat antibody Matrix Metalloproteinase-3 (MMP-3), Tissue Inhibitor of Metalloproteinase-2 (TIMP-2), immunohistochemistry kit and DAB color Boster kit from Wuhan Boster Biological Engineering Co, and Aliskiren from Qingdao Shi Jie Kang Biotechnology Limited were purchased. Kidney tissues were fixed, dehydrated, embedded in paraffin, cut into 3 μ m thick tissue specimens stained with Hematoxylin & Eosin (HE) to evaluate the degree of renal tubular interstitial injury and also through improved Masson trichrome staining, tubular damage and renal interstitial fibrosis were observed.

Analysis pathology of renal tubular

By pathological HematoxylinOesin (HE) and Masson staining, at high magnification-X400, each biopsy without glomeruli were randomly cut 10 non-overlapping field of vision, in parts of the cortex and by HematoxylinOesin (HE) pathological observation in the renal cortex damage tubules (including the expansion of the renal tubules, collapse, necrosis or atrophy), as a percentage of the total number of tubular damage number indicates the degree of renal tubular damage within the time point of renal tubules. Through inter-Masson staining quality fibrosis, where the green zone is fibrosis.

Immunohistochemistry staining and analysis

SABC conventional method using a fixed paraffin renal tissue slice dewaxing hydration, antigen retrieval after dropping an appropriate proportion of diluted primary antibody (MMP-3: 1: 100, TIMP-2: 1: 150) and incubated overnight at 4°C in a refrigerator, DAB color, expression of each factor were mounted after observation; phosphate buffered saline (PBS) instead of the primary antibody blank. At magnification – X400, each slice randomly selected among 10 tubulointerstitial vision, positive regional of DAB color may appear contrasting brown (or homogeneous granules) for the specific positive reaction. Image analyzer for analysis of the selected image, calculate the cumulative optical density value of each factor positive expression were used (IOD).

Statistical analysis

All data obtained as mean \pm standard deviation, and the use of statistical analysis software SPSS17.0, Using multivariate ANOVA single factor analysis of variance was used to compare the same time point after a one week and two weeks after surgery between the paired t test, and P <0.05 was considered statistically significant.

Ethic consideration

Before proceeding to our study, the research protocol was submitted to the Staff of the First Affiliated Hospital of Jiamusi University for Approval and consent was given. It was after informed consent of the director of research and education that we preceded with this study. There were no

biases and we did not modify the usual practice of investigations and the ethics were judiciously considered.

RESULTS

Renal tubular of rat and interstitial pathological changes

An optical examination of microscope showed that the sham group tubular structure was intact, no obvious inflammatory cell infiltration, no edema change without lumen dilation and interstitial after 1 week and after 2 weeks. On the model rat group, one week after, the model rats showed an apparent at all levels of renal tubular dilation, and some tubular epithelial with cell vacuoles degeneration, inner portion of the tubular lumen scattered epithelial cells and protein casts off, widened interstitial more visible inflammatory cells. After 2 weeks, the model rat group showed a visible proximal and distal tubules and collecting duct into the cystic dilatation, serious damage to the structure of tubular lumen collapse, renal interstitial inflammatory cell infiltration (figure 1). The extent of damage in difference of time to the same point on tubular was statistically significant between experimental groups ($P < 0.05$). After 1, 2 weeks the luminal damage and increased collagen fibers were not found to be statistically significant. In the model group after 7 days the lumen damage, interstitial hyperemia and extended time with obstruction were clearly observed. After 2 weeks of the visible damage the large lumen structure were light green stained collagen fibers; kidney tissue in rats treated tubular structural damage and fiber proliferation was significantly reduced compared with the model group at the same time (Figure 2).

Experimental expression of TIMP-2 and MMP-3 protein in renal rat tissue at various time points (Table 1)

An examination under light microscope, the Matrix Metallo-Protease-3 (MMP-3) in the cytoplasm of the distal renal tubular epithelial cells and the glomerular epithelial cells showed a small amount of expression and there was no statistically significant change at each point in time ($P > 0.05$).

The model group expression of Matrix Metallo-Protease-3 (MMP-3) with the degree of obstruction increase reduced expression, the expression of Matrix Metallo-Protease-3 (MMP-3) in each time point were higher than the sham operation group ($P < 0.05$); the treated rats kidney tissue Matrix Metallo-Protease-3 (MMP-3) expression with the degree of obstruction increased although showed a decreasing trend, but its expression was still higher than the model group at the same time ($P < 0.05$). In microscopic examination, the Tissue inhibitor of metalloproteinase-2 (TIMP-2) in the sham operation group in renal tubular epithelial cells showed a small amount of expression. There were no expression in glomerular; tissue inhibitor of metalloproteinase-2 (TIMP-2), in the model group there were expressions in renal tubules at all levels. The expression with the obstruction time prolonged presents growth trend, at each point in time in the model group, the renal expression of Tissue inhibitor of metalloproteinase-2 (TIMP-2) were of high quality than in the sham operation group ($P < 0.05$). The expression of Tissue inhibitor of metalloproteinase-2 (TIMP-2) in the treatment group decreased with the prolonged time of obstruction, although showing a growth trend, but compared with the model group at the same time, the TIMP-2 expression decreased significantly ($P < 0.05$).

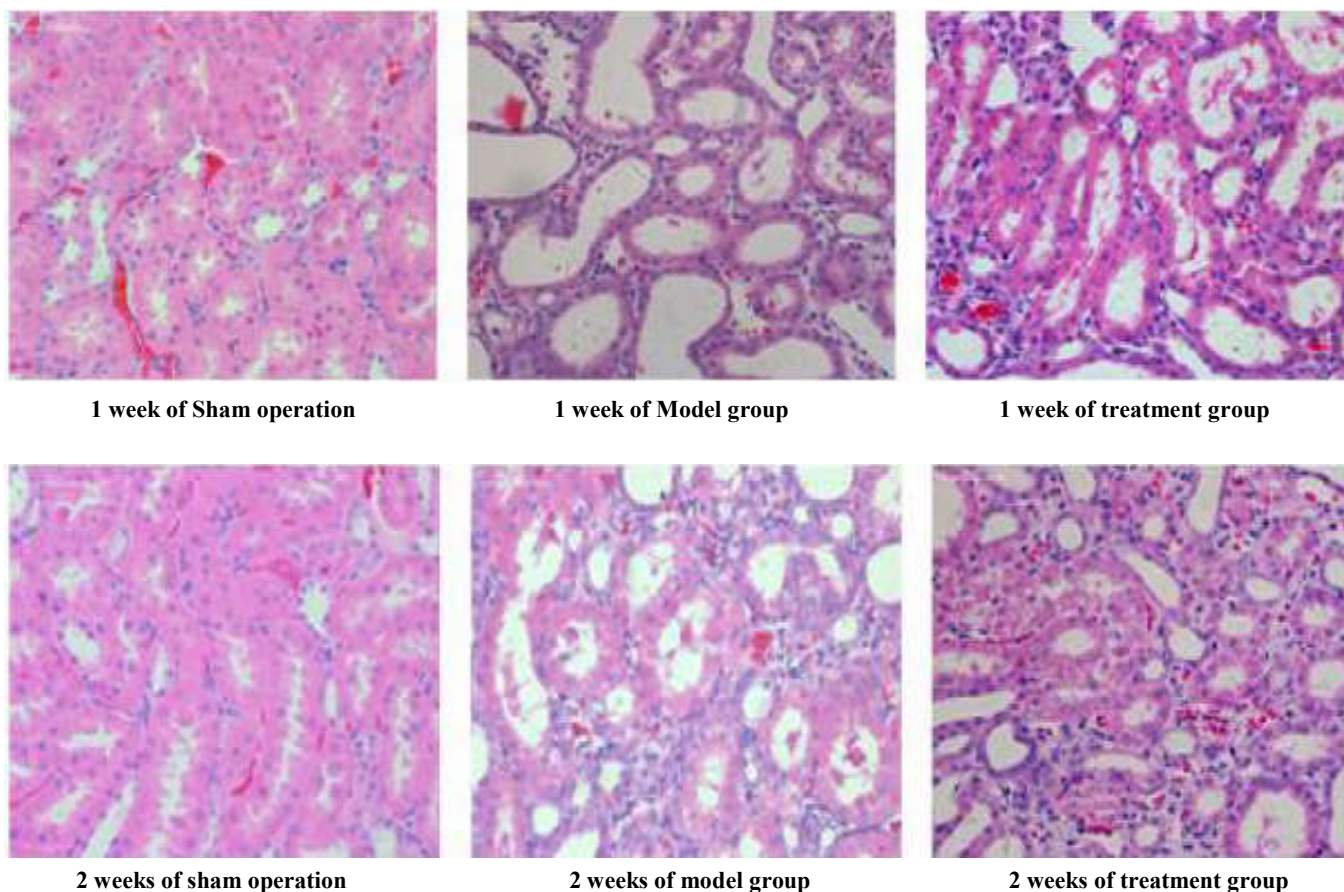


Figure 1. HE Changes of renal tubule in the model group and in the sham operation group of rats in -X400

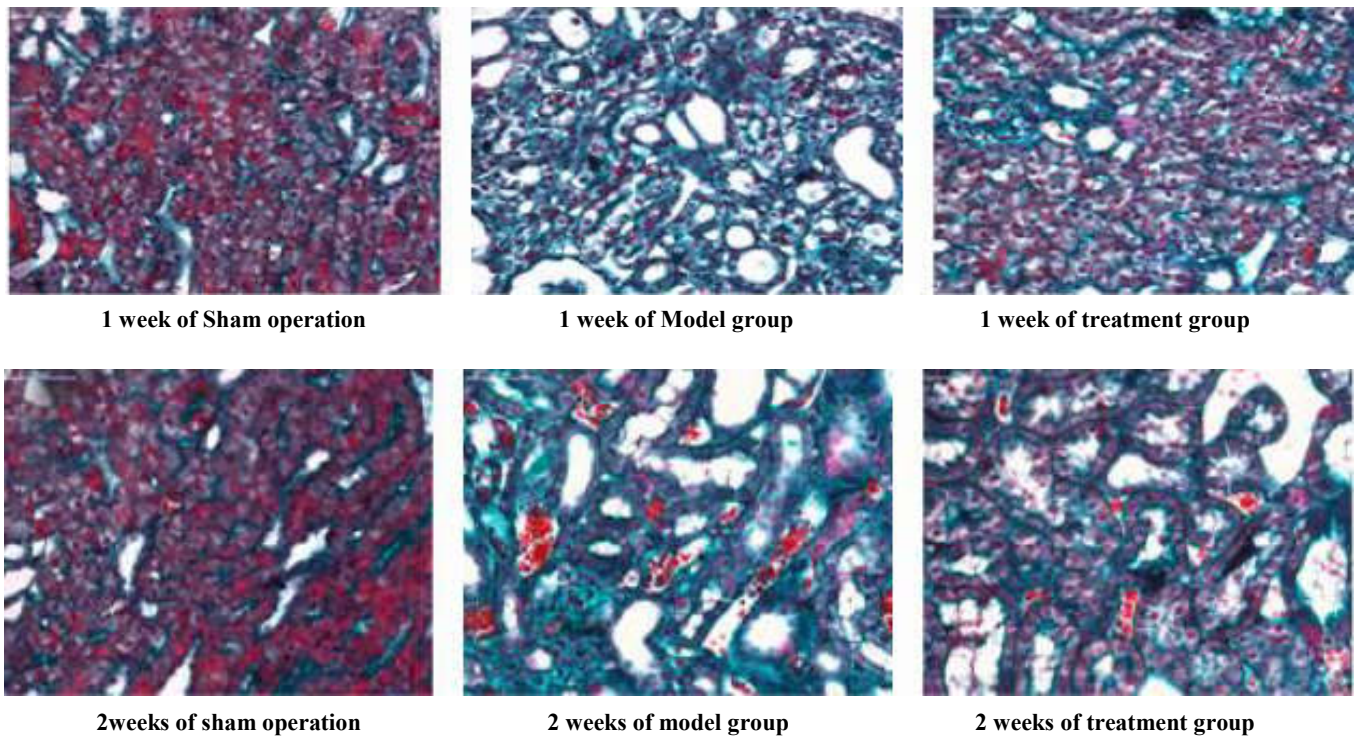


Figure 2. Masson the changes of renal tubular and interstitial fibrosis in the sham operation group, model group and treatment group at each time point -X400

Table1. The expression of MMP-3 and Tissue inhibitor of metalloproteinase-2 (TIMP-2) in renal tissue of each experimental group at different time points ($P < 0.05$)

Group	MMP-3				TIMP-2			
	1week	2weeks	<i>t</i>	<i>P</i>	1week	2weeks	<i>t</i>	<i>P</i>
Operation	23.62±2.36	24.10±2.90	0.41	0.69	12.96±2.20	13.94±2.37	0.81	0.42
model	48.89±4.20	34.55±2.87	7.60	0.00	65.72±2.80	69.53±2.90	3.45	0.00
treatment	53.07±1.66	45.70±1.69	8.24	0.00	45.20±2.48	51.04±2.40	6.67	0.00

DISCUSSION

In the renal fibrosis, the Renin Angiotensin System (RAS) plays a very important role, it can activate inflammatory factors and promotes fibrosis (Zeisberg *et al.*, 2003), therefore, angiotensin converting enzyme inhibitors and angiotensin II receptor blocking agent is arguably the prevention and cure of renal fibrosis in the first-line drug (Herrero-Fresneda *et al.*, 2006). Angiotensin II (Ang II) is an active source of Renin Angiotensin System (RAS), its receptor AT1 can regulate the expression of profibrotic factors, while AT2 can promote the progress of inflammatory cells and accelerate renal fibrosis. Aliskiren can activate a direct inhibition of renin angiotensin system (RAS) from the source, reduce generation of Ang and the inhibition effect, at the same time the pathway of the generation is reduced by ACEI or ARB drugs produced by Ang1 accumulation, to avoid "Ang II Escape" phenomenon (Berman *et al.*, 2006). On the other hand (Kerkela *et al.*, 2006) others authors giving different doses of aliskiren in ischemia reperfusion rat model and Kyrgyzstan after the treatment, aliskiren can reduce the levels of AT2 decrease renal damage, improve the molecular pathology of renal tissue and biochemical changes (Boffa *et al.*, 2013), indicating that aliskiren was involved in the treatment process at the same time in order to avoid the increase of AT2 induced by ARB, the protective effect of it in renal fibrosis may be better than that of ACEI and ARB.

In this experiment, it was observed at all levels where renal tubular expansion can appear, obvious obstruction of model group rats after 1 week, part of the renal tubular epithelial cells expressed vacuolar degeneration of epithelial cells and protein sheddings were a bit visible with some parts of the tubular lumen. Obstruction after 2 weeks it was observed at all levels of renal tubular expansion became cystic, serious damage to the renal tubules, lumina collapse, kidney matter in a large number of inflammatory cell infiltration. At the same time, the treatment group in renal tissue of rats with renal tubular damage and the qualitative decrease of the fibrosis degree that Ligillen can inhibit the progression of renal fibrosis and reduce the damage of renal tubule, this previous studies consistent (Volpini *et al.*, 2004). The Matrix Metallo-Protease (MMPs) and tissue inhibition of tissue inhibitor of metalloproteinase (TIMPs) is one of the regulation of Extra cellular matrix (ECM) homeostasis of the most important enzymes. The previous studies found that the tissue inhibitor of metalloproteinase (TIMPs) increases, inhibit the activity of MMPs resulting in deposition of Extra cellular matrix (ECM) caused by imbalance of MMPs/ tissue inhibitor of metalloproteinase (TIMPs) proportion, this is leading to the important reasons of the occurrence and development of renal fibrosis. In recent years, (ZHAO Li-jun *et al.*, 2013) Study found that the expression of MMP-3/Tissue inhibitor of metalloproteinase-2 (TIMP-2) imbalance and renal interstitial fibrosis is closely related to the occurrence of others study

(ZHAO Li-jun *et al.*, 2013), at the same time, as the TIMP-2 in the short term prediction of AKI factor were shown to trigger tubulointerstitial fibrosis and injury, promote the progression of the disease to factor (De Jesus Soares *et al.*, 2006; Shihab, 2007). This method through the experiment of immunohistochemistry, found expression in renal tissue of model group rats were observed in Matrix Metalloproteinase-3 (MMP-3) and TIMP-2, enhance the expression of renal tissue of the rats in the model group of Matrix Metalloproteinase-3 (MMP-3) in the obstruction, and first appeared in the proximal end of the tube straight part and expansion of the distal tubule epithelial cell cytoplasm, with the obstruction time extended, the levels of renal tubules expressed in cytoplasm of epithelial cells in the collecting duct, glomerular epithelial also showed a small expression.

The expression of Tissue inhibitor of metalloproteinase-2 (TIMP-2) with the obstruction time prolonged, the expression of Growth trend and levels of renal tubular epithelial cells and interstitial were expressed, which is consistent with (Shihab, 2007). The study, also found treated rats kidney tissue Matrix Metalloproteinase-3 (MMP-3) expression at the same time, was higher than that of model group and sham operation group. tissue inhibitor of metalloproteinase-2 (TIMP-2) expression was lower than that in the model group at the same time; this shows that aliskiren can significantly increase the expression of Matrix Metalloproteinase-3 (MMP-3) in renal tissue of rats, inhibited TIMP-2 expression, which may play an important role in the adjustment Matrix Metalloproteinase-3 (MMP-3) /Tissue inhibitor of metalloproteinase-2 (TIMP-2) imbalance. Summing up the appeal, aliskiren may through the promotion of Matrix Metalloproteinase-3 (MMP-3) expression, and inhibits the activity of Tissue inhibitor of metalloproteinase-2 (TIMP-2) to adjust the Matrix Metalloproteinase-3 (MMP-3)/Tissue inhibitor of metalloproteinase-2 (TIMP-2) imbalance play the renoprotective, inhibit the occurrence and progression of renal fibrosis. The experiment is limited to the study of kidney tissue in mice and rats, and whether humans have a similar change still needs continued studies to confirm. Next is our small sample size, further research could expand the sample size.

Conclusion

- The expression of Matrix Metalloproteinase-3 (MMP-3) in Unilateral Ureteral Obstruction (UUO) model rats increased first and then decreased with the progression of the disease. The expression sites were mainly in the renal interstitial, renal tubules.
- The expression of Tissue inhibitor of metalloproteinase-2 (TIMP-2) in the renal tissue of Unilateral Ureteral Obstruction (UUO) model rats increased gradually with the prolongation of obstruction time. The expression sites of Tissue inhibitor of metalloproteinase-2 (TIMP-2) were mainly in renal interstitial and renal tubular epithelium.
- Aliskiren may through the promotion of Matrix Metalloproteinase-3 (MMP-3) expression, and inhibits the activity of Tissue inhibitor of metalloproteinase-2 (TIMP-2) to adjust the Matrix Metalloproteinase-3 (MMP-3)/Tissue inhibitor of metalloproteinase-2 (TIMP-2) imbalance that can play the renoprotective role, inhibit the occurrence and progression of renal fibrosis.

REFERENCES

- Angeli, F., Reboldi, G., Mazzotta, G. and al. 2012. Safety and efficacy of aliskiren in the treatment of hypertension and associated clinical conditions. *Curr Drug Saf.*, 7(1): 76-85.
- Azizi, M., Webb, R., and Nussberger, J., et al. 2006. Renin inhibition with aliskiren: where are we now, and where are we going?. *J Hypertens.*, 24(2): 242-256.
- Berman, E., Nicolaidis, M., Maki, R.G., Fleisher, M., Chanel, S., Scheu, K., Wilson, B.A., Heller, G. and Sauter, N.P. 2006. Altered bone and mineral metabolism in patients receiving imatinib mesylate. *N Engl J Med.*, 354, 2006-13.
- Boffa, J.J., Lu, Y., Placier, S., Stefanski, A., Dussaule, J.C. and Chatziantoniou, C. 2003. Regression of renal vascular and glomerular fibrosis: role of angiotensin II receptor antagonism and matrix metalloproteinases. *J Am Soc Nephrol.*, 14, 1132-44.
- De Jesus Soares, T., Costa, R.S., Balbi, A.P. and Coimbra, T.M. 2006. Inhibition of nuclear factor-kappa B activation reduces glycerol-induced renal injury. 19, 439-48.
- Fu Ping, Feng Mei, Zhang Zhu, 2006. Matrine on renal tubulointerstitial MMP-3 and TIMP-1. *Chinese Journal of Integrated Traditional Chinese and Western Medicine*, 7 (2): 80-82.
- Herrero-Fresneda, I., Torras, J., Franquesa, M., Vidal, A., Cruzado, J.M., Lloberas, N., Fillat, C. and Grinyo, J.M. 2006. HGF gene therapy attenuates renal allograft scarring by preventing the profibrotic inflammatory-induced mechanisms. *Kidney Int* 70, 265-74.
- Kerkela, R., Grazette, L., Yacobi, R., Ilescu, C., Patten, R., Beahm, C., Walters, B., Shevtsov, S., Pesant, S. et al. 2006. Cardiotoxicity of the cancer therapeutic agent imatinib mesylate. *Nat Med.*, 12, 908-16.
- Lee, J.M., Dedhar, S., Kallfi, R. *et al.* 2006. The epithelial-mesenchymal transition: New insights in signaling, development and disease. *Cell Biol.*, 172 (7) : 973 -981
- Ni Jie, Ma Kunling and al. 2013. Role of renal renin angiotensin system activation in apolipoprotein E gene knockout mice lipid renal injury. *Chinese Journal of Hypertension*, 3 (22) 236-245
- Rashikh, A., Ahmad, S.J., Pillai, K.K., et al. 2012. Aliskiren as a novel therapeutic agent for hypertension and cardio-renal diseases. *J Pharm Pharmacol.*, 64(4): 469-482.
- Shihab, F.S. 2007. Do we have a pill for renal fibrosis? *Clin J Am Soc Nephrol.*, 2, 876-8.
- Volpini, R.A., Costa, R.S., da Silva, C.G. and Coimbra T.M. 2004. Inhibition of nuclear factor-kappa B activation attenuates tubulointerstitial nephritis induced by gentamicin. *Nephron Physiol.*, 98, p97-106.
- Wang Yan, Zhao Dean, Yang Dasheng, 2007. Expression of matrix metalloproteinase-9 and tissue inhibitor of metalloproteinase-1 in tubulointerstitial fibrosis rats. *Practical Pediatric Clinical Journal*, 22 (5): 345-346,376
- Wu Hongyi, Zhou Jingmin, 2013. Renin inhibitor aliskiren, *Shanghai Pharmaceutical.*, 33,6-9
- Zeisberg, M., Hanai, J., Sugimoto, H., Mammoto, T., Charytan, D., Strutz, F. and Kalluri, R. 2003. BMP-7 counteracts TGF-beta1-induced epithelial-to-mesenchymal transition and reverses chronic renal injury. *Nat Med.*, 9, 964-8.
- ZHAO Li-jun, CUI Jian-jun, LI Xiu-hua, 2013. Expression of MMP-3 and TIMP-2 in renal interstitial cells of UUO rats, *Chinese Journal of Integrated Traditional Chinese and Western Medicine*, 13 (3): 211-215.