

CASE REPORT**HYDATID CYST OF PANCREAS: A CASE REPORT*****Dr. Sonal Jain, Dr. Kirit Jadav and Dr. Pragati Rastogi**

SSG Hospital Baroda, India

ARTICLE INFO**Article History:**

Received 28th May, 2017
Received in revised form
08th June, 2017
Accepted 24th July, 2017
Published online 31st August, 2017

Key words:

Hydatid cyst, Pancreas, Case report.

Copyright©2017, Sonal Jain *et al.* This is an open access article distributed under the Creative Commons Attribution License, which permits unrestricted use, distribution, and reproduction in any medium, provided the original work is properly cited.

Citation: Sonal Jain *et al.* 2017. "Hydatid cyst of pancreas: A Case report", *International Journal of Current Research*, 9, (08), 55686-55688.

ABSTRACT

Primary pancreatic hydatid disease is rare. The diagnosis may be difficult when the presentation is that of an unexplained epigastric mass, despite suggestive of radiological and ultrasonic features. We describe a 32-year-old female in whom the definitive diagnosis was only made on histopathology.

INTRODUCTION

Hydatid disease is a zoonosis caused by the larval stage of *Echinococcus granulosus* which is endemic to regions where stockbreeding and agriculture are a common occupation (Akbulut *et al.*, 2014). These include the Mediterranean region, Africa, South America, Australia, Middle East and India (Sharma *et al.*, 2015). For *Echinococcus granulosus*, dogs are the definitive host whereas sheep and goats are the intermediate host. Man is an accidental dead end host who is infected after consuming vegetables contaminated with dog feces containing Echinococcal eggs (Eckert and Deplazes, 2004). Hydatid cysts can be found in almost any organ of the body but the most common sites are liver (50%–77%), lung (15%–47%), spleen (0.5%–8%), and kidney (2%–4%) (Akbulut *et al.*, 2014). We describe a case which presented with epigastric pain and cystic pancreatic mass.

Case History

A 32 year female patient noticed a swelling in left upper quadrant of abdomen since 20 days. She had no history of abdominal pain, jaundice or fever. There was also no history of loss of appetite or weight loss. On examination the patient was conscious and oriented. Icterus, lymphadenopathy and edema were absent. Examination revealed 8x5cm swelling in epigastrium and left hypochondrium. The swelling was smooth and cystic. The results of systemic examinations were normal. Her pre-operative laboratory investigations including liver

function tests, kidney function tests and chest x ray were within normal range. On ultra sound examination, an approximately 5.9x6.5x6.9cm sized anechoic cystic lesion with post acoustic enhancement and no internal vascularity was noted within the tail of pancreas. Her CT scan revealed a well defined wall enhancing fluid density cystic lesion in body and tail of pancreas. The cyst was 6.5x6.2cm in size with no obvious calcification (Fig 1). All other organs were normal. No additional cystic lesion were seen in any other organ. Open distal pancreatectomy with splenectomy with resection of a segment of transverse colon followed by end to end anastomosis was performed. Resected specimen (Fig 2) send for histopathology was 14x10x7 cm with firm to cystic in consistency and thick wall. On cutting clear fluid came out. On histopathological examination laminated membrane and scolices were seen which suggested hydatid cyst of pancreas (Fig 3) with changes of congestion in spleen. Post operative ELISA for Echinococcal antigen was also positive.

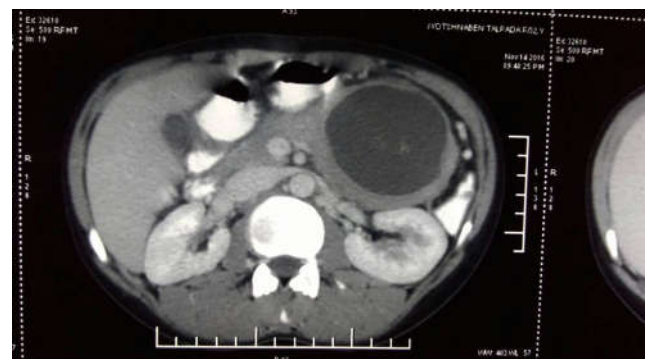

Fig.1. Well defined fluid density cystic lesion with enhancing walls in body and tail region of pancreas

***Corresponding author:** Sonal Jain
SSG Hospital Baroda, India

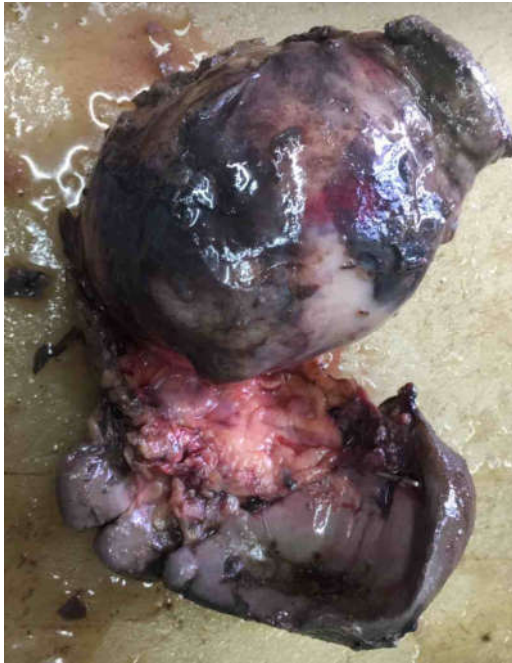

Fig.2. Pancreatic cysts with splenectomy specimen

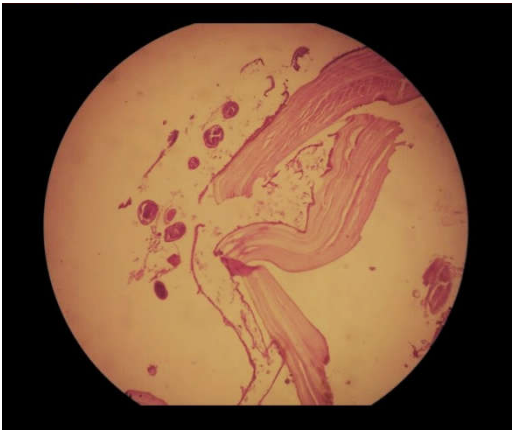


Fig.3. Laminated membrane with scolices

DISCUSSION

Pancreatic hydatid cysts (PHC) are rare entities with incidence ranging from 0.14% to 2% (Shah *et al.*, 2010). PHCs are usually solitary (90%–91%) and distributed unevenly throughout the head (50%–58%), body (24%–34%) and tail (16%–19%) (Akbulut *et al.*, 2014). Clinical presentation depends on the location of the cyst within the pancreas. Cysts located in the head can present as obstructive jaundice due to external compression of the common bile duct and masquerade as a choledochal cyst (Mandelia *et al.*, 2012; Turkyilmaz *et al.*, 2013). Cysts located in the body and tail of pancreas are usually asymptomatic until they become large enough to present as an abdominal lump or cause symptoms due to compression of adjacent structures like epigastric pain, nausea and vomiting (Akbulut *et al.*, 2014; Shah *et al.*, 2010). Rarely, cysts located in the pancreatic tail can result in splenomegaly and portal hypertension (Szant *et al.*, 2010). Complications like cholangitis, rupture into the biliary tree or peritoneal cavity, pancreatic fistula, recurrent pancreatitis and abscess have also been described (Chinya *et al.*, 2015). Imaging modalities commonly employed to diagnose a pancreatic cyst are Ultrasonography (USG), Computed Tomography (CT) and Magnetic Resonance Imaging (MRI). Tests for detecting

specific serum antibodies and circulating echinococcal antigens include indirect hemagglutination assay, immunoelectrophoresis, enzyme linked immunosorbent assay, complement fixation test and immunofluorescence assay (Akbulut *et al.*, 2014). They are useful in follow-up monitoring also. Enzyme-linked immunosorbent assay for Echinococcal antigens is positive in more than 85% of cases (Sbihi *et al.*, 2001; Sayek and Onat, 2001). The characteristic radiological findings described for hydatid cysts are often not present, as in our case (Shah *et al.*, 2010). This makes differentiating PHCs difficult from more common cystic lesions of the pancreas like pseudocysts and benign or malignant cystic neoplasms of the pancreas (Akbulut *et al.*, 2014; Shah *et al.*, 2010). Never the less, PHCs should always be considered in the differential diagnosis of pancreatic cystic lesions in patients from endemic areas.

Open surgery is the treatment of choice (Akbulut *et al.*, 2014; Shah *et al.*, 2010). The diagnosis of pancreatic hydatid cyst is based on historical and geographic backgrounds, physical examination, radiological tools, serology, fine needle aspiration cytology, and histopathological examinations of resected cysts. Serological tests are used for diagnosis, screening, and follow-up for recurrence (Szanto *et al.*, 2010). Several traumatic ruptured splenic cyst hydatid case are encountered in the literature. The cases in the literature almost always are not case report but those are one or more than one case in a case series (Shah *et al.*, 2010). This case, an extremely infrequent encountered is reporting. Splenic hydatid cyst tends to grow and the spleen will be vulnerable to trauma (Shah *et al.*, 2010). Primary hydatid cyst of the pancreas is an extremely rare entity. Our intention in presenting the case is to highlight the fact that hydatid cyst can masquerade as more common cystic lesions of the pancreas. Physicians who have not encountered a pancreatic hydatid cyst may not consider it in the differential diagnosis. In patients from endemic areas, a pancreatic hydatid cyst should always be considered in the differential diagnosis.

Conclusion

PHCs can masquerade as more common lesions of the pancreas like pseudocyst or cystic pancreatic neoplasms. PHCs should always be kept in the differential diagnosis in case of cystic pancreatic mass in patients from endemic areas. Serology, Imaging modalities and Cytological examination of cystic aspirate are important but not always diagnostic. Surgical exploration with histopathological examination is the gold standard.

REFERENCES

- Akbulut, S. *et al.* 2014. Hydatid cyst of the pancreas: report of an undiagnosed case of pancreatic hydatid cyst and brief literature review. *World J. Gastrointest. Surg.*, 6: 190–200
- Chinya, A. *et al.* 2015. Isolated hydatid cyst of the pancreas masquerading as pancreatic pseudocyst. *BMJ Case Rep.*, 2015
- Eckert, J. and Deplazes, P. 2004. Biological, epidemiological, and clinical aspects of echinococcosis, a zoonosis of increasing concern. *Clin. Microbiol. Rev.*, 17: 107–135
- Mandelia, A. *et al.* 2012. Pancreatic hydatid cyst masquerading as a choledochal cyst. *J. Pediatr. Surg.*, 47: e41–e44
- Sayek, I. and Onat, D. 2001. Diagnosis and treatment of uncomplicated hydatid cyst of the liver. *World J. Surg.*, 25: 21–27

- Sbihi, Y. *et al.* 2001. Comparative sensitivity of six serological tests and diagnostic value of ELISA using purified antigen in hydatidosis. *J. Clin. Lab. Anal.*, 15: 14–
- Shah, O.J. *et al.* 2010. Hydatid cyst of the pancreas. An experience with six cases. *JOP*, 11: 575–581
- Sharma, S. *et al.* 2015. Endoscopic ultrasound-guided FNA: emerging technique to diagnose hydatid cyst of pancreas. *J. Cytol.*, 32: 211–212
- Szanto, P. *et al.* 2010. Hydatid cyst of the pancreas causing portal hypertension. *Maedica (Buchar)*, 5: 139–141
- Turkyilmaz, Z. *et al.* 2013. Obstructive jaundice resulted from hydatid cyst of pancreatic head. *Hippokratia*, 17: 378–379
