



CASE STUDY

THE AFTER SURGERY OF THE TONGUE CANCER: PULMONARY EMBOLISM - A RARE AUTOPSY CASE OF SUDDEN DEATH

*Nagahisa Matsuyama and Tetsuya Hachiya

Department of Human Anatomy & Pathology, (Co-author), School of Nursing, Japan University of Health Sciences, Sate 1961-2, Sate -City, Saitama Prefecture, 340-0113, Japan

ARTICLE INFO

Article History:

Received 06th March, 2017
Received in revised form
25th April, 2017
Accepted 21st May, 2017
Published online 30th June, 2017

Key words:

Tongue cancer, After surgery, Pulmonary embolism (PE), Deep venous thrombosis (DVT), Sudden death, Forensic autopsy.

ABSTRACT

A male was diagnosed with squamous cell carcinoma on the right side of the tongue and underwent right hemiglossectomy and tongue reconstruction using a skin flap. Walking was initiated 16 days after the surgery, but he developed dyspnea and suddenly died 18 days after the surgery. Autopsy revealed a continuous thrombus from the right ventricle to the pulmonary arteries and fresh thrombi from the pulmonary trunk to the periphery in both lungs. His cause of death was considered to be pulmonary embolism resulting from movement of blood clots that formed after the surgery to the pulmonary arteries.

Copyright©2017, Nagahisa Matsuyama and Tetsuya Hachiya. This is an open access article distributed under the Creative Commons Attribution License, which permits unrestricted use, distribution, and reproduction in any medium, provided the original work is properly cited.

Citation: Nagahisa Matsuyama and Tetsuya Hachiya, 2017. "The after surgery of the tongue cancer: pulmonary embolism - A rare autopsy case of sudden death", *International Journal of Current Research*, 9, (06), 52730-52732.

INTRODUCTION

A pulmonary embolus is equivalent to pulmonary embolism (PE), pulmonary artery embolism, and acute pulmonary thromboembolism. PE is a sudden blockage of the pulmonary artery by a blood clot formed in the veins or heart (Kurnicka *et al.*, 2016; Ramesh *et al.*, 2016), mostly (> 90% of cases) in the deep veins of the lower limbs or intrapelvic veins (deep vein thrombosis: DVT) (Piazza *et al.*, 2015; Warwick *et al.*, 2014). DVT and PE are both forms of venous thromboembolism (Piazza *et al.*, 2015; Warwick *et al.*, 2014). When patients are asymptomatic, they develop various conditions such as cardiac arrest occurring simultaneously with the onset of PE (Kurnicka *et al.*, 2016; Ramesh *et al.*, 2016; Piazza *et al.*, 2015; Warwick *et al.*, 2014). The mortality rate due to PE is even higher than that due to acute myocardial infarction. When cardiac arrest occurs simultaneously with the onset of PE, survival is difficult (mortality rate, 52%), and the prognosis is poor. Patients aged >60 years are often affected, and pulmonary infarction (hemorrhagic infarction) occurs in 10-15% of patients with PE (Kurnicka *et al.*, 2016; Ramesh *et al.*, 2016; Piazza *et al.*, 2015; Warwick *et al.*, 2014). PE is often observed after surgeries in the fields of gynecology, orthopedic surgery, and urology

(Meimoun *et al.*, 2016; Kim *et al.*, 2016). However, PE in the field of oral surgery is extremely rare. We report a rare patient who suddenly died of PE after surgery for tongue cancer.

Case report

On July 26, 2015, a male visited the Department of Dental and Oral Surgery and underwent biopsy of a tongue lesion. After pathological examination, a diagnosis of squamous cell carcinoma was made. On September 1, 2015, tracheotomy, right hemiglossectomy, and tongue reconstruction using a free flap were performed under general anesthesia. Sixteen days after the surgery, the patient's condition was stable, and walking was initiated. However, 17 days after the surgery, he complained of dyspnea during walking and subsequently developed cardiac arrest and died.

RESULTS

Autopsy findings

The cadaver was 172 cm tall and weighed 76 kg. The heart weight was 550 g. Mild coronary atherosclerosis was observed (Figure 1). There was a thrombus from the right atrium to right ventricle and further to the pulmonary artery (Figure 2). In each lung (left, 505 g; right, 605 g), there was a fresh thrombus from

*Corresponding author: Nagahisa Matsuyama

Department of Human Anatomy & Pathology, (Co-author), School of Nursing, Japan University of Health Sciences, Sate 1961-2, Sate -City, Saitama Prefecture, 340-0113, Japan.

the pulmonary trunk to the peripheral area (Figure. 3a; b; c). In addition, a thrombus that moved from the lower limb was present from the bilateral common iliac veins to inferior vena cava (Figure 4). There was neither cancer metastasis nor local recurrence. The brain weighed 1,450 g and showed mild basilar artery atherosclerosis. However, other organs lacked findings that can cause sudden death.

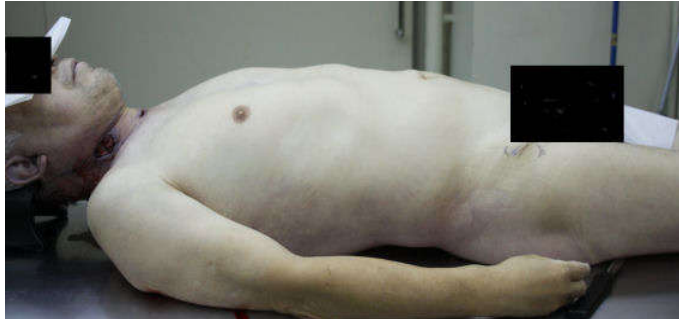

Figure 1. This cadaver, a 62 - years old male cadaver of good nutritional status, body height 172 cm, body weight 76 kg

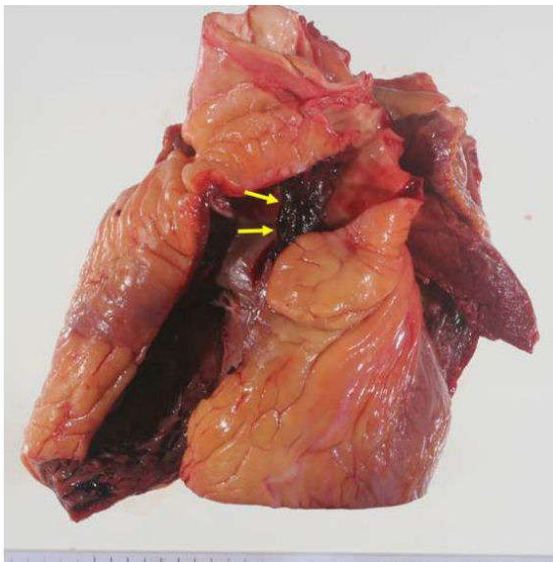


Figure 2. There was a thrombus (arrow) from the right atrium to right ventricle and further to the pulmonary artery

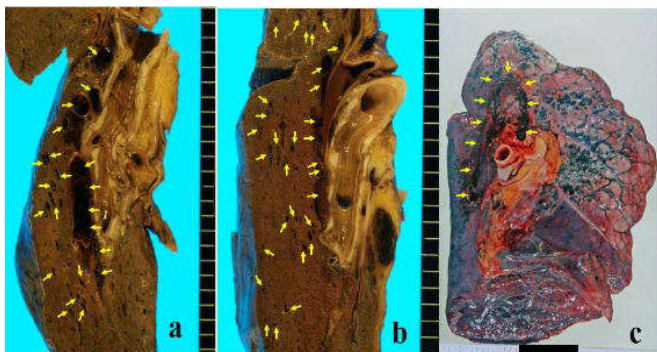

Figure 3. There was a fresh thrombus (arrow) from the pulmonary trunk to the peripheral area

a; The surface of left lung, the fresh thrombus (arrow) was observed in the peripheral pulmonary artery
 b; The surface of right lung, the fresh thrombus (arrow) was observed in the peripheral pulmonary artery
 c; The thrombus (arrow) was observed in pulmonary artery of the left lung

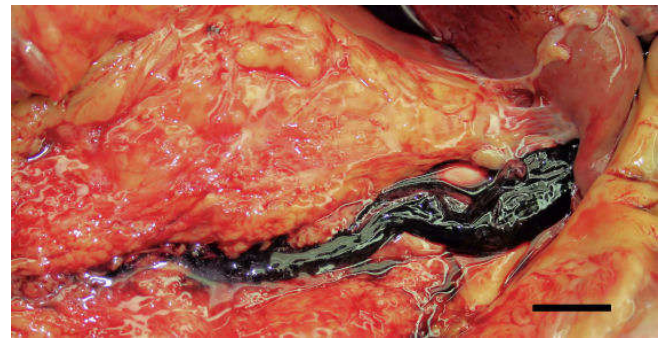


Figure 4. A thrombus that moved from the lower limb was present from the bilateral common iliac veins to inferior vena cava. Bar = 1cm

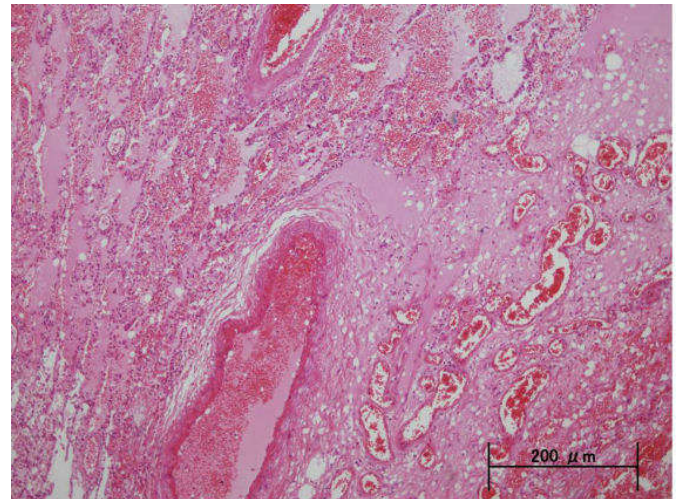


Figure 5. Congestive edema was observed in the inferior lobes of both lungs. HE stain

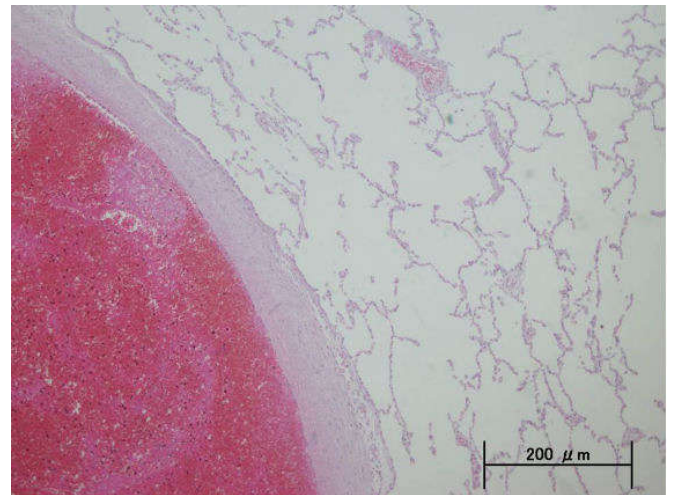


Figure 5. Congestive edema was observed in the inferior lobes of both lungs. HE stain

Histological findings

Congestive edema was observed in the inferior lobes of both lungs (Figure 5). The thrombi were fresh and consisted of erythrocytes and fibrin but showed no organization (Figure 6).

DISCUSSION

In western countries, PE accounts for about 5-10% of all death causes and is recognized as an important common cause of death. In Japan, since its incidence is 0.5-1.7%, being markedly

low compared with western countries, this disease was not considered important (Kurnicka *et al.*, 2016; Ramesh *et al.*, 2016). However, in recent years, PE has also attracted attention as a cause of so-called economy class syndrome. PE as a postoperative complication frequently occurs after surgeries in the departments of gynecology, urology, and orthopedic surgery (Meimoun *et al.*, 2016; Kim *et al.*, 2016; Hamilton *et al.*, 2016) but rarely observed after surgeries in the oral surgery field (Babu *et al.*, 2013; Monnazzi *et al.*, 2012).

The cause of acute PE is DVT in the pelvis or lower limbs in 95% of cases (Moser, 1990). Borow (Borow *et al.*, 1981) reported that DVT was observed on postoperative day 1 in 50% and on postoperative day 2 in 30%, and thrombus formation in the deep veins began during the surgery, being mostly completed within 48 hours after the operation, and was also correlated with the operative time (Piazza *et al.*, 2015; Warwick *et al.*, 2014). In addition, they reported that blood stagnation and promoted coagulation were present due to the influences of general anesthesia and bed rest during the surgery, which could promote the mechanism of thrombus formation (Borow *et al.*, 1981; Fernández *et al.*, 2010). Concerning the cause of PE in this patient, we speculate that his past history of hyperlipidemia and diabetes mellitus and the prolonged bed rest (16 days) after the operation were associated with the development of DVT. This DVT developed after the surgery. When the patient began to walk 16 days after the surgery, thrombi may have traveled due to the pump action of lower limb muscles from the inferior vena cava to pulmonary arteries and finally reached the lungs, resulting in pulmonary thrombosis and sudden death.

Conclusion

A male was diagnosed with squamous cell carcinoma on the right side of the tongue and underwent right hemiglossectomy and tongue reconstruction using a skin flap. Seventeen days after the surgery, he complained of dyspnea during walking and subsequently developed cardiac arrest and died. Autopsy revealed a continuous thrombus from the right ventricle to the pulmonary arteries and fresh thrombi from the pulmonary trunk to the periphery in both lungs. His cause of death was considered to be pulmonary embolism resulting from movement of blood clots that formed after the surgery to the pulmonary arteries.

REFERENCES

- Babu MR, Ramesh C, Thirumurugan K, Prasad GA. 2013. Deep vein thrombosis: A rare complication in oral and maxillofacial surgery: A review of two cases. *Contemp Clin Dent.*, 236-8.
- Borow M. and Goldson H. 1981. Postoperative venous thrombosis. *Am J Surg.*, 245– 251.
- Fernández E, Dueñas N, Villafranca A, Perea M, Amorós B, Bermejo L. 2010. Parturient at full term with inferior vena cava thrombosis: anesthesia during surgical delivery. *Rev Esp Anestesiología Reanim.*, 307-10.
- Hamilton EJ, Green AQ, Cook JA, Nash H. 2016. Investigating for pulmonary embolism in pregnancy: Five year retrospective review of referrals to the acute medical unit of a large teaching hospital. *Acute Med.*, 58-62.
- Kim KK, Won Y, Won YY. 2016. The efficacy of low molecular weight heparin for the prevention of venous thromboembolism after hip fracture surgery in Korean patients. *Yonsei Med J.*, 1209-13.
- Kurnicka K, Lichodziejewska B, Goliszek S, Dzikowska-Diduch O, Zdończyk O, Kozłowska M, Kostrubiec M, Ciurzyński M, Palczewski P, Grudzka K, Kupa M, Koć M, Pruszczyk P. 2016. Echocardiographic pattern of acute pulmonary embolism: Analysis of 511 Consecutive Patients. *J Am Soc Echocardiogr.*, 907- 13.
- Meimoun P, Mesnil Dray P, Clerc J, Luyckx-Bore A, Boulanger J. 2016. Voluminous thrombus straddling the patent foramen oval in the setting of massive pulmonary embolism, treated successfully by surgery. *Ann Cardiol Angeiol (Paris).*, 30315-8.
- Monnazzi MS, Passeri LA, Gabrielli MF, Hochuli-Vieira E, Gabrielli MA. and Pereira Filho VA. 2012. Deep venous thrombosis prophylaxis in oral and maxillofacial surgery: a Brazilian survey. *Indian J Dent Res.*, 519-23.
- Moser KM. 1990. Venous thromboembolism. *Am Rev Respir Dis.*, 235– 249.
- Piazza G. 2015. Beyond Virchow's Triad: does cardiovascular inflammation explain the recurrent nature of venous thromboembolism? *Vasc Med.*, 102-4.
- Ramesh D, Setty HS, Kumar Swamy, Kumar S, Jayanth, Manjunath CN. 2016. Timely embolectomy in acute massive pulmonary embolism prevents catastrophe: An experience from two cases. *J Nat Sci Biol Med.*, 176-9.
- Warwick R, Mediratta N, Chalmers J, McShane J, Shaw M, Poullis M. 2014. Virchow's triad and intestinal ischemia post cardiac surgery.
