



CASE STUDY

PRE-PROSTHETIC MINI-IMPLANT SUPPORTED ORTHODONTIC MOLAR INTRUSION- AN UNCONVENTIONAL APPROACH: A TWIN CASE REPORT

¹Dr. Prathmesh Mehta, ^{*}²Dr. Rishi Bhimani and ³Dr. Anand Badavannavar

^{1,3}Department of Orthodontics & Dentofacial Orthopaedics, KLE Academy of Higher Education & Research (KLE University's) KLE V.K Institute of Dental Sciences, Belagavi

²Department of Periodontics, KLE V.K. Institute of Dental Sciences, Belagavi – 590010

ARTICLE INFO

Article History:

Received 05th March, 2017
Received in revised form
26th April, 2017
Accepted 21st May, 2017
Published online 30th June, 2017

Key words:

Implants,
Intrusion,
Mini-implant,
Temporary Anchorage Device,
Pre-prosthetic orthodontics.

ABSTRACT

Aim: To demonstrate two cases in which mini-implant supported orthodontic molar intrusion has been performed to regain ideal crown height space for implant prosthesis.

Background: Tooth loss is associated with esthetic, functional and psychological consequences on an individual. Replacement of missing teeth by dental implants has gained significant importance due to promising advantages of implants over conventional prosthesis. Edentulism often results in supra-eruption of antagonistic teeth into the edentulous site resulting in reduced vertical dimension for tooth replacement, posing a restorative challenge for clinicians. Hence, it is necessary to regain the lost vertical dimension prior to the implant prosthesis, either conventionally by endodontic and prosthetic intervention or by orthodontic intrusion with the aid of Temporary Anchorage Devices (TADs). Mini-implants are a category of TADs that provide a minimally invasive technique for molar intrusion.

Case description: Two patients with missing mandibular molars, desiring tooth replacement presented with supra-eruption of antagonist teeth, posing a difficulty during prosthetic treatment. Orthodontic intrusion using mini-implants was performed to regain the lost vertical space simultaneously along with dental implant placement followed by prosthetic rehabilitation.

Conclusion: The present twin case report demonstrates the successful role of mini-implants in orthodontic molar intrusion for establishing an ideal crown height space for implant prosthesis to re-establish masticatory function.

Clinical significance: The twin case report demonstrates mini-implant supported orthodontic molar intrusion as a replacement for conventional gross tooth reduction, for regaining the lost vertical space in cases of supra-eruption of maxillary molar associated with edentulism.

Copyright©2017, Vasanthakumari et al. This is an open access article distributed under the Creative Commons Attribution License, which permits unrestricted use, distribution, and reproduction in any medium, provided the original work is properly cited.

Citation: Dr. Prathmesh Mehta, Dr. Rishi Bhimani and Dr. Anand Badavannavar, 2017. "Pre-Prosthetic mini-implant supported orthodontic molar intrusion- An unconventional approach: A twin case report", *International Journal of Current Research*, 9, (06), 52733-52736.

INTRODUCTION

Tooth loss is associated with esthetic, functional and psychological consequences on an individual. Replacement of missing teeth by dental implants has gained significant importance due to promising advantages of implants over conventional prosthesis. Edentulism often results in supra-eruption of antagonistic teeth into the edentulous site resulting in reduced vertical dimension for tooth replacement, presenting a restorative challenge for the clinician. Thus, it necessitates to regain the lost vertical dimension prior to the implant placement, either conventionally by endodontic and prosthetic intervention or by orthodontic intrusion with the aid of Temporary Anchorage Devices (TADs). A temporary

anchorage device (TAD) is a device that is temporarily fixed to bone for the purpose of enhancing orthodontic anchorage either by supporting the teeth of the reactive unit or by obviating the need for the reactive unit altogether, which is subsequently removed after use (Jason B. Cope, 2004). TADs used for molar intrusion are mini implants or zygomatic plate that aid in achieving ideal results maintaining functional occlusion. Mini implants can be used in anterior as well as posterior region to achieve ideal orthodontic results (Profitt *et al.*, 2003). Mini implant supported intrusion helps to regain the lost vertical dimension for the implant prosthesis. Thus, the purpose of this article is to demonstrate two cases in which molar intrusion was achieved using orthodontic mini-implants to regain ideal crown height space for implant prosthesis.

Case description 1

A 27 years old male patient reported with a chief complaint of missing lower left 1st molar (36) and desired for replacement of

*Corresponding author: Dr. Rishi Bhimani,

Department of Periodontics, KLE V.K. Institute of Dental Sciences, Belagavi – 590010

the same. The tooth was extracted 6 months ago due to failed endodontic therapy. On clinical examination, the patient presented with ideal overjet and overbite and a class I molar relationship on the right side and mutilated occlusion on the left side. Upper left 1st molar (26) was supra-erupted reducing the space between the mandibular ridge crest and buccal cusp of 26 to 3.58 mm (Fig 1). For the replacement of 36 two treatment modalities were advised, either dental implant or fixed partial denture prosthesis. The patient opted for an implant prosthesis. Diagnostic casts were prepared and a facebow record was made and the patient was guided in centric relation by bilateral manipulation and the bite record was made using bite registration silicone. The vertical space was measured after mounting the models in centric relation on a semi-adjustable articulator using a digital Vernier caliper (Mitutoyo Absolut, Mitutoyo Corporation, Japan) (Fig 2). The treatment plan included placement of one implant in 36 with simultaneous intrusion of 26 using orthodontic mini-implants.

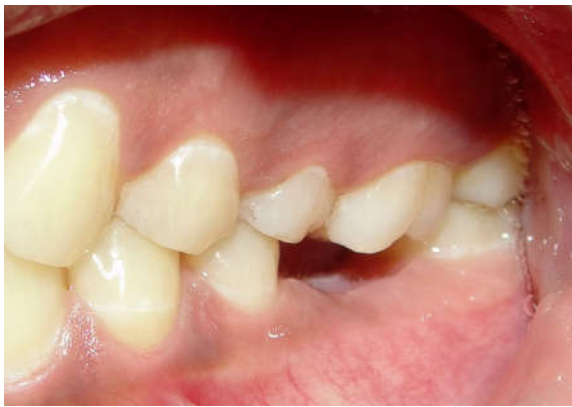

Fig.1. Pre-treatment clinical photograph showing supra-eruption of 26 and reduced crown height space (CHS) for prosthesis placement

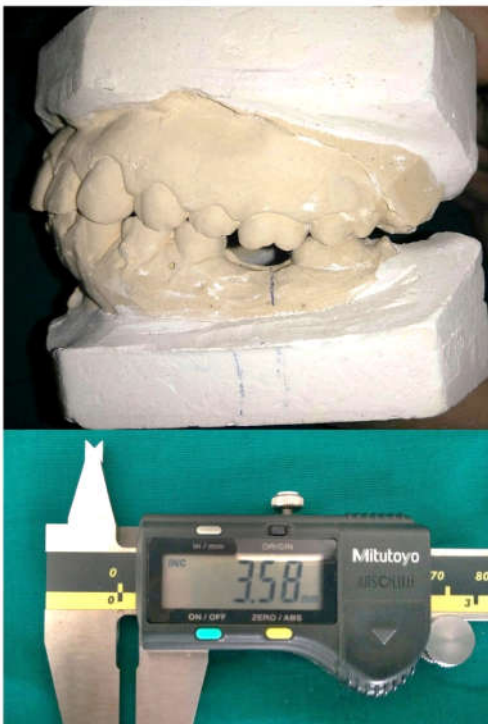


Fig.2. Pre-treatment cast showing CHS reduced to 3.58 mm

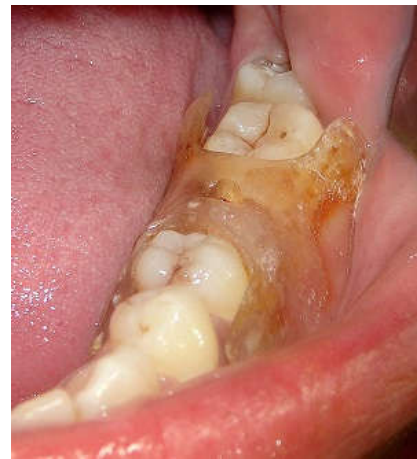

Fig.3. Surgical stent for implant placement

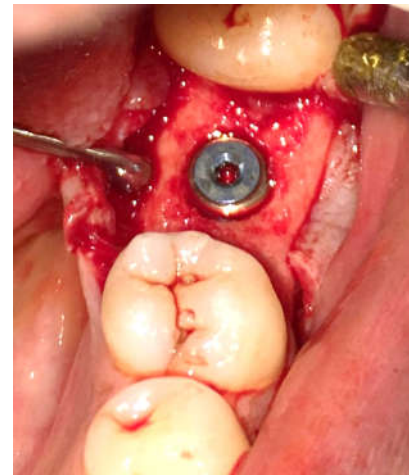


Fig.4. Implant placed in the edentulous site

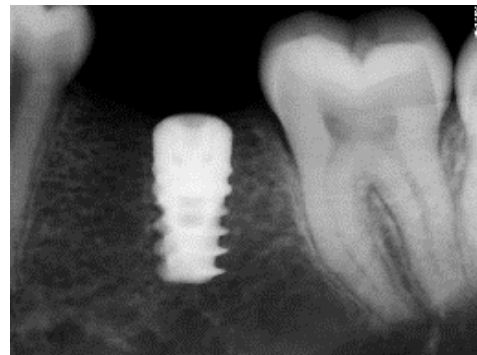


Fig.5. Radiovisuograph with dental implant

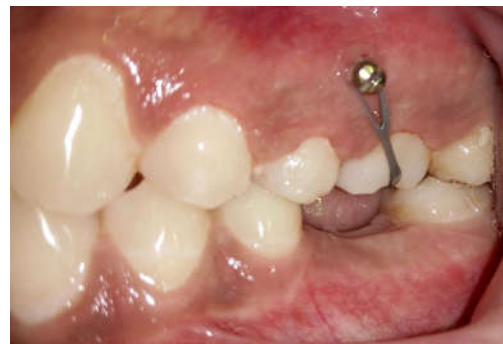

Fig.6. Orthodontic mini-implant with E-chain with evident intrusion of 26

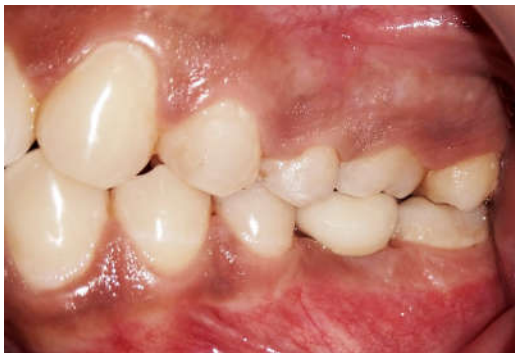

Fig.7. 6 months post crown placement with ideal intercuspation and class I molar relationship

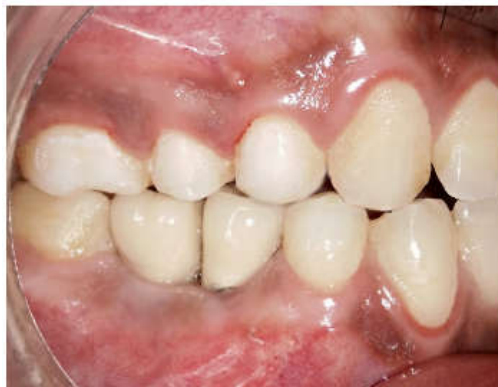
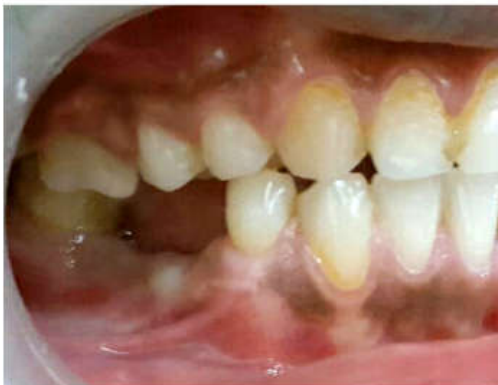
Fig.8. Pre-treatment and post-treatment clinical photograph of case 2

Implant placement in the mandible

Radiographic examination and bone sounding using a bone caliper was done in the region of implant placement. Adequate bone height and width along with soft tissue thickness were present. A surgical stent was prepared to guide the pilot drill into the alveolar crest (Fig 3). A conventional mucoperiosteal flap was reflected and sequential osteotomies with ascending drill diameters were performed. A 5 x 10 mm implant (Noris Medical, Israel) was placed and the flap was sutured (Fig 4). The implant was allowed to osseointegrate for 3 months (delayed loading protocol) (Misch *et al.*, 2004) (Fig 5).

Mini-implant placement in maxilla

One month prior to implant placement in the mandible, mini-implants were placed in the maxillary arch. On the buccal side, a 2 mm x 9mm mini-implant (S.K Surgicals) was placed between 25-26 and palatally, a 2 mm x 6 mm (S.K. Surgicals,

India) implant was placed between 26-27 (Fig 6). The patient was recalled after 1 week to check the stability of the implant. When the implant was stable, a force of 100-150 grams was applied with an E-chain. The force was measured with a Dontrixforce gauge. The patient was recalled every 2 weeks to evaluate the intrusion. A 3.5 mm intrusion was achieved within 3 months with an additional 1 month retention period, to prevent relapse until crown placement in 36.

Final prosthesis

Once the minimum space required for a cement retained implant crown was achieved, a close-tray impression was made using a single stage addition silicone impression material. A metal-ceramic crown was fabricated and cemented. Post-cementation clinical and radiographic follow-ups were done upto 6 months (Fig 7).

Case description 2

A 35 years old male patient reported with a chief complaint of missing lower right 2nd premolar and 1st molar (45,46) and desired for replacement of the same. The teeth was extracted 1 year ago due extensive caries. On clinical examination, the patient presented with edge to edge bite and a class I molar relationship on the left side and mutilated occlusion on the right side. Upper right 1st molar (16) was supra-erupted reducing the space between the mandibular ridge crest and buccal cusp of 16 to 4 mm (Fig 8). For the replacement of 46, either dental implant or fixed partial denture prosthesis was suggested. The patient opted for an implant prosthesis. Similar to the first case, diagnostic casts were prepared and mounted. The treatment plan included placement of two implants in 45, 46 region with simultaneous intrusion of 16 using mini-implants.

Implant placement in the mandible

Similar to the previous case, radiographic examination and bone mapping was done followed by surgical stent preparation. A conventional mucoperiosteal flap was reflected and two implants, 4.2 x 11.5 mm in 45 region and 5 x 10 mm in 46 (Noris Medical, Israel) were placed and the flap was sutured. The implant was allowed to osseointegrate for 3 months.

Mini-implant placement in maxilla

One month prior to dental implant placement in the mandible, orthodontic mini-implants of the same diameter and length were placed in the maxillary arch on the buccal side between 15-16 and on the palatal side between 16-17. The same recall protocol was followed as the previous case. Intrusion of 2.5 mm was achieved in 3 months and a retention period of 1 month was provided, until crown placement.

Final prosthesis

Once the minimum space required for a cement retained implant crown was achieved, impressions were made and metal-ceramic crowns were fabricated and cemented (Fig 8).

DISCUSSION

The crown height space for implant dentistry is measured from the crest of the bone to the plane of occlusion. The minimum crown height space needed for a fixed implant prosthesis

should be 8 mm (Misch, 2013). Critical evaluation of the available restorative space during the diagnostic phase of implant treatment is necessary to determine the available prosthetic alternatives (Abujamra *et al.*, 2000). Attempt to fabricate a prosthesis with inadequate restorative space may result in physiologically inappropriate counter, structurally weak prosthesis and esthetic compromise and/or sub-optimal retention and stability of the treated results (Chaimattayompol and Arbree, 2003). Loss of teeth in the posterior region results in extrusion of antagonist teeth, posing a problem during prosthetic rehabilitation. Hence, correction of this frequently encountered problem is deemed necessary prior to implant prosthesis planning either by conventional gross tooth reduction following endodontic therapy or by orthodontic intrusion with TADs for gaining the lost vertical space. Anchorage is the major concern during orthodontic tooth movement especially in cases where supra-eruption of upper molar occurs into the extraction site. Treating such minor discrepancies with aid of conventional mechanotherapy may lead to anchor loss. With the help of TADs, it is possible to intrude a molar by applying a force from the buccal and palatal side engaging an E-chain with minimal to no anchor loss (Moschos *et al.*, 2007). In the present cases, mini-implants were placed at the level of center of resistance of tooth on both sides which resulted in bodily intrusive movement of upper molar. Orthodontic mini-implants are simple and excellent anchorage devices, demanding less co-operation from patients and provide an opportunity for clinicians to perform desired tooth movements without unnecessarily sacrificing healthy tooth structure of antagonist tooth (Shinde *et al.*, 2015). In the present cases, ideal intercuspation was achieved at the treated sites in centric occlusion. 6 month follow-up showed stable treatment results with a good level of patient satisfaction.

Conclusion

The present twin case report demonstrates the successful role of mini-implants in molar intrusion for establishing an ideal crown height space for implant prosthesis to re-establish masticatory function

Clinical significance

The twin case report demonstrates mini-implant supported orthodontic molar intrusion as a convenient and minimally invasive replacement for conventional gross tooth reduction, for regaining the vertical space in cases of supra-eruption of maxillary molar associated with edentulism.

REFERENCES

- Abujamra NF, Stavridakis MM, Miller RB. 2000. Evaluation of interarch space for implant restorations in edentulous patients. A laboratory technique. *J Prosthodont.*, Jun; 9(2): 102-105.
- Chaimattayompol N. and Arbree NS. 2003. Assessing the space limitation inside a complete denture for implant attachments. *J Prosthet Dent.*, Jan;89(1): 82-85.
- Jason B. Cope, 2004. Temporary Anchorage Devices in Orthodontics: A Paradigm Shift. *Seminars in Orthodontics*, doi:10.1053/j.sodo.2004.11.002
- Misch C.E. 2013. Contemporary Implant Dentistry. 3rd edition. Missouri; Elsevier Publishers.
- Misch C.E. Wanh H.L, Misch C.M, Sharawy M., Lemons J, Judy K.W. 2004. Rationale for application of immediate load in implant dentistry: *Part I. Implant Dent.*, Sep 13(3): 207-215.
- Moschos A. 2007. Papadopoulos, Fadi Tarawneh. The use of miniscrew implants for temporary skeletal anchorage in orthodontics: A comprehensive review. *Oral Surg OralMed Oral Pathol Oral RadiolEndod.*, 103: e6-e15.
- Profitt, W.R., Fields H. W. and Sarver D.M. 2013. Contemporary Orthodontics. 5th Edition. Missouri Elsevier Publishers.
- Shinde P.H., Jain N.V., Duggal R. 2015. Maxillary molar intrusion using Mini-implants to gain vertical space in the antagonist arch for rehabilitation with implant prosthesis: An interdisciplinary approach. *International Journal of Clinical Implant Dentistry*, 1(3): 119-122.
