



CASE STUDY

SERTOLI CELL TUMOR IN A LABRADOR RETRIEVER

*Krishnaveni Narayanan, Bharathidasan, M. and Srikumar, N.

Star Pet Hospital, Kutchery Road, Mylapore, Chennai, India

ARTICLE INFO

Article History:

Received 28th April, 2017
Received in revised form
22nd May, 2017
Accepted 20th June, 2017
Published online 31st July, 2017

Key words:

Sertoli cell, Tumor, Dog, Cryptorchidism.

ABSTRACT

A 7 years old male Labrador Retriever was presented with the history of fast growing enlarged abdominal swelling near the inguinal region for 6 months. On clinical examination, right testis was descended and a mass located near left inguinal region was movable and non-painful. Abdominal plain radiography revealed soft tissue mass on the inguinal region. No metastasis on thorax radiography. Haematology and serum biochemistry values were within the normal range. Fine needle aspiration biopsy confirmed the presence of Sertoli cell tumor in the cryptorchid testis. Surgical excision of the unilateral testicular tumor and the normal descended testis was performed under general anaesthesia. Histopathology of the excised testicular tumor has pale eosinophilic cytoplasm, abundant fibrous tissue stroma and less prominent tubular structure.

Copyright©2017, Krishnaveni Narayanan et al. This is an open access article distributed under the Creative Commons Attribution License, which permits unrestricted use, distribution, and reproduction in any medium, provided the original work is properly cited.

Citation: Krishnaveni Narayanan, Bharathidasan, M. and Srikumar, N. 2017. "Sertoli cell tumor in a Labrador retriever", *International Journal of Current Research*, 9, (07), 54710-54711.

INTRODUCTION

Testicular neoplasms are common in dogs, and their incidence is higher in older animals, and in cases of cryptorchidism. They are benign and rarely metastasize (Argenta *et al.*, 2016). The highest prevalence of testicular tumors was detected in mixed breed dogs, followed by German Shepherds, Collies, Poodles, Golden Retrievers, Cocker Spaniels, German Boxers, Labrador Retrievers and Samoyed (Svara *et al.*, 2014). The occurrence of Sertoli cell tumor may be due to presence of embryological ectopic testicular tissue and testicular tissue transplanted during castration procedure or as a result of trauma to the testis (Sivasudharsan *et al.*, 2017). Sertoli cell is a nurse cell of the testicles that is a part of seminiferous tubules and helps in the process of spermatogenesis. These cells nourish the developing sperm cells through the stages of spermatogenesis and also act as phagocytes to eliminate the residual cytoplasm (Rato *et al.*, 2012). Interstitial cell tumors and Sertoli cell tumors are the most common types of testicular tumors, derived from the sex cord-stromal tumours. Seminoma is the most common type derived from the germ cells. Cryptorchid dogs appear to have a 13.6 times higher risk of testicular tumor than normal dogs. Male dogs with inguinal hernia have an increased risk of testicular tumor (Hayes and Pendergrass, 2006).

Case history and clinical observations

A 7 years old male Labrador Retriever was presented with the history of fast growing enlarged abdominal swelling near the

inguinal region for 6 months. On clinical examination, right testis was descended and a mass located near the left inguinal region was movable and non-painful. Abdominal plain radiography revealed soft tissue mass on the inguinal region. No metastasis on thorax radiography. Haematology and serum biochemistry values were within the normal range. Fine needle aspiration biopsy confirmed the presence of Sertoli cell tumor in the cryptorchid testis.

Treatment and discussion

Animal was pre-medicated with diazepam @ 0.25 mg/kg BW, butorphanol @ 0.2 mg/kg BW, induced with propofol @ 4 mg/kg BW and maintained with isoflurane 3%. Inguinal region and scrotum was aseptically prepared for surgery. An elliptical incision was made over the mass, the tumor mass was exteriorized and resected with the vessel sealer which ensured no haemorrhage (Figure 1). Muscle and sub-cutaneous was closed with absorbable PGA 3-0 using simple continuous pattern. Pre-scrotal castration for the right testis was performed (Figure 2). The resected testicular tumor was apx. 10cm×10cm×7cm (Figure 3) and the right testis were normal in size. Postoperatively, cefotaxime @ 10 mg/kg BW and tramadol @ 2mg/kg BW was given intravenously for 3 days. Oral antibiotics and anti-inflammatory were used for another 3 days. Skin sutures was removed on 10th postoperative day. Histopathology of the testicular tumor revealed pale eosinophilic cytoplasm, abundant fibrous tissue stroma and less prominent tubular structure, which confirmed the sertoli cell tumor (Figure 4). No complications were noticed after surgery.

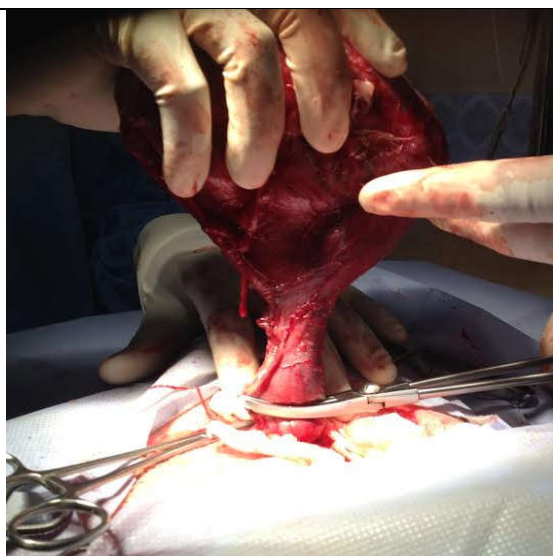


Figure 1. Exteriorized left testicular tumor resecting with vessel sealer

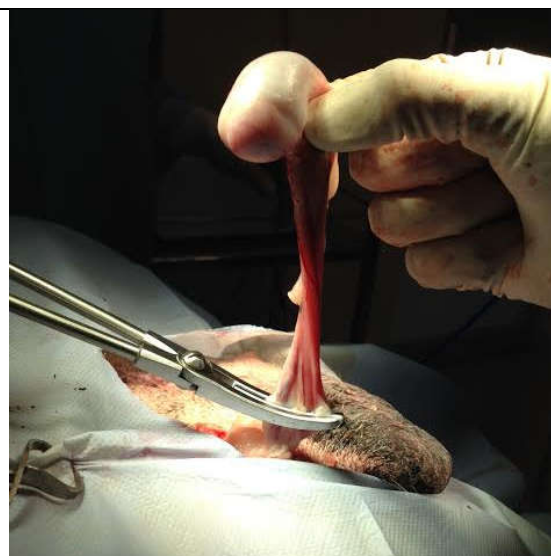


Figure 2. Pre-scrotal castration of right testis

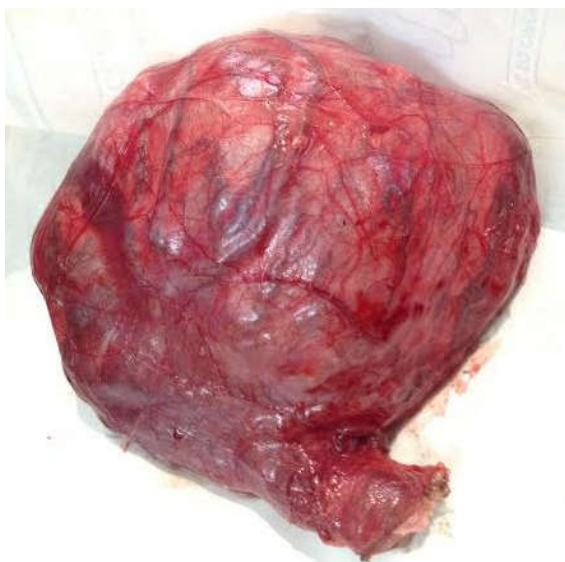

Figure 3. Removed testicular tumor

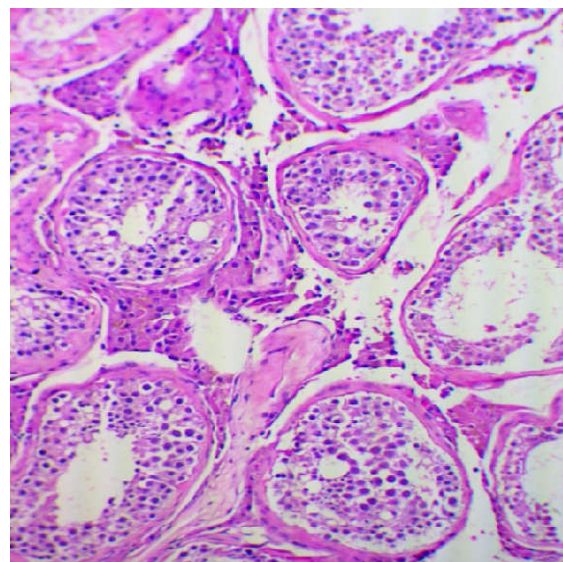


Figure 4. Pale eosinophilic cytoplasm, with abundant fibrous tissue stroma and less prominent tubular structure -Histopatology

Descended testis would not have predilection for cancer development either in the right or the left testis. However, the abdominal and inguinal location of the testis is known to be one of several predisposing factors for the development of testicular tumors, with the right testis more often being retained and predisposed to tumorigenesis but in the present case the tumor was noticed on the left cryptorchid testis. The occurrence of sertoli cell tumor in the cryptorchid testis is much higher than in scrotal testis (Svara *et al.*, 2014).

Conclusion:

Testicular neoplasms are higher in cyrptorchidism. Routine physical examination of the genital system in the growing animals is vital. Early reporting and diagnosis allows early treatment of the condition.

REFERENCES

Argenta, F., P. Paureira, R. A. Caprioli, A. Vielmo, L. Sonnie, S. P. Pavarini and D. Driemeier. 2016. Testicular neoplasms

in dogs in Rio Grande do Sul, Brazil. *Acta Scientiae Veterinariae*, 44:1413

Hayes, H. M. and T. W. Pendergrass. 2006. Canine testicular tumors: epidemiologic features of 410 dogs. *Int. J. Cancer*, 18 (4): 482 – 487.

Rato, Luís, Alves, Marco, G., Socorro, Sílvia, Duarte, Ana I., Cavaco, José, E. and Oliveira, Pedro F. 2012. Metabolic regulation is important for spermatogenesis. *Nature Reviews Urology*, 9(6): 330 – 338.

Sivasudharsan, L., J. Devarathnam, R. Mahesh, G. Kamalalar, K. Rambabu, N. Sumiran and N. Sailaja. 2017. Sertoli cell tumor in a dog – A case report. *Ind J of Can Prac.*, 9 (1): 75 -77.

Svara, T., M. Gombač, E. Pogorevc, T. Plaveč, Petra Zrimšek and M. Pogačnik. 2014. A retrospective study of testicular tumors in Slovenia. *Slov Vet Res.*, 51 (2): 81 - 88.