



CASE STUDY

VACUUM ASSISTED CLOSURE (V.A.C.) DRESSINGS – OUR EXPERIENCE IN A LIMITED RESOURCE SETUP

**Dr. Kailash. R. Gindodia, Dr. Sameer Mahakalkar, *Dr. Aditya A. Manekar
and Dr. Sudarshan B. Thakare**

Department of General Surgery, ACPM Medical College, Dhule

ARTICLE INFO

Article History:

Received 24th May, 2017
Received in revised form
10th June, 2017
Accepted 23rd July, 2017
Published online 31st August, 2017

Key words:

Negative pressure wound therapy,
Vacuum, Diabetes mellitus.

Copyright©2017, Dr. Kailash. R. Gindodia et al. This is an open access article distributed under the Creative Commons Attribution License, which permits unrestricted use, distribution, and reproduction in any medium, provided the original work is properly cited.

Citation: Dr. Kailash. R. Gindodia, Dr. Sameer Mahakalkar, Dr. Aditya A. Manekar and Dr. Sudarshan B. Thakare, 2017. "Vacuum assisted closure (V.A.C.) dressings – Our experience in a limited resource setup", *International Journal of Current Research*, 9, (08), 56515-56518.

ABSTRACT

Since, its introduction in 1990s, vacuum assisted closure (V.A.C.) has been known to reduce the wound healing time along with promotion of granulation tissue as compared to conventional dressing techniques. The therapy involves controlled application of negative pressure to the local wound environment using a sealed wound dressing connected to a vacuum pump. Recent introduction of the commercial products for vacuum dressings have added to enormous costs of these dressings. We at our limited resource setup, provided our patients with a very cheap alternative for the vacuum assisted dressings with the help of locally available materials. We hereby present few of the challenges that our patients posed to us in the course of vacuum assisted closure therapy and how they were handled in our setup with limited available resources.

INTRODUCTION

Vacuum assisted closure (VAC), may also be known as negative pressure wound therapy. This therapy has been a revolution in wound management since last 15 years. Fleischmann *et al.* in 1993 was the first to describe this method. (Fleischmann *et al.*, 1993) Negative pressure wound dressing and moist wound dressings have proven to be very effective in acute and chronic wound treatment, and in many instances it has become the standard of care. However, there are a variety of devices (VAC Therapy, Versatile 1) which claim to provide continuous negative pressure wound therapy (NPWT). (Orgill and Bayer, 2011; Gupta *et al.*, 2007) The basic mechanism of action of negative pressure wound therapy is removal of all collections, serous, pus as well as blood by application of negative pressure over the wound in addition to increasing the blood flow to the wound which helps in faster healing. The major disadvantages in their wide spread acceptance is the high cost, lack of visibility of wound bed during treatment, requirement of special suction machine, maceration of the skin due to the moist environment of the wound, anaerobic infection, foul smell and difficulty in manipulation of wound environment once dressing has been done. The trademarked and copyrighted VAC therapy unit belonging to KCI VAC

(KCI VAC, 2014) needed a sophisticated equipment with drain and a specialized foam and trained personnel for application and maintenance, which is possible at high cost settings. We, at our setup, with limited resources have used locally available materials in wards like plastic leggings, condoms, gloves, balloons, food wraps, Ryle's tube, etc. for the dressings with Ryle's tube/ Suction tubings inserted inside the dressing to deliver the negative pressure wound therapy. We would like to discuss a few of the challenging cases in our study and how they were dealt in our limited resource setup.

MATERIALS AND METHODS

Our study consisted of 20 patients. We selected patients presenting to us in our OPD with non-healing ulcers as well as cellulitis over feet. Patients were thoroughly investigated prior to admission along with radiographs to rule out osteomyelitis and also to rule out malignancy. Any other co-morbid conditions were also looked for. These patients with ulcers underwent thorough debridement till fresh capillary bleeding was seen; after which they were subjected to Negative Pressure Wound Therapy (NPWT).

Method which we used for NPWT

Patients' ulcers or wounds were thoroughly debrided initially under anaesthesia and washed with hydrogen peroxide as well

*Corresponding author: Dr. Aditya A. Manekar,
Department of General Surgery, ACPM Medical College, Dhule

as provide iodine solution. After haemostasis was confirmed, a saline soaked gauze pad was placed over the ulcer, a Ryle's tube was placed over the gauze pad with its openings over the wound. The wound was covered with plastic leggings, generally available as shoe covers in OT (Sterilised by Ethylene Oxide), through which the Ryle's tube was brought outside. The opening of the shoe cover was closed using micropore tape or the sticking plaster available in the wards. Seal was superimposed with petroleum jelly. The other end of the Ryle's tube was connected to the conventional suction machine available in the wards to deliver the NPWT. Seal was confirmed with the rise of the negative pressure inside the leggings.



Figure 1. NPWT dressings and the suction apparatus

We used a pressure generally of about 200 mmHg for the NPWT. The dressings were changed every 5-7 days depending upon the amount of secretions alternating with regular dressing for 1 day to reduce the maceration of the skin. Swabs from the wound for culture and sensitivity were taken before every dressings and antibiotic cover was given accordingly. Instruments used by us for debridement were autoclaved and suction apparatus was timely swabbed for any bacterial growth. Along with the above method, supportive treatment in the form of diabetes control, anaemia correction and dietary support was also given. Depending upon the condition of the wound, the patients were taken for skin grafting or other corrective procedures.

Case 1

A 55-year old non-diabetic female was referred to our hospital for treatment of non-healing ulcer over the right foot with swelling since 10 years. The patient was on antibiotics as well as supportive dressings from a general practitioner. The patient was taken up for thorough debridement where we found maggots in the wound along with ample of necrotic material as

well as slough, which was taken out. Amputation of the necrotic great toe digit was done. Patient was then subjected to NPWT after 48 hours of debridement. Patient was given 3 sittings of the NPWT. Subsequent cultures revealed a sterile culture as a healthy granulation tissue started appearing and wound started improving. Finally skin grafting was done with 100% uptake of graft.

Case 2

A 50 year diabetic female patient was referred to us with a large non healing severely infected ulcer over her right foot for which she was advised amputation at some hospital. The culture and sensitivity report of the swab from the wound showed pseudomonas aeruginosa which was resistant to all antibiotics. There were 2 ulcers, one on the dorsum of foot and other on the plantar surface of the foot, the plantar ulcer being larger, with a significant amount of slough over the ulcer. Patient was started with insulin for blood sugar level control. However antibiotics were not effective due to resistance. Patient was taken for debridement after which NPWT was given to the patient. To increase the efficacy, we instilled the wound with 2% acetic acid (vinegar) and NPWT was given to the patient 1 hour after instillation of vinegar. The wound was subsequently rendered culture negative. The ulcer showed signs of improvement with formation of a healthy granulation tissue after 5 sittings of NPWT. Skin grafting was then done with 100% acceptance of the graft.

Case 3

A 60 year old diabetic male patient presented to our OPD with swelling over left foot along with pain and hyperpigmentation of the skin since 10 days. Patient was on oral hypoglycaemic agents, however diabetes was uncontrolled. The patient was shifted on to insulin, and after controlling the BSL, patient was taken for debridement. Post debridement, patient was sent home with regular conventional dressings and was followed up, however, the conventional dressings failed to show a significant improvement. NPWT was given to the patient who developed a healthy granulation tissue in 2 sittings after which skin grafting was done with 86 % take up of the graft.

Case 4

A 55 year old with uncontrolled diabetes presented to our OPD with an ulcer over right sole of foot. Patient had undergone debridement for ulcer over the foot about a month ago with regular conventional dressings, but to no good result. We subjected the wound to NPWT after which there was formation of the granulation tissue. However, the ulcer being on the dependent part of the foot did not show signs of improvement. We offloaded the wound by giving a cast with a window just to show the ulcer. The ulcer was offloaded and with regular dressing, it showed signs of healing.

Observations

Out of 20 patients, 11 patients were male and 9 patients were females (male to female ratio is 1:1.2). Diabetes being the most important comorbid factor, 14 patients (70%) were diabetic and 6 (30%) patients were non-diabetic. We had excellent results with NPWT with 17 patients (85%) having positive results in terms of granulation tissue formation and acceptance of skin grafts. 2 patients left our study, and one patient having diabetes with peripheral vascular disease underwent amputation.

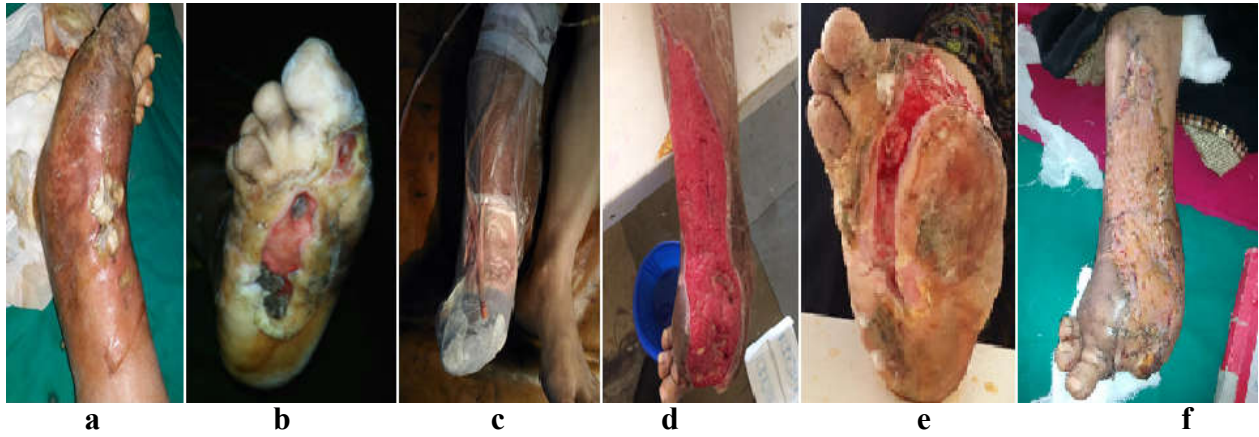


Figure 1. a & b – Clinical photograph when the patient presented to us. c – NPWT given. d – granulation tissue after NPWT. e – the wound over the sole. f – post skin grafting

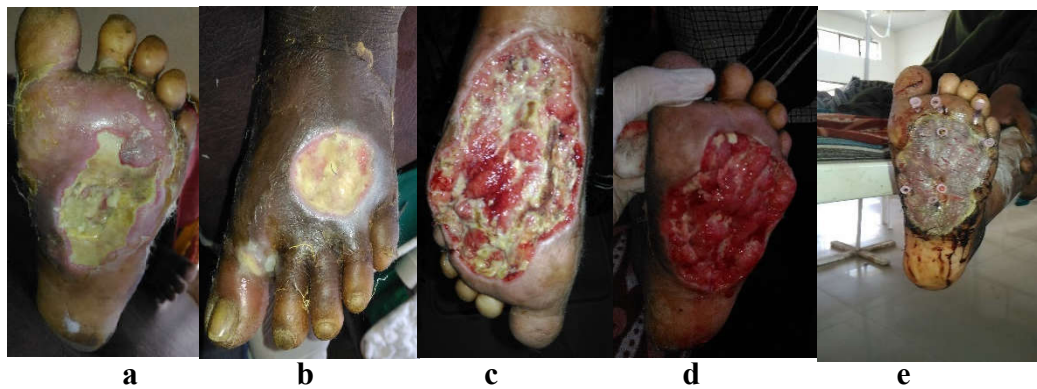


Figure 2. a & b – Clinical photograph of the patient when presented to us. c – After debridement. d – post NPWT. e – after skin grafting

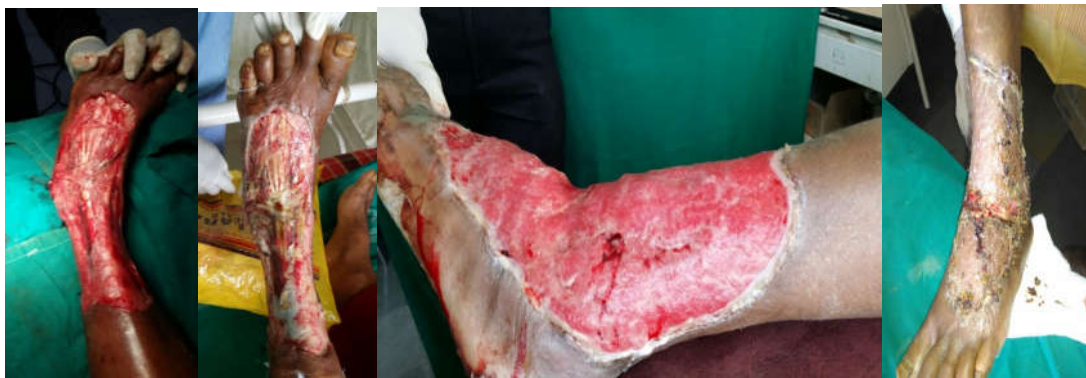

Figure 3. a – the wound post debridement. b – 10 days after conventional dressing. c – after 2 sittings of NPWT. d – post skin grafting

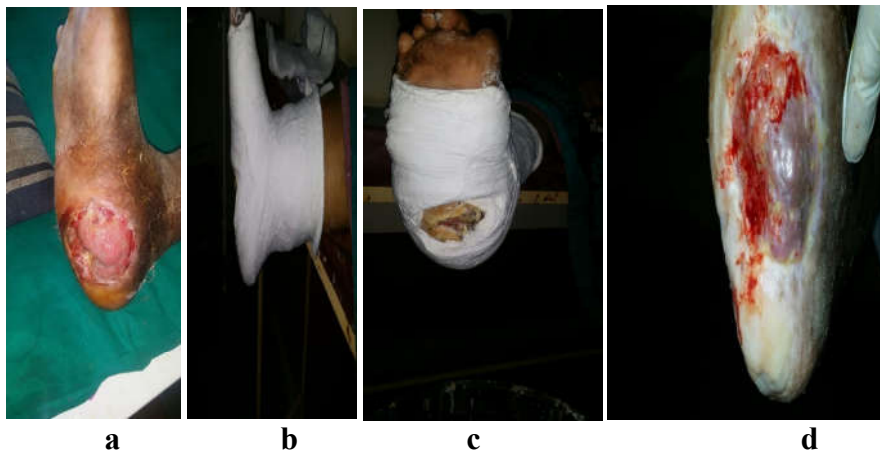


Figure 4. a – clinical photograph of the ulcer. b & c – offloading done

DISCUSSION

Wound healing is a complex interdependent and intricate process involving many cellular interactions, release of biochemical mediators, changes in the microenvironment and extracellular matrix resulting in structural and functional restoration of the wound. (Clarke and Henson, 1988) Locally acting growth factors influence healing in the events of angiogenesis, formation of extracellular matrix, migration of neutrophils, macrophages, fibroblasts, increasing collagen and protein production thereby enhancing the healing of wound. (Laiho and Keski-Oja, 1989; Whitby and Ferguson, 1992) Any disturbance in this mechanism will delay in healing and lead to chronic non healing wounds. Application of sub atmospheric pressure decreases the bacterial colonization over the wound and increases the blood flow. (Argenta and Morykwas, 1997) Increase in oxygenated blood flow to the damaged tissues increases the wound resistance to the infection. (Hunt, 1988) Increased oxygenated blood flow to the wound healing promotes the oxidative bursts in neutrophils and there by promoting the killing of microbes and preventing infection. (Ryan, 1980) Negative pressure therapy decreases the interstitial oedema and increases the capillary blood flow, promotes granulation tissue formation and produces a traction force whereby decreases the wound surface area and increases the mitoticity in cells around the area. (Leininger *et al.*, 2006)

It has been proposed four primary mechanisms for healing by negative pressure therapy

1. Macrodeformation or wound shrinkage at the base
2. Microdeformation near the interface sponge
3. Removal of excess fluid
4. Optimizing the wound environment. (Orgill *et al.*, 2009)

Negative pressure therapy treated wounds in the granulation phase have robust granulation tissue, proliferation of cells, angiogenesis and the maturation of collagen exhibit mast cell dependence in proliferation and remodeling phases. Morykwas *et al.* studies showed a decrease in the bacterial load in wounds treated with negative pressure therapy. (Morykwas *et al.*, 2006) Mouës *et al.* studies showed there is a decrease in non fermentive Gram-negative bacilli and *S. aureus* increased. (Mouës *et al.*, 2004) The effect of negative pressure therapy on bacterial culture from the wounds should be more studied particularly in responses of different strains that are elicited. Traditional VAC dressing's uses polyurethane ether foam, reduction of bacterial load can be achieved in the wound by silver coating added to the foam. Stinner *et al.* study in the goat model with silver dressings placed beneath the foam in complex wounds with high bacterial load demonstrated reduction in bacterial growth particularly *S. aureus* when compared to standard VAC dressings. (Stinner *et al.*, 2001) Instillation therapy adding of fluid to the wound through a tubing in form of normal saline or other antimicrobials like sodium hypochlorite solution, dilute povidone iodine, doxycycline, phenytoin, lactoferrin are done but trials are needed to prove its efficacy. We had excellent results in terms of granulation tissue formation and wound healing in a smaller amount of time than that would be taken by conventional dressings, with the other comorbidities managed adequately.

Conclusion

V.A.C. dressings (Negative Pressure Wound Therapy) coupled with older treatment modalities like acetic acid dressings in cases of difficult wounds with treatment of comorbidities like diabetes, anaemia along with dietary support can accentuate management of even difficult non-healing ulcers.

REFERENCES

- Argenta LC, Morykwas MJ. 1997. Vacuum-assisted closure: A new method for wound control and treatment: Clinical experience. *Ann Plast Surg.*, 38:563-76.
- Clarke and RA, Henson PM, editors. 1988. The Molecular and Cellular Biology of Wound Repair. New York, NY, USA: Plenum Press.
- Fleischmann W, Strecker W, Bombelli M, Kinzl L. 1993. Vacuum sealing as treatment of soft tissue damage in open fractures. *Unfallchirurg*, 96:488-92
- Gupta S, Bates-Jensen B, Gabriel A, Holloway A, Niezgoda J, Weir D. 2007. Differentiating Negative Pressure Wound Therapy Devices: An Illustrative case series. *Wounds*, 19:1-9.
- Hunt TK. The physiology of wound healing. *Ann Emerg Med.*, 17:1265-73.
- KCI VAC, 2014. Available from: <http://www.kci.com/KCI1/educationtraining>. (Last accessed on 2014 Nov 11).
- Laiho M, Keski-Oja J. 1989. Growth factors in the regulation of pericellular proteolysis: A review. *Cancer Res.*, 15:49: 2533-53.
- Leininger BE, Rasmussen TE, Smith DL, Jenkins DH, Coppola C. 2006. Experience with wound VAC and delayed primary closure of contaminated soft tissue injuries in Iraq. *J Trauma.*, 61:1207-11.
- Mendez-Eastman S. 2001. Guidelines for using negative pressure wound therapy. *Adv Skin Wound Care*, 14:314-22.
- Morykwas MJ, Simpson J, Pungler K, Argenta A, Kremers L, Argenta J. 2006. Vacuum-assisted closure: State of basic research and physiologic foundation. *Plast Reconstr Surg.*, 117:121S-6.
- Mouës CM, Vos MC, van den Bemd GJ, Stijnen T, Hovius SE. 2004. Bacterial load in relation to vacuum-assisted closure wound therapy: A prospective randomized trial. *Wound Repair Regen.*, 12:11-7.
- Orgill DP, Bayer LR. 2011. Update on negative-pressure wound therapy. *Plast Reconstr Surg.*, 127(Suppl 1):105S-115
- Orgill DP, Manders EK, Sumpio BE, Lee RC, Attinger CE, Gurtner GC, *et al.* 2009. The mechanisms of action of vacuum assisted closure: More to learn. *Surgery*, 146:40-51.
- Ryan TJ. 1980. Microcirculation in psoriasis: Blood vessels, lymphatics and tissue fluid. *Pharmacol Ther.*, 10:27-64.
- Stinner DJ, Waterman SM, Masini BD, Wenke JC. 2011. Silver dressings augment the ability of negative pressure wound therapy to reduce bacteria in a contaminated open fracture model. *J Trauma.*, 71:S147-50.
- Whitby DJ, Ferguson MW. 1992. Immunohistological studies of the extracellular matrix and soluble growth factors in fetal and adult wound healing. In: Adzick NS, Longaker MT, editors. Fetal Wound Healing. New York, NY, USA: Elsevier Science; p. 161-77.