



## RESEARCH ARTICLE

### LIGATION OF THE WIRE: CLINICAL UPDATE

**\*<sup>1</sup>Dr. Stephen Chain, <sup>2</sup>Dr. Vaibhav Vashishta, <sup>3</sup>Dr. Sulabh Grover, <sup>4</sup>Dr. Ankita Singh  
and <sup>5</sup>Dr. Monisha Singhal**

<sup>1</sup>Department of Orthodontics and Dentofacial Orthopedics, Chandra Dental College and Hospital, Safedabad, Barabanki - 225001

<sup>2</sup>Department of Orthodontics and Dentofacial Orthopedics, Sardar Patel Post Graduate Institute of Dental and Medical Sciences, Lucknow-226025

<sup>3</sup>Department of Orthodontics and Dentofacial Orthopedics, Chandra Dental College and Hospital, Safedabad, Barabanki - 225001

<sup>4</sup>Department of Oral Pathology, BBD College of Dental Sciences, Lucknow -227015

<sup>5</sup>Department of Pedodontics and Preventive Dentistry, Chandra Dental College and Hospital, Safedabad, Barabanki - 225001

#### ARTICLE INFO

##### Article History:

Received 09<sup>th</sup> July, 2017

Received in revised form

22<sup>nd</sup> August, 2017

Accepted 15<sup>th</sup> September, 2017

Published online 31<sup>st</sup> October, 2017

#### ABSTRACT

Ligation is adaptation of the wire to the bracket slot in order to move the tooth. Usually Metal or elastics are used for this purpose. A voluminous knowledge is required for the placement of ligatures in order to make better and faster treatment. This article gives an insight to the different ligation technique and each to be applied at given situations for the benefit of the treatment result.

##### Key words:

Ligation, Clockwise, Counterclockwise, "Figure 8 Shape".

Copyright©2017, Stephen Chain et al. This is an open access article distributed under the Creative Commons Attribution License, which permits unrestricted use, distribution, and reproduction in any medium, provided the original work is properly cited.

Citation: Dr. Stephen Chain, Dr. Vaibhav Vashishta, Dr. Sulabh Grover, Dr. Ankita Singh and Dr. Monisha Singhal, 2017. "Ligation of the wire: Clinical update", *International Journal of Current Research*, 9, (10), 59818-59825.

## INTRODUCTION

Ligation is the key in Orthodontics. The adaptation of the wire on the bracket makes the appliance active and helps the tooth to move with proper ligation technique. One could express different movements and to improve control over the position of paralleling roots when closing extraction spaces and to achieve more efficient correction of rotation. (Faber, 2000) These are widely used in current Orthodontics because they exert 3-dimensional control on the tooth movement. For the control of orthodontic tooth movement, Orthodontic archwires must be tied into the bracket slots using metal or elastomeric ligatures or combination of both. For the adaptation of the arch wire either Metal ligatures which are of stainless steel alloy wires of varying gauge (.009 to .014 inch) or circular-shaped elastomers can be used. The ligatures are tied to both wings of the bracket which holds the wire in the bracket slot (Fig 1 & 2).

The wire is usually seated in the slot before application of the ligatures (Dragiff, 1971) but in newer technique, (Kodail *et al.*, 2011; Rammanohar, 2014) it is not followed. The great advantage of elastomeric ligatures is the speed with which the archwire can be fixed in place and removed, however firmer tying is required with metal ligation should be used as ligation of archwires for orthognathic surgery (Proffit and White, 1991) or in special cases. When metal ligatures are used, the tips should be twisted together. The ties may be twisted clockwise or counterclockwise (Dragiff *et al.*, 1967) to ensure firmness. Four or five complete turns of the wire are sufficient to obtain a firm tie. These can be performed by different instruments, including Mathieu needle holders, Steiner or Coon ligature tying pliers, or ligature cutter pliers. Once it has been twisted, the ligature should be cut and tucked to avoid traumatizing the buccal or labial mucosa.

\*Corresponding author: Stephen Chain,

Department of Orthodontics and Dentofacial Orthopedics, Chandra Dental College and Hospital, Safedabad, Barabanki – 225001

## Types of ligation

### Based on the material used

**Metal:** Stainless Steel ligatures are used to tie the wire to the bracket slot (Fig 1a & 1b).

**Elastic:** Elastic or O ring are used to ligate the wire (Fig 2a & 2b).

**Combination:** Both metal as well as elastic are used to adapt the wire to the bracket (Fig 3b).

### Based on the method

#### Basic ligation

Basic ligation can use either metal or elastic ligatures and it is the most common procedure. Tying can be straight (Fig 1a & 2a) (simple tie) (Faber, 2000) or cross arch (Dragiff *et al.*, 1967) (Fig 1b & 2b) ("figure 8 shape" tie). It should be noted that the full adaptation of the metal ligatures are difficult to obtain. The ligature must be secured in order for the full expression of the wire. This can be obtained with the help of an instrument (Fig 4a, 4b, 4c & 4d). Presently orthodontists use the twin bracket, which follows a series of tying to achieve the proper force in relation to correct the rotation of the teeth using this bracket design. The cross arch wire engages the wire in the bracket slot better than the simple tie.

#### Circumferential Ligations (Faber, 2000)

Although the position of rotated teeth can be corrected by basic ligation procedures, circumferential ligations, specifically for correcting rotations, can be used to tie both anterior and posterior teeth. In case of anterior teeth, the ligature threads are attached to the bracket tie wings nearest the archwire. The ligature is then passed through the interdental spaces encircling the tooth on the lingual-palatine surfaces, emerging on the labial side via opposed interproximal spaces for tying on the archwire (Fig. 5) (Dragiff, 1971). In the case of canine and posterior teeth, the same kind of ligation can be used. However, a small retention area can be molded in composite resin or an auxiliary can be placed or soldered onto the lingual-palatine surface to prevent vertical displacement of the ligature wires. The mechanical efficiency of circumferential ligations can be improved by using a combination of ligature wires and elastomeric ligatures on both anterior and posterior teeth. In this case (Fig 6), the ligature thread passes through the elastomeric ligature, which was previously fitted into the part of the twin bracket closest to the archwire. When the metal ligature is tied to the archwire, the elastomeric ligature will be activated. An additional advantage of this type of tie is that, it provides prolonged action of the applied force. The circumferential ligations should be used with caution because if the ligature wires pass through the anatomic contact points instead of the interdental spaces, interproximal pressure may be created and cause minute irregularities or crowding of the anterior teeth. Faber, 2000

#### Complex ligation

This requires a bit adaptation of the ligature on to the wire. The metal or elastic module is placed over one wing of the bracket of the rotated tooth preferably the one closer to the wire

without including the wire (Fig 7a & 7b). The module is then brought over to the wire from the gingival or occlusal, in a figure of '8' fashion including the wire and place over the other wing or the more distant or second wing, (Fig 7c) including the wire. (Rammanohar, 2014)

#### Combination ligation

Many a times the orthodontist faces a problem with crowded teeth and blocked out tooth. A simple ligation produces a large amount of force and usually leads to debonding of the bracket. A combination technique can be used in these situations. An application of the elastic ligatures without the placement of the wire (Fig 3a), and Then a steel ligature is passed under the elastic and over the wire. (Fig 3b & 3c) This ensures the force applied to bring the tooth out into the arch without excess amount of force and complexity in the design. (Kodail *et al.*, 2011)

#### Isolated Ligation

Another way to correct rotation is to use an isolated ligation. Tying only one wing of the bracket which is the farthest from the archwire (Fig 8). (Renfroe EW. Edgewise, 1975) This often requires help of a finger or an instrument to press the archwire into the bracket slot for the ligation.

#### Coil Spring Ligation

Another technique for correcting tooth rotation consists of using a coil spring ligature (Fig 9a & 9b). To start with, a stainless steel ligature is threaded through a segment of closed coil spring the length of the height of the bracket tie wings. The spring is positioned under the archwire by the bracket closest to the wire. The ligature is threaded under the tie wings and is tied to the archwire by the wings of the bracket farthest away from it. (Signorella, 1968) Prefabricated systems that operate in a similar fashion are available; the spring is replaced by an elastic wedge (Faber, 2001).

#### Extrusion or Intrusion Ties

Sometimes in a number of situations, the orthodontist requires intrusion or extrusion of the tooth or teeth. That could not be possible without the extensive bending of the wire or using auxiliary wires. The intrusion or extrusion tie could be used in adjunct for this correction. This tie is adapted in repeated performance till the desired result is achieved. There are 3 techniques for extrusion ties. In the first, the ligature thread is looped around the archwire, wrapped around the cervical portion of the bracket's wings and attached to the archwire (Fig 10a). (Dragiff, 1971) In the second, the ligature loops around the cervical wing of one bracket, wraps around the archwire, and is twisted and folded under the cervical wing of the other bracket (Fig 10b). In the last, the ligature thread is looped around the cervical bracket wings, pulled toward the archwire, which it also loops around, and then threaded back to the wing where the tie was initiated. At this point, it is twisted until the archwire becomes slightly deflected (Fig 10c). (Faber, 2000) Whichever technique is used, it is ensured that the archwire is as close to the bracket as possible and the twist is made as close as possible to the bracket so that it remains stable, flush, and nontraumatic. When the twist is located closer to the archwire, it is more susceptible to displacement and this can provoke trauma to the buccal or labial mucosa.

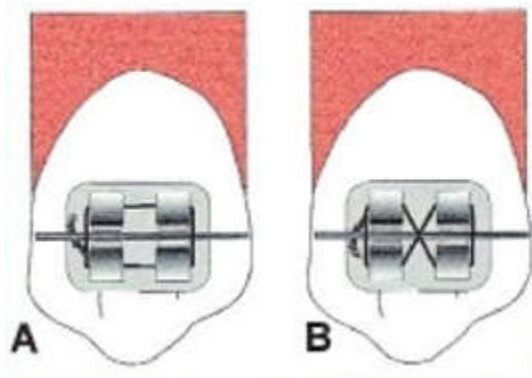


Figure 1. Basic Ties For Tooth With Metal Ligatures (A) Simple And (B) Cross Arch Tie. (Taken With Permission From Faber)

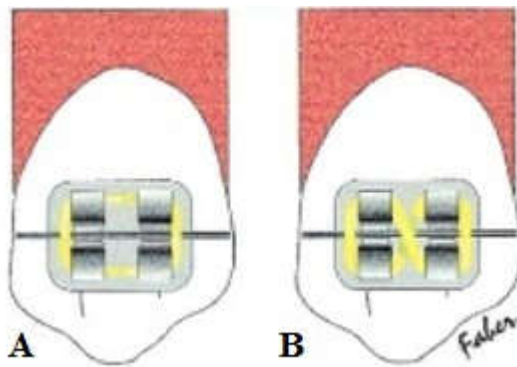


Figure 2. Basic Ties For Tooth With Elastic Ligatures (A) Simple And (B) Cross Arch Tie. (Taken With Permission From Faber)

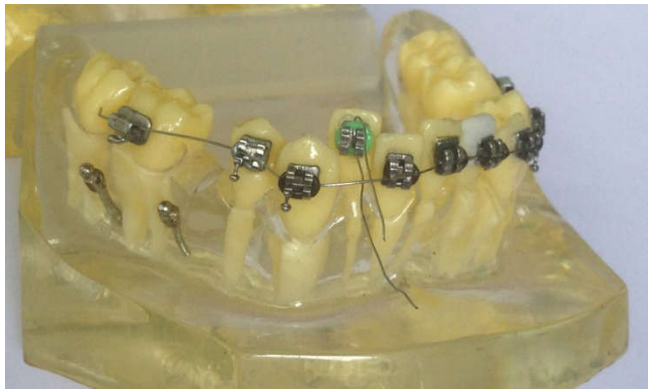


Figure 3a. Combination Tie: a metal ligature is passed under the elastic ligature

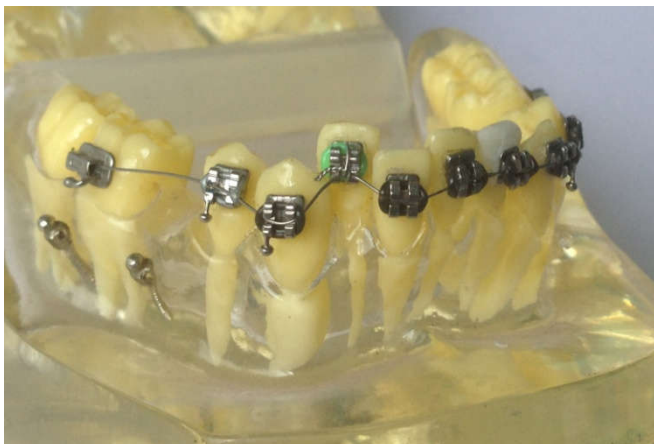

Figure 3b. Combination Tie: metal ligature is tied over the wire

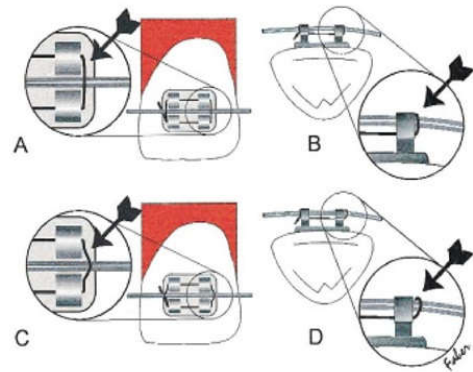


Figure 4. Ligature must be snug with bracket to prevent slackening. Diagram shows correct ligature position from labial (A) and occlusal (B) perspectives; wrong ligature position is shown from labial (C) and occlusal (D) perspectives. (Taken With Permission From Faber)

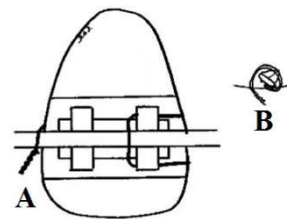


Figure 5. Ligature wire makes a loop around the rotated tooth so that when the wire is twisted, the part of the tooth farther from the alignment is pulled toward the archwire, labial (A) and occlusal (B) perspectives. (Taken With Permission From Dragiff)

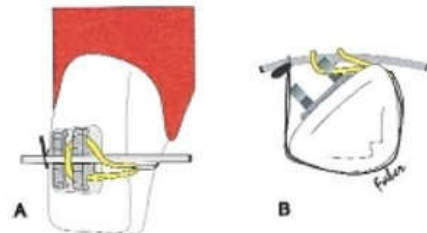


Figure 6. Circumferential ligations with elastomeric ligature fitted to one bracket's wings and linked to the metal ligature. Detail of upper lateral incisor with this combined ligature is shown in labial (A) and occlusal (B) perspectives. (Redrawn With Permission From Faber)

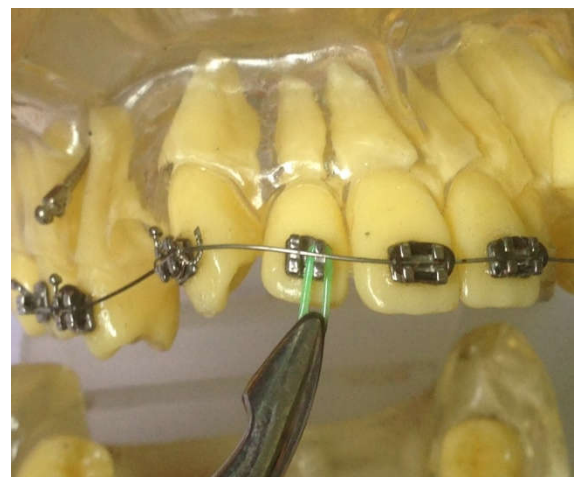


Figure 7a. Elastic ligature is placed over one wing of the bracket, nearest to the wire

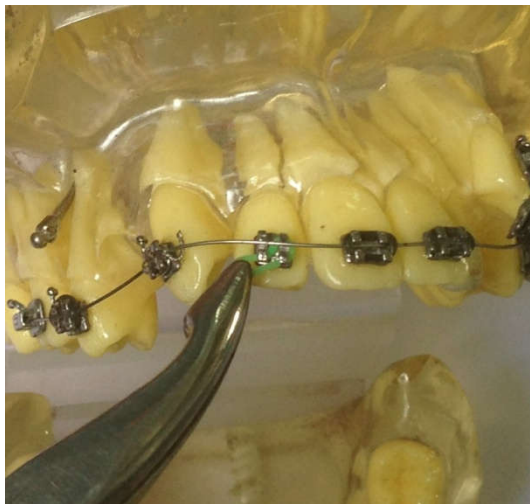


Figure 7b. The Ligature is then stretched and brought over the wire

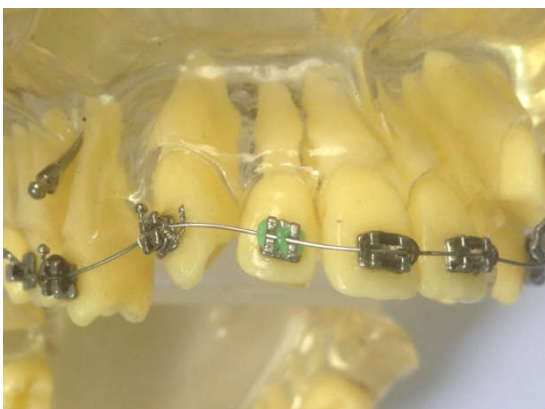


Figure 7c. It is then tied over the second wing which is distant from the bracket

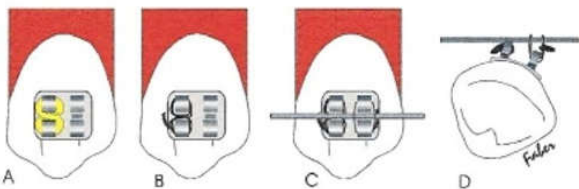


Figure 8. Isolated ligation can be used to correct rotated teeth. The slot closer to the archwire can be filled with an elastomeric ligature (A) or a metallic ligature (B) or be left empty, or be deformed to prevent the archwire from slotting in. A firm tie is made to the bracket farther from the archwire (C and D) (Taken with permission from faber)

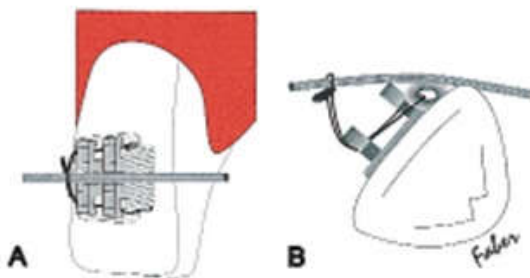


Figure 9. Closed coil spring ligation is made so that the existing spring section is pressed by the archwire, thus helping to provide the momentum required for correcting a tooth rotation. Note position of spring in relation to bracket wings, labial (A) and occlusal (B). (Taken with permission from faber)

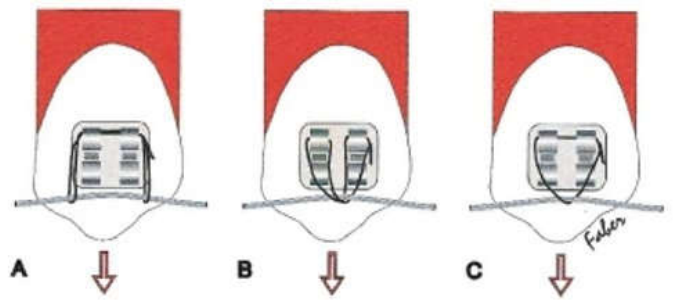


Figure 10. Three basic techniques for extrusion ties (A, B, and C). Twist should be made snug against the bracket to prevent trauma to the mucosa. (Taken with permission from faber)

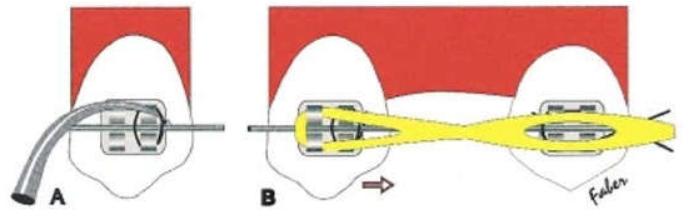


Figure 11. (A) Antirotation tying should be performed by inserting a probe between the ligature and the bracket to ensure there is enough slack to reduce friction; (B), only then should the device used for distalization of the canine be adjusted, in this case with an elastic chain. (Taken With Permission From Faber)

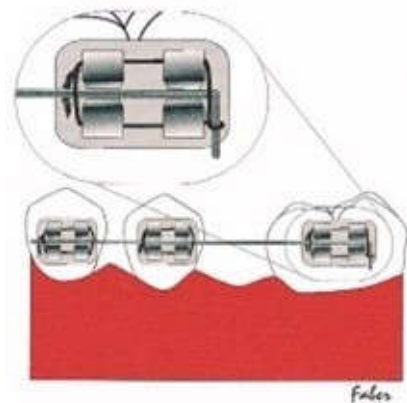


Figure 12 a. Stabilization Tie Where A Helix Is Made And Attached To The Vertical Section Of The Wire And Tied On The Other Side. (Taken with permission from faber)

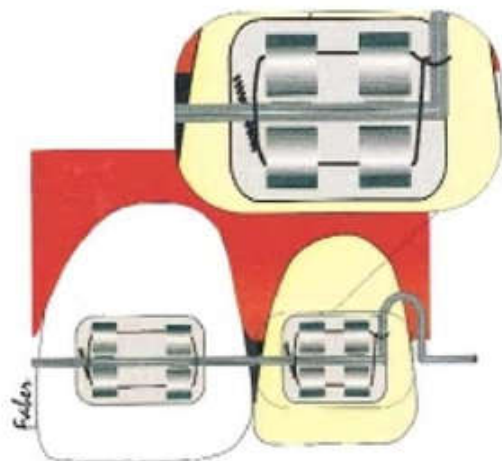


Figure 12 b. Stabilization Tie Can Also Be Used In Anteriors. (Taken with permission from faber)

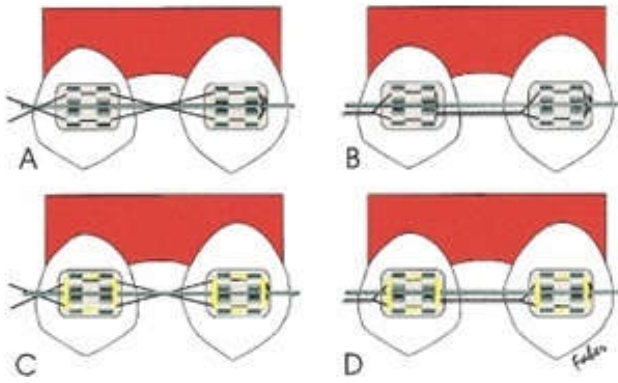


Figure 13. Tie together can be used to support the archwire (A and B) or not (C and D), being crossed in the interbracket area (A and C) or twisted (B and D). Additional ligatures must be used when the archwire is not supported by the tie together (C and D). (Taken with permission from Faber)

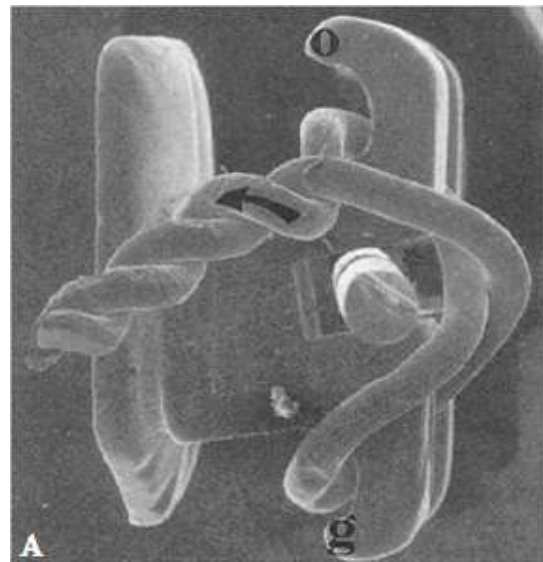


Figure 15a. Scanning electron micrographs showing mesial view of twist ligation technique (magnification 20x). A. Note space (\*) between ligature and archwire with correct direction of twist (arrow). B. With incorrect direction (arrow), ligature contacts archwire in slot (arrowhead) (Taken With Permission From Pollit)




Figure 14a. Scanning electron micrographs showing facial view of twist ligation technique (magnification 20x). Ligature has been placed under gingival wing (g), crossed over archwire slot, and tied under occlusal wing (o). A. Arrow indicates correct gingival-to-occlusal direction for twisting ligature ends. B. Large arrow indicates incorrect direction; small arrows show section of ligature wire almost parallel to bracket slot. (Taken With Permission From Pollit)

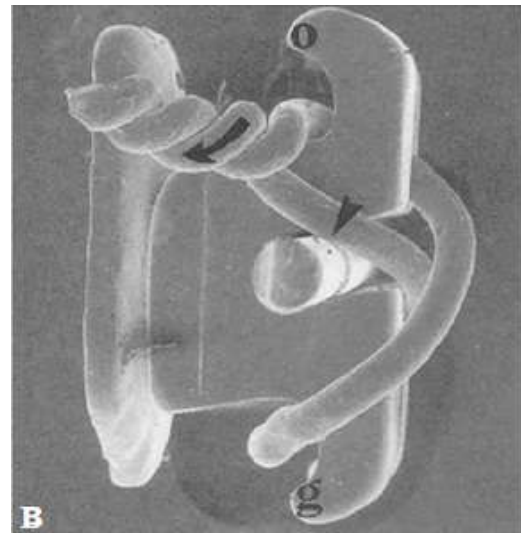


Figure 15b. Scanning electron micrographs showing mesial view of twist ligation technique (magnification 20x). A. Note space (\*) between ligature and archwire with correct direction of twist (arrow). B. With incorrect direction (arrow), ligature contacts archwire in slot (arrowhead) (Taken With Permission From Pollit)




Figure 14b. Scanning electron micrographs showing facial view of twist ligation technique (magnification 20x). Ligature has been placed under gingival wing (g), crossed over archwire slot, and tied under occlusal wing (o). A. Arrow indicates correct gingival-to-occlusal direction for twisting ligature ends. B. Large arrow indicates incorrect direction; small arrows show section of ligature wire almost parallel to bracket slot. (Taken With Permission From Pollit)

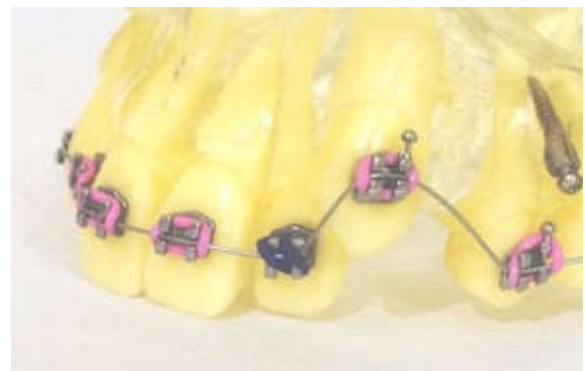

Figure 16. Cross ligation is applied from one wing of the bracket to the opposite wing diagonally




Figure 17a. Special ligature forms fourth wall of slot, allowing archwire to slide freely while transmitting full force to tooth. Oblique view (Taken With Permission From Fortini)




Figure 17b. Special ligature forms fourth wall of slot, allowing archwire to slide freely while transmitting full force to tooth. Lateral view (Taken With Permission From Fortini)

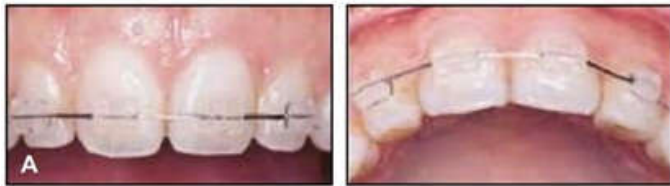

Figure 18 a. Ligation from maxillary right lateral incisor to left lateral incisor. (Taken With Permission From Tamari)

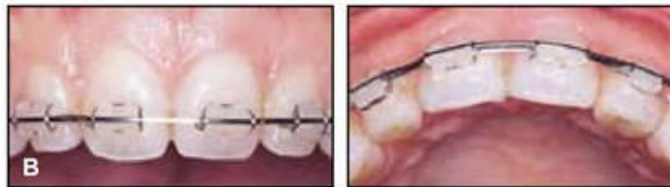

Figure 18 b. Main archwire tied in above ligature wire. (Taken With Permission From Tamari)




Figure 19. A-E Placement of ligature wire in maxillary incisor segment. F. Cross-section after placement of main archwire (bold dashed line) (Taken With Permission From Tamari)

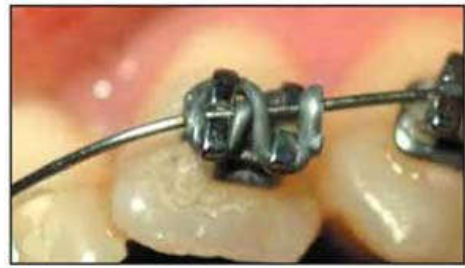

Figure 20a. A cross ligation in place where the archwire do not sit completely in the bracket slot. (Taken With Permission From Mirzakouchaki)

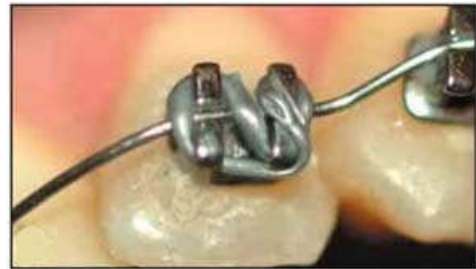

Figure 20b. Asymmetrical O-Ring ligation showing the elastic passing incisally where the wire does not seat in the bracket slot. (Taken With Permission From Mirzakouchaki)

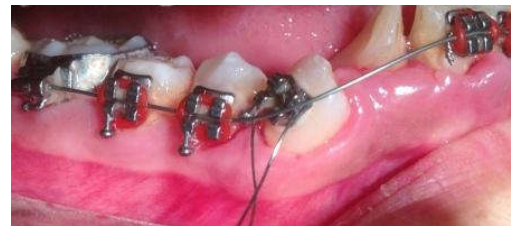

Figure 21a: The ligature wire is placed on the bracket, but under the arch wire. (Taken With Permission From Chain)

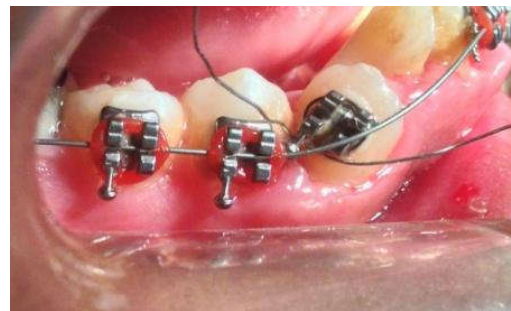


Figure 21b. The ligatures are then crossed under its wings. (Taken With Permission From Chain)

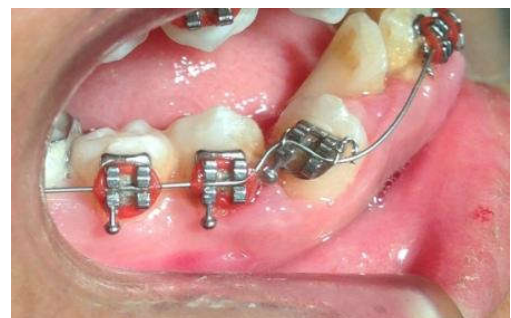

Figure 21c. The ends are brought over the archwire behind the incisal wings and tied together. (Taken With Permission From Chain)

## Antirotational Tying

In many premolar extraction procedures, retraction of the canine usually possesses with rotation. Correction of these unwanted effects requires additional time and care; which leads to a longer treatment time. An antirotation tie for the canines (Fig 11a) (or the first premolars in cases where second premolars have been extracted) can prevent the rotation of the canine during retraction. The wings of the distal bracket alone should be tied to prevent it from moving away from the archwire during retraction (Fig 11b). The tie of the ligature can be clockwise and the tuck be made away from the operator. If the tuck is made in the manner described and away from the operator, it will tend to loosen (Dragiff *et al.*, 1967) and ensures a degree of freedom this helps in reduction of friction and allows the canine to be retracted with ease. Only when this procedure has been completed should the retraction device be activated.

## Stabilization Tie

Using a small round sectional wire with a right angle bend in the initial stages of bracket engagement for uprighting, leveling, and rotating involves the risk of having the wire rotate on itself in the mouth. This may misdirect the forces, and/or injure the cheek or lips. The sectional can be made non-rolling with a modification in the ligature tie. A helix is made in the center of the ligature wire and it is slipped over the short vertical anterior end of the archwire. When the ligature is twisted at the distal of the bracket, the occlusal portion of the ligature is always snugly up the gingival portion of the ligature wire into the bracket. Small, round sectional wire with right angle bend stabilized with helix-modified ligature wire on the short, vertical anterior right angle bend. These ligatures are formed as lefts and rights, depending on which extension from the helix (mesial or distal) crosses underneath the top portion of the helix (Fig 12a). (Hitchcock, 1981) The ligature can also be adapted within the helix to stabilize the wire in the anterior segment (Fig 12b). This tie also prevents the round sectional wire from slipping forward or back in the horizontal plane. The wire is held in three planes of space. It can be used with square or rectangular sectionals; where a tieback towards the front of the mouth might be easier to accomplish, and more comfortable for the patient. (Hitchcock, 1981)

## Tie Together

Certain clinical conditions require binding groups of teeth together by means of a tie together. There are 2 basic forms of tying together: over the archwire (Fig 13a & 13b) or under the archwire (Fig 14a & 14b). In either case, the ligature can be cross-tied or twisted the latter providing greater stability and better hygiene. When the tie together is made under the archwire, additional ligatures are required to fasten the wire to the brackets. This underarch tie allows the archwire to be replaced without having to redo the tie together.

## Twist Ligation (Pollit, 1996)

The ligature was engaged in the gingival wing of each bracket; it was crossed over and engaged in the occlusal wing (Fig 15a & 15b). This method either gingival-to-occlusal direction, where the ligature wire did not appear to enter the bracket slot (Fig 15c & 15d) or with the ends of the ligature twisted in the opposite direction. The section of the ligature wire was

oriented almost parallel to the slot, in contact with the archwire. The technique has an advantage of reduced-friction appliances in that use lighter forces, but it has the additional advantage of requiring no special tools or brackets.

## Cross ligation

Certain conditions do not allow the complete engagement of the wire in the bracket due to excess of crowding or the tooth is too lingually placed. The adaptation of the ligation is across diagonally to ensure the wire is adapted in the bracket slot (Fig 16). Since the wire is not engaged fully, the force levels are low and can be replaced again when the movement of the tooth has taken place.

## Special Elastomeric Ligatures (SEB) (Fortini *et al.*, 2005; Queiroz *et al.*, 2012)

These are special made elastomeric ligatures designed to be used with conventional brackets. This retains the orthodontic archwire without pressing it against the bottom of the slot. Upon insertion, the central body rests on the buccal surface of the bracket while the extensions are positioned under the tie-wings (Fig 17a & 17b).

## Esthetic and Hygienic Ligation (Tamari and Sa'Do, 2000)

This method places a continuous ligature wire beneath the main archwire in the bracket slots, so that the ligature wire is virtually invisible (Fig. 18a & 18b). The placement of the wire is shown in Fig 19 (A-E).

## Asymmetric O-Ring Ligation (Mirzakouchaki, 2008)

The asymmetric rotation uses the traditional O-Ring applied in a cross ligation over the bracket to increase the tension (Fig 20a). Then one side of the elastic is pulled under the incisal wing where the wire is needed to be seated in the bracket slot (Fig 20b). This placement offers an asymmetrical force load to help fully seat the archwire into the bracket slot.

## Double Ligation Technique (Chain *et al.*, 2016)

The double ligation technique is used where the correction of the rotated tooth is eminent and the full engagement of the wire is difficult to approach. Here the ligature wire is placed on the bracket under the arch wire (Fig 21a). The ends are then pulled gingivally and crossed to each other under the wings of the bracket (Fig 21b). The ends are then brought over the arch wire behind the incisal wings and tied together (Fig 21c). This tie ensures the archwire to seat in the bracket slot without major discomfort to the operator or the patient.

## DISCUSSION

Ligation is the process of adopting the archwire to the bracket. It makes the appliance active for the necessary correction to happen. A fine understanding of the ligation technique can help the orthodontist ease out on difficult situation. The ligation helps in the prevention of the adverse effect of the force (during retraction). And also helps in the transfer of active force. The tuck of the twisted end of the wire should keep going in the direction in which the tie is twisted. If the twist is clockwise, the tuck should continue in a clockwise direction. If the twist is counterclockwise, the tuck should continue in a

counterclockwise direction. When tucks are made in this manner, ties remain effective. If the tuck is made in a direction opposite to that of the twist, the tie is loosened. This can have an effect on treatment by diminishing the tightness of the tie, by having the twisted end loosen and turn out, by creating discomfort and emergencies (Dragiff *et al.*, 1967). However, ligation with a gingival twisted end is more frequent. (Faber, 2000) The elastic ligature is easy to adapt and is quick to perform but it undergoes permanent deformation in shape and thus force decay over time and potentially impede good oral health. Whereas, the metal ligatures take up time in tying but provides better hygiene and stability to the arch wire.

### Conclusion

The ligation technique depends upon few categories. They are:

1. The design of brackets and the wings available.
2. Knowing how to use all the ligation technique with the relevant stage for better and/or faster treatment results.
3. The knowledge and sole discursion and the creativity of the orthodontist in tying the brackets as tools is required for obtaining excellence in orthodontics.

### REFERENCES

- Chain S, Tan K, Loomba A, Seth P, Sarkar S. 2016. Double Ligation Technique for Rotated Teeth. *J Clint Orthod.*, 50(4):258.
- Chawala H, Suri S, Utreja A. 2006. Engagement of elastomeric modules for efficient force delivery. *J Clin Orthod.*, 40(11):652-654.
- Dragiff DA, Blafer JL, Gottlieb EL. Twist and Turns. 1967. *J Clin Orthod.*, 11:111-115.
- Dragiff DA. 1971. Tying Siamese brackets. *J Clin Orthod.*, 5: 397-400.
- Faber J. 2000. Tying Twin Brackets. *Am J Orthod Dentodacial Orthop.*, 118(1):101-06.
- Fortini A, Lupoli M, Cacciafesta V. 2005. A new low friction ligation system. *J Clin Orthod.*, 8:464-470.
- Hitchcock HP. 1981. Non Rolling Round Sectional Wire Tie. *J Clin Orthod.*, 6:433
- Kodail K Kiran, Goel S, Tanveer S, Srihari V. 2011. Ligation of Blocked-Out Incisor SIMPLIFIED WJD, 2(1); 75-75.
- Mirzakouchaki B. 2008. Asymmetric O-Ring Ligation. *J Clin Orthod.*, 2:100.
- Pollit D.J.J. 1996. Twist Ligation: A Technique to Reduce Archwire Binding. *J Clin Orthod.*, 4:150-153.
- Proffit W, White R. 1991. Surgical-orthodontic treatment. St. Louis: Mosby.
- Queiroz GV, Rino Neto J, De Paiva JB, Rossi JL, Ballester RY. 2012. Comparative study of classic friction among different archwire ligation systems. *Dental Press J Orthod.*, 17(3):64-70.
- Rammanohar M. 2014. Bracket Ligation with a Difference. *J Ind Orthod Soc.*, 48 (4) 286-287.
- Renfroe EW. 1975. Edgewise. Philadelphia: Lea & Febiger.
- Signorella A. 1968. Coil springs. *J Clin Orthod.*, 2:132-5.
- Tamari K and Sa'Do B. 2000. Esthetic and Hygienic Ligation. *J Clin Orthod.*, 2:97-98.

\*\*\*\*\*