



RESEARCH ARTICLE

USE OF MTA AS APICAL PLUG IN TEETH WITH OPEN APEX - A REPORT OF 2 CASES

¹Amitoj Kaur Walia, ^{2*}Harshita, ³Monika Vashisht, ⁴Fatinderjeet Singh, ⁵Pratima Sharma, ⁶Harsimranjit Kaur and ⁷Gajinder Krishan

¹Tutor, Department of Conservative Dentistry and Endodontics, Genesis Institute of Dental Sciences and Research, Ferozepur, Punjab, India

²Post Graduate Student, Department of Conservative Dentistry and Endodontics, Genesis Institute of Dental Sciences and Research, Ferozepur, Punjab, India

³Post Graduate Student, Department of Conservative Dentistry and Endodontics, Genesis Institute of Dental Sciences and Research, Ferozepur, Punjab, India

⁴Senior Lecturer, Department of Conservative Dentistry and Endodontics, Genesis Institute of Dental Sciences and Research, Ferozepur, Punjab, India

⁵Post Graduate Student, Department of Conservative Dentistry and Endodontics, Genesis Institute of Dental Sciences and Research, Ferozepur, Punjab, India

⁶Post Graduate Student, Department of Conservative Dentistry and Endodontics, Genesis Institute of Dental Sciences and Research, Ferozepur, Punjab, India

⁷Post Graduate Student, Master of Business Administration, Thapar Institute of Engineering and Technology, Patiala, Punjab, India

ARTICLE INFO

Article History:

Received 23rd July, 2017

Received in revised form

27th August, 2017

Accepted 18th September, 2017

Published online 31st October, 2017

ABSTRACT

Aim: As management of non-vital teeth with open apices is a challenge to dental practitioners. So, the aim of this case series is to use MTA plug in teeth with open apex.

Summary: Mineral trioxide aggregate (MTA) apical plug method is an alternative treatment option for open apices, as it requires reasonably less time with predictable results and appears to be a valid material to obtain periradicular healing in teeth with open apices and necrotic pulps.

Key words:

MTA, Necrotic pulp,
Open apex,
Apical plug.

Copyright©2017, Amitoj Kaur Walia et al. This is an open access article distributed under the Creative Commons Attribution License, which permits unrestricted use, distribution, and reproduction in any medium, provided the original work is properly cited.

Citation: Amitoj Kaur Walia, Harshita, Monika Vashisht, Fatinderjeet Singh, Pratima Sharma, Harsimranjit Kaur and Gajinder Krishan. 2017. "Use of MTA as apical plug in teeth with open apex - a report of 2 cases", *International Journal of Current Research*, 9, (10), 59938-59942.

INTRODUCTION

The primary objective of endodontic therapy is the complete obturation of the root canal space to prevent re-infection. In teeth with incomplete root development caused by trauma, caries or other pulpal pathosis, the absence of the natural constriction at the end of the root canal presents a challenge and by making control of obturating materials difficult. For success in these particular cases, the aim of the dentist is to adequately seal a sizeable communication between the root

canal system and the periradicular tissue and provide a barrier against which obturation material can be compacted (Aggarwal, 2012). Recently, synthetic apical barriers with a variety of materials have been proposed as alternatives to the traditional apexification treatment method using calcium hydroxide. Mineral trioxide aggregate (MTA) is the most popular material for this purpose. It has been advocated for use as an apical barrier because of its sealing capabilities, ability to get hardened in the presence of blood, and biocompatibility. So it can be used to create an apical plug at the root-end that helps to prevent the extrusion of the obturating materials. These two case series presents the clinical applications of MTA as apical plug in teeth with open apex.

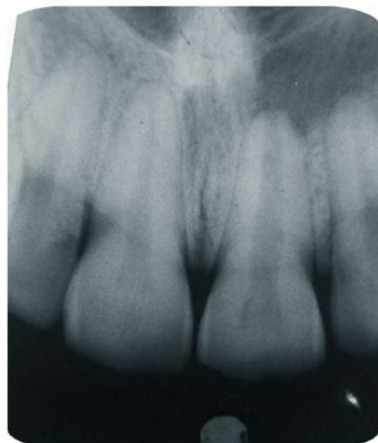*Corresponding author: Harshita,

Post Graduate Student, Department of Conservative Dentistry and Endodontics, Genesis Institute of Dental Sciences and Research, Ferozepur, Punjab, India

MATERIALS AND METHODS

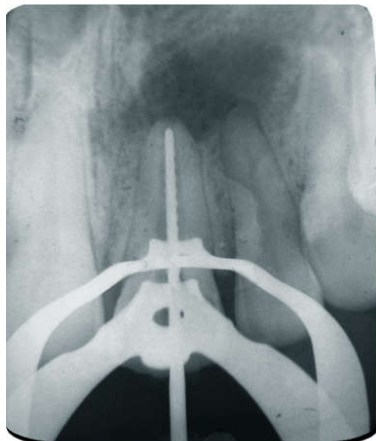
Case Report 1

A 23 year old male patient reported Department of Conservative Dentistry and Endodontics, Genesis Institute of Dental Sciences and Research, Ferozepur with chief complaint of fractured and discolored upper right front tooth. Patient gave history of trauma at the age of 7 or 8 years and gave no history of pain or swelling. Clinical examination revealed Ellis class I fracture and discolored tooth in relation to 11. Tooth showed tenderness on percussion but no response to vitality tests. Medical history was non contributory. Radiographic examination revealed fractured tooth with open apex and radiolucent lesion in proximity to apex of tooth 11 (Figure 1).



PREOPERATIVE

Figure 1. Ellis class I fracture with open apex and periapical radiolucency in relation to 11relation to 11

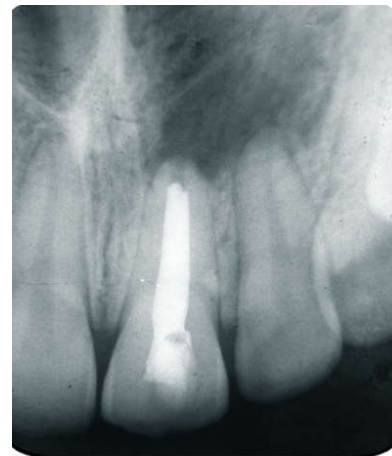

WORKING LENGTH

Figure 2. Working length determined in relation to 11

So, according to 'AAE Consensus Conference Recommended Diagnostic Terminology' the final diagnosis of Pulpal necrosis with asymptomatic apical periodontitis with open apex with respect to 11 was made. After the application of the rubber dam, access cavity preparation was done, the working length was determined (Figure 2). The canal was then cleaned biomechanically by using intracanal instruments. Irrigation was done using saline and 5 ml of 3% NaOCl (Shiva Products, Waliv, Palghar, Maharashtra, India) as an irrigant after each instrumentation for final flush.

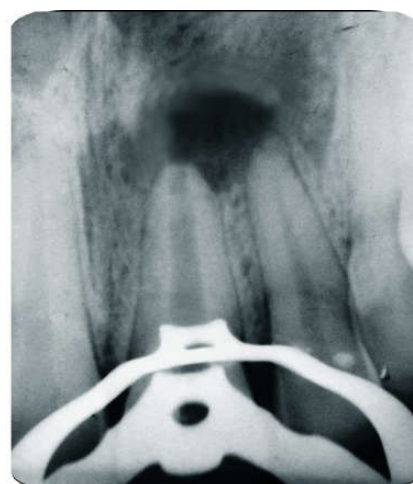
Then, the canal was dried with sterile paper points and Metapex (Meta Dental Corp. Ltd., Elmburst, NY), a commercially available product of composed Ca(OH)_2 , silicone oil, and iodoform was then placed in the canal and temporary restoration was done using Cavit (3M ESPE, St. Paul, MN, USA) (Figure3). Patient was recalled after 2 weeks.



METAPEX PLACED

Figure 3. Metapex placed in relation to 11

At follow up visit tooth was isolated using rubber dam and metapex was removed using H files and repeated rinsing with 3% NaOCl followed by rinsing with distilled water (Figure4). The canal was dried with sterile paper points and the MTA (Dental Tulsa Dentsply, Johnson City, TN, USA) was mixed according to manufacturer's instructions and placed in canal with help of Dovgan carrier in the apical portion of the canal (Figure 5). and compacted into the coronal section of the canal using Schilder plugger [Dentsply Caulk, Milford, USA] to form a tight apical plug of 4mm. To check the correct position of the MTA placement, an IOPA radiograph was taken. A wet cotton pellet with distilled was then placed in the pulp chamber and the access cavity was closed with temporary filling material Cavit (3M ESPE, St. Paul, MN, USA).

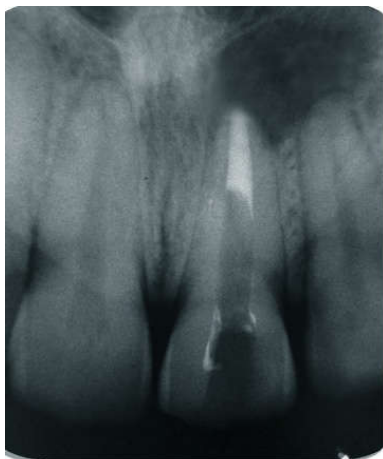

METAPEX REMOVED

Figure 4. Metapex removed in relation to 11

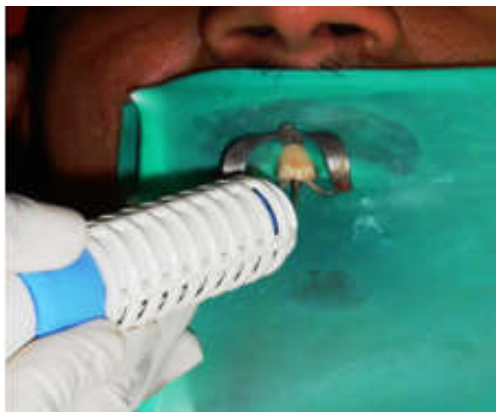After one day, the Cavit and the cotton pellet were removed. The rest of the canal was obturated with thermoplastic gutta-percha using calamus system (Dentsply/Tulsa; Tulsa, Okla), (Figure 6) in association with a zinc oxide eugenol sealer (Pulp

Canal Sealer EWT Kerr, West Collins, CA) (Figure 7) followed by placement of composite resin (Kulzer Charisma, Mumbai) as permanent restoration.



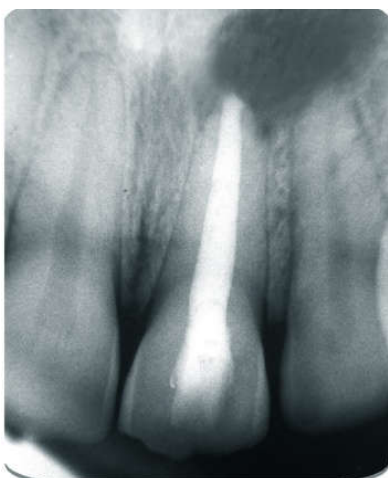MTA PLUG

Figure 5. MTA placement in relation to 11



USE OF CALAMUS FOR OBTURATION

Figure 6



OBTURATION DONE

Figure 7.

Case Report 2

A 25 year old male presented in the Department of Conservative Dentistry and Endodontics, Genesis Dental

College, Ferozepur with the chief complaint of discoloration in his right upper front tooth region. He gave history of trauma to this tooth at age of 9 and swelling and pus discharge from the right upper front since 1 month. The clinical examination revealed slight discoloration in relation to 12 and tooth did not showed any response to vitality tests. Radiographic examination (Figure 8) of the tooth revealed a wide open apex and presence of periapical lesion.

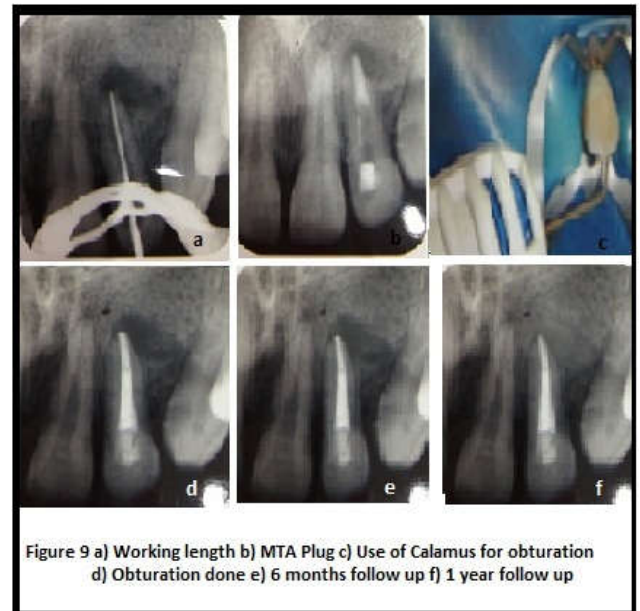
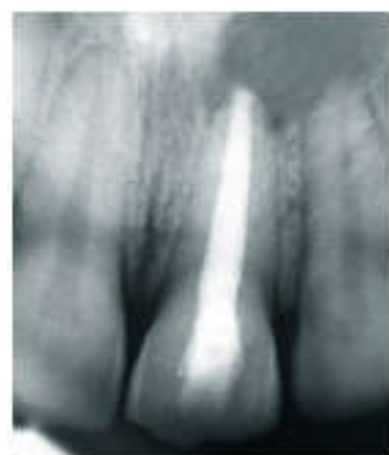


Figure 9 a) Working length b) MTA Plug c) Use of Calamus for obturation d) Obturation done e) 6 months follow up f) 1 year follow up

So, according to ‘AAE Consensus Conference Recommended Diagnostic Terminology’ the final diagnosis of Pulpal necrosis with asymptomatic apical periodontitis with open apex in relation to 12 was made. The protocol for the creation of an apical plug with MTA mixture was implemented as in case 1 (Figure 9a, b, c and d).

RESULTS

In Case Report 1, patient was recalled after 6 months and 12 months for follow up. The radiographic follow up at 6 months revealed a decrease of the periapical rarefaction, regeneration of the periradicular tissue and hard tissue deposition indicating healing of lesion (Figure 8) and at 1 year significant healing was observed clearly (Figure 9).



6 MONTHS FOLLOW UP

Figure 8

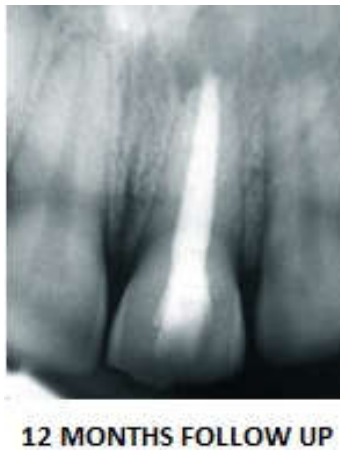

Figure 9

Case Report 2

In Case Report 2, patient was recalled after 6 months (9e) and 1 year (9f) for follow up. Complete resolution of lesion was seen on 1 year follow up.

DISCUSSION

During tooth development, the inner and outer dental epithelia fuse and form the cervical loop, which results in Hertwig's epithelial root sheath, a structure responsible for root formation (Hargreaves, 2002). The presence of healthy pulp is essential for root development and apical closure. When the pulp is vital and the apex is not fully formed, it is imperative to maintain the pulp vitality for dentine formation. Dental caries and trauma are the most common challenges to the integrity of a tooth as it matures. Both insults can render the pulp non-vital. If this occurs prior to complete root formation and apical closure, normal root development is halted (Farhad, 2005). Clinically, there are several difficulties associated with treating non-vital teeth that have a widened or open apical foramen. Firstly, the apical diameter of the canal is often larger than the coronal diameter, so debridement is difficult. In addition, the lack of an apical stop makes the control of obturation materials very difficult. Finally, the thin walls of the root canal are prone to fracture, so that surgical treatment is generally not a viable option (Cohen, 2006). To avoid these complications, apexification prior to root canal filling should be attempted.

The use of calcium hydroxide for apical closure was first introduced in 1964 by Kaiser, when he proposed that using it after mixing with camphorated parachlorophenol (CMCP) would induce the formation of a calcified barrier across the apex (Dogra, 2005). The larger the apical opening, the longer is the time necessary to induce apical closure. Induction of apical healing takes at least 3–4 months and requires multiple appointments. Patient compliance with this regimen may be poor and many fail to return for scheduled visits. The temporary seal may fail resulting in reinfection and prolongation or failure of treatment. For these reasons one-visit apexification has been suggested. A number of materials have been proposed for this purpose including tricalcium phosphate, calcium hydroxide, freeze dried bone, and freeze dried dentine. Placement of MTA has been considered in these cases as it is effective as an apical barrier and its application results in predictable apical closing, reduced treatment time and a reduced number of exposures to radiographs (Giuliani *et al.*, 2002).

It is a biomaterial that has been investigated for endodontic applications since the early 1990s. It was first described in the dental scientific literature in 1993 and was given approval for endodontic use by the U.S. Food and Drug Administration in 1998 (Howard *et al.*, 2008). It is a powder that consists of fine hydrophilic particles that set in the presence of moisture. The setting time in moisture is 2 hours 45 minutes (Hargreaves, 2002). Two commercial forms of MTA are available: ProRoot MTA as the grey and white MTA (Tulsa Dental Products, Tulsa, OK, USA) and MTA-Angelus (Angelus, Londrina, PR, Brazil) is without tetracalcium alumioferrite. MTA is a mixture of a refined Portland cement and bismuth oxide, and contains trace amounts of SiO_2 , CaO , MgO . Investigations have found that lower amounts of iron, aluminum, and magnesium are present in white MTA than in grey MTA. Hydrated MTA products have an initial pH of 10.2, which rises to 12.5 three hours after mixing. The setting process is described as a hydration reaction of tricalcium silicate ($3\text{CaO}\cdot\text{SiO}_2$) and dicalcium silicate ($2\text{CaO}\cdot\text{SiO}_2$), which the latter is said to be responsible for the development of material strength (Kumari, 2011). It not only fulfills the ideal requirement of being bacteriostatic, but it might have potential bactericidal properties. The release of hydroxyl ions, a sustained high pH for extended periods, and the formation of a mineralized interstitial layer might provide a challenging environment for bacterial survival. These antibacterial properties can be a potent inhibitor of bacterial growth against species such as *Enterococcus faecalis*, a microorganism prevalent in root canal failures. Moreover, *Candida albicans*, commonly present in refractory endodontic disease, is susceptible to the antifungal activity of freshly mixed MTA. These factors are important when considering nonsurgical treatments for patients with large periapical lesions associated with initial root canal treatment (Bogen, 2009). MTA has also presented promising outcomes when used for the repair of lateral and furcation perforations. Formation of cementum surrounding MTA was observed, even after extrusion of MTA into a furcation (Pitt *et al.*, 1995).

On the basis of these findings, MTA may be an appropriate material for apical sealing of mature root canals with open apices, which may impose technical challenges in obtaining adequate obturation because of apical perforation, over-instrumentation, resorption, or former surgical treatment. Successful prognosis from conservative treatment with MTA for such difficult cases without surgical treatment is a great benefit for patients (Hayashi *et al.*, 2004). Furthermore, MTA provides scaffolding for the formation of hard tissue and the potential of a better biological seal (Steinig *et al.*, 2003). It also facilitates formation of normal periradicular architecture by inducing hard tissue barriers. The rationale is to establish an apical stop that would enable the root canal to be filled immediately. There is no attempt at root end closure. Rather an artificial apical stop is created (Mohammadi, 2011). The application of MTA mixture was preceded by a temporary calcium hydroxide dressing in order to limit bacterial infection in the tooth (Arzu, 2008). Obturation in this case was completed with thermoplasticized gutta-percha, since it can be placed without applying any compaction forces on thin dentinal walls in contrast to lateral condensation method.

Conclusion

The presented cases showed placement of an apical barrier using MTA is an alternative to conventional long-term calcium hydroxide therapy.

In conclusion, MTA appeared to be a valid option for apexification with the added advantage of speed of completion of therapy.

Acknowledgement

Authors would like to thank Genesis Institute of Dental Sciences and Research, Ferozepur, Punjab, India for its support.

REFERENCES

- Aggarwal, A 2012. Single visit apexification with MTA: A report of two cases. *Clinical Dentistry Mumbai*, 30(9), 20-5.
- Arzu P, Erdem E 2008 Mineral trioxide aggregate for obturation of maxillary central incisors with necrotic pulp and open apices. *Dental Traumatology*, 24 (8), 38-41.
- Bogen G, Kutter S 2009. Mineral Trioxide Aggregate Obturation: A Review and Case Series. *Journal of Endodontics* 35(6), 777- 90.
- Cohen S, Hargreaves KM 2006. Pathways of the Pulp. *St Louis Mosby Inc* 30(2), 610-49.
- Dogra S, KS Mukunda, Arun A 2005. Apexification. *Journal of Dental sciences and Research* 3(1), 41-4.
- Farhad A, Mohammadi Z 2005. Calcium hydroxide: a review. *Int Dent J*. 55(2), 293-301.
- Giuliani V, Baccetti T, Pace R, Pagavino G 2002. The use of MTA in teeth with necrotic pulps and open apices. *Dent Traumatol* 18(5), 217-21.
- Güneş B, Aydinbelge H 2012. Mineral trioxide aggregate apical plug method for the treatment of nonvital immature permanent maxillary incisors: Three case reports. *Journal of Conservative Dentistry* 15(1), 73-6.
- Hargreaves KM, Goodis HE 2002. Seltzer and Bender's Dental Pulp. *Quintessence Publishing Co. Inc* 38(5), 13-40.
- Hayashi M, Shimizu A, Ebisu A 2004. MTA for Obturation of Mandibular Central Incisors with Open Apices: Case Report. *Journal of Endodontics* 30(2), 120-2.
- Howard WR, Jeffrey M, David W, David G (2008) Mineral trioxide aggregate material use in endodontic treatment: A review of the literature. *Charlton dental materials* 23(5), 149-64.
- Kumari M, Takkar H, Nigam N 2011. Mineral Tri Oxide Aggregate Used As Apical Plug In Open Apex Cases - A Review And Case Report. *Indian Journal of Dental Sciences* 3(4): 15-7.
- Matt, GD, Thorpe JR, Scott B 2004. Comparative Study of White and Gray Mineral Trioxide Aggregate (MTA) Simulating a One- or Two-Step Apical Barrier Technique. *Journal of Endodontics* 30(12), 876-80.
- Mohammadi Z 2011. Strategies to manage permanent non-vital teeth with open apices: a clinical update. *International Dental Journal* 61(5), 25-30.
- Morse DR, O'Larnic J, Yesilsoy C 1990. Apexification: review of the literature. *Quintessence Int* 21(7), 589-98.
- Pitt Ford TR, Torabinejad M, McKendry JD, Hong CU, Kariyawasam SP 1995. Use of mineral trioxide aggregate for repair of furcal perforations. *Oral Surg Oral Med Oral Pathol Oral Radiol Endod* 7(9), 756-62.
- Steinig TH, Regan JD, Gutmann JL 2003. The use and predictable placement of Mineral Trioxide Aggregate in one-visit apexification cases. *Aust Endod J* 29(3), 34-42.
