



RESEARCH ARTICLE

CONSERVATIVE AND RADICAL MANAGEMENT OF OSTEOCHONDROMA OF MANDIBULAR  
CONDYLE- A SYSTEMATIC REVIEW

\*Dr. Pratik N. Suthar, Dr. Sonal B. Shah, Dr. Pushkar P. Waknis, Dr. Gandhali Limaye,  
Dr. Pranav Sathe and Dr. Aditi Saha

Department of Oral and Maxillofacial Surgery, Dr. D.Y Patil Vidyapeeth's Dr. D.Y Patil Dental College  
and Hospital, Pimpri, Pune

ARTICLE INFO

Article History:

Received 11<sup>th</sup> August, 2017  
Received in revised form  
16<sup>th</sup> September, 2017  
Accepted 20<sup>th</sup> October, 2017  
Published online 30<sup>th</sup> November, 2017

Key words:

Osteochondroma,  
Mandibular condyle,  
Condylectomy.

ABSTRACT

**Purpose:** The purpose of this study was to evaluate the functional outcomes of conservative and radical management of osteochondroma of mandibular condyle.

**Methods:** All relevant full text articles available on PubMed and GoogleScholar between 2001 and 2015 were retrieved and examined. The data was tabulated and analyzed.

**Results:** Of the 24 cases 14 were treated by condyloplasty, whereas 10 required total condylectomy. Twelve patients required orthognathic surgery of which 3 patients had transient mandibular weakness and 1 patient had transient inferior alveolar nerve anaesthesia complications. Follow-up period for all cases ranged between 3 months to 7 years. There was only one case of recurrence but the patient was not re-operated as she was symptom free.

**Conclusion:** Mandibular condylar osteochondroma is thought to be a relatively rare lesion occurring in the facial skeleton. Gradual facial asymmetry over the years is the most striking feature. The treatment modality for osteochondroma of mandibular condyle could be conservative condylectomy or total condylectomy. Both the procedures are curative. Additional procedures like orthognathic surgery may be required in extensive tumours. The decision, however, depends on the tumour size and how much swing of mandible is required post-surgery for correction of asymmetry and occlusion.

Copyright © 2017, Dr. Pratik N. Suthar et al. This is an open access article distributed under the Creative Commons Attribution License, which permits unrestricted use, distribution, and reproduction in any medium, provided the original work is properly cited.

Citation: Dr. Pratik N. Suthar, Dr. Sonal B. Shah, Dr. Pushkar P. Waknis et al. 2017. "Conservative and radical management of Osteochondroma of Mandibular condyle- A systematic review", *International Journal of Current Research*, 9, (11), 60664-60668.

INTRODUCTION

Temporomandibular Disorders (TMD) involve different combinations of musculoskeletal problems like those involving masticatory musculature, the temporomandibular joint and associated structures. The chief symptoms involve pain and/or restricted range of mandibular motion. Pain and dysfunction in the orofacial region represents a diagnostic challenge. Osteochondroma in this region can have symptoms mimicking temporomandibular disorders. Osteochondroma or osteocartilaginous exostosis of temporomandibular joint is a rare slow growing cartilage capped exophytic benign tumour. This lesion predominantly involves the axial skeleton especially long bones like femur and tibia. The oral and maxillofacial regions are not common sites of osteochondromas, but the embryonic development of the temporomandibular joint, by the endochondrial ossification makes this area the most frequent facial site of this type of tumour. (Utumi et al., 2010; Ortakoglo et al., 2007; Wu et al., 2007) They are found on the medial aspect of the mandibular

condyle (57%), followed by an anterior (20%), and rarely in lateral or superior positions (<1%). (Peroz et al., 2002) Osteochondromas occur singly or as a part of an autosomal dominant syndrome known as osteochondromatosis. (Veazeau et al., 1995) Radiologically and histologically, multiple osteochondromatosis and solitary osteochondromas cannot be distinguished from each other (Porter and Simpson, 1999). This distinction is clinically relevant because multiple osteochondromatosis has a higher risk of sarcomatous transformation (11%) than that of the solitary osteochondroma (1%). (Jaffee, 1961) Various etiological factors have been described in the literature, (Obwegeser and Makek, 2002; Slootweg and Muller, 1986) but it is still unclear as to how the condition develops and runs. It could occur in any age group and females are slightly more prone to develop this condition. Osteochondroma can present different clinical characters like facial asymmetry, malocclusion, prognathic deviation of chin, contralateral crossbite and interference with mouth opening, etc. the other conditions mimicking these features include unilateral condylar hyperplasia, osteoma, chondroma, giant cell tumour, myxoma, fibro-osteoma, fibrous dysplasia, fibrosarcoma and chondrosarcoma. The definitive diagnosis should always be based on clinical, radiological and

\*Corresponding author: Dr. Pratik N. Suthar,  
Department of Oral and Maxillofacial Surgery, Dr. D.Y Patil Vidyapeeth's Dr.  
D.Y Patil Dental College and Hospital, Pimpri, Pune.

histopathological criteria. Complementary examinations like panoramic radiography, computed tomography and scintigraphy may also be used as an adjunctive tool. Literature studies reveal osteochondroma being treated by either conservative method or radical method. This study was conducted to evaluate the functional outcomes of conservative and radical management of osteochondroma of mandibular condyle.

### Focused question

What are the functional outcomes of managing osteochondroma of mandibular condyle by conservative approach vs radical approach?

### Objective

To study the functional outcomes of conservative and radical management of osteochondroma of mandibular condyle.

### Methods

#### Eligibility criteria

#### Inclusion criteria

1. Studies published between 1<sup>st</sup> January 2001 to 31<sup>st</sup> December 2015.
2. Studies will involve case reports and case series.

#### Exclusion criteria

1. Articles other than ENGLISH.
2. Osteochondroma of mandibular condyle associated with other pathology.

### PICO

P- Participant- age group 18- 70 years.  
I- Intervention- radical.  
C- Comparison- conservative.  
O- Outcome- possibility of recurrence.  
restoration of function.

Tumour size, treatment done and the postoperative outcome of each study was thoroughly evaluated.

### Search

#### Keywords

Osteochondroma	Osteocartilagenous exostosis, benign bone tumour
Panaromic radiograph	OPG
Facial asymmetry	Differential growth pattern, deviation in opening pattern, jaw deformity
Condylectomy	Disarticulation, TMJ

#### Data collection process

A standard pilot form in excel sheet was initially used and then all those headings not applicable for review were removed. Data extraction was done for one article and this form was reviewed by an expert and finalized. This was followed by data extraction for all the articles.

#### Study selection

Records screened through database and additional records identified through other sources were 632 and 850 respectively. Of these 1482, 322 were duplicates. Only 320 articles were relevant to our study. Due to limitations of access only 9 full text articles were available.

#### Data items

The data items included were:

Author- the name of the author  
Location- the country in which the study took place  
Year of publication- the year in which the study was established  
Chief complaint- complaint of the patient  
Study design- if the study was a control or a clinical trial, blinding  
Sample size- no. of participants included in the study  
Setting- place where the study was conducted  
Pathology

S.No.	Search strategy	Number of articles	Number of selected articles	After duplicate removal
1.	osteochondroma OR panaromic radiograph OR facial asymmetry OR condylectomy	620	5	600
2.	osteochondroma AND panaromic radiograph AND facial asymmetry OR condylectomy	5	0	2
3.	osteochondroma AND panaromic radiograph OR facial asymmetry And condylectomy	2	0	
4.	osteochondroma OR panaromic radiograph AND facial asymmetry AND condylectomy	1	1	0
5.	osteochondroma AND condylectomy	2	0	
6.	Osteocartilagenous exostosis AND Condylectomy	2	0	2
7.	osteochondroma of mandibular condyle	850	3	556
	TOTAL	1482	9	1160

### Information sources

A thorough computer literature search was done using PubMed and Google Scholar. Additional manual search was done by going through published home-based and foreign articles available at DPU library resources. Case reports/series, and original articles in English that documented management of osteochondroma of mandibular condyle published between January 2001 to December 2015 were included in the study.

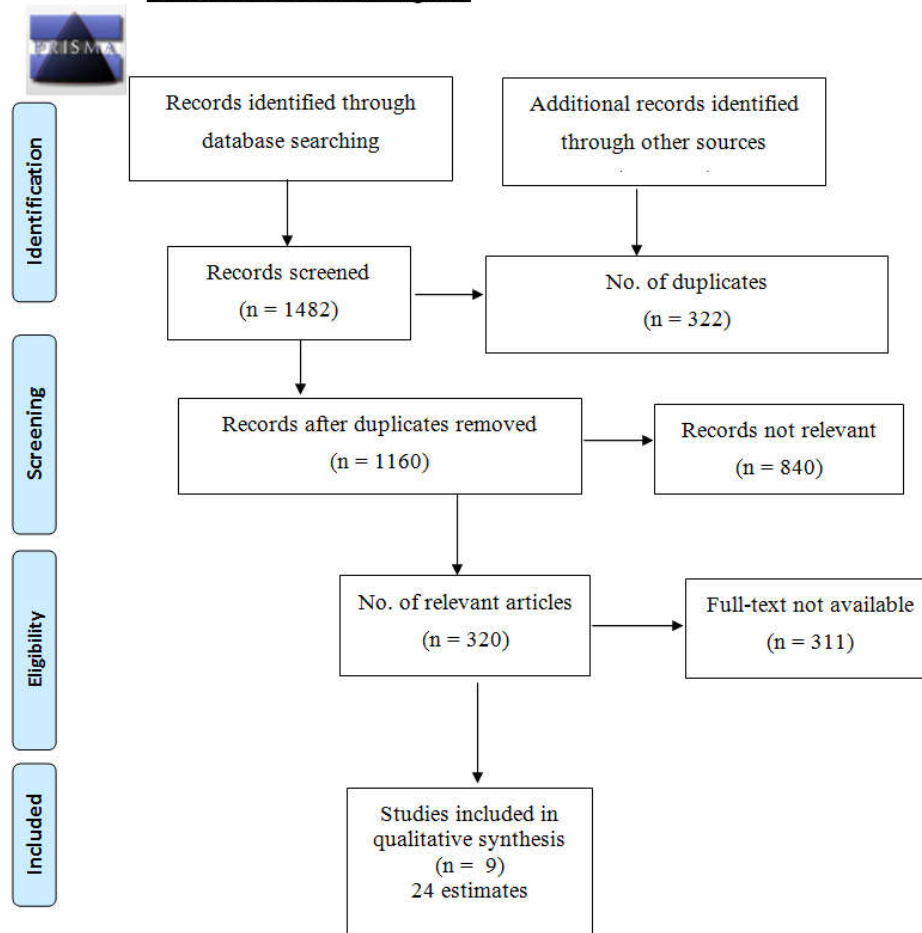
Tumour size  
Investigation type  
Dentition- type of occlusion  
Surgical procedure- conservative and radical management  
Adjuvant treatment  
Evaluation period- time of evaluation  
Results- outcome of the study  
Remark- comments of the author.

## RESULTS

Of the 24 cases 14 were treated by condyloplasty, whereas 10 required total condylectomy. Twelve patients required orthognathic surgery of which 3 patients had transient mandibular weakness and 1 patient had transient inferior alveolar nerve anaesthesiacomplications. Follow-up period for all cases ranged between 3 months to 7 years. There was only one case of recurrence but the patient was not re-operated as she was symptom free.

are case reports and case series done in European countries, Japan, USA, Brazil and Korea. All the studies included were between 2001 and 2015. All our studies were hospital based and most of the patients reported with chief complaint of facial asymmetry and disturbed occlusion. Some patients had pain at the TMJ region and restricted movement of the jaw. One of the patient had chief complaint of impaired hearing. (Cimino *et al.*, 2003) 3 patients had chief complaint of headache and joint noises. (Holmlund *et al.*, 2004; Gonzalez-Otero *et al.*, 2009; Ord *et al.*, 2010) 2 patients complained of a slow growing

**PRISMA 2009 Flow Diagram**



## DISCUSSION

Osteochondroma, an exophytic growth developing in cortical bone, accounts for 8% to 15% of all primary bone tumours. It frequently occurs elsewhere in the skeleton, but is rare in the craniofacial region. (Roychoudhary *et al.*, 2011; Wolford *et al.*, 2002; Wolford *et al.*, 2014; Karras *et al.*, 1996) Most cases of osteochondroma present with facial asymmetry and disturbed occlusion as the chief complaint, with no impairment of TMJ movements. Malocclusion generally shows ipsilateral posterior openbite and contra-lateral cross bite with severe cases, a shift of midline may occur. Although the conventional treatment for osteochondroma of mandibular condyle is condylectomy, this procedure can result in extensive and unnecessary tissue removal, which may necessitate secondary procedures for reconstruction. Various studies have been found in literature where a more conservative surgery has given successful outcomes. Hence this study was undertaken to review all these previous studies of radical as well as conservative treatment protocols for managing osteochondroma of mandibular condyle and come to same definitive conclusion. We have observed that of the full text articles that were available to us, most of them

painless swelling in the preauricular region. (Ord *et al.*, 2010) All the lesions were confirmed to be osteochondroma of mandibular condyle. The tumour size ranged between 1cm to 4cm at maximum dimension. However many studies have not documented the tumour size. (Utumi *et al.*, 2010; Saito *et al.*, 2001; Holmlund *et al.*, 2004; Gonzalez-Otero *et al.*, 2009; Ord *et al.*, 2010) The standard investigations indicated were panoramic view, CT scan, MRI and bone scintigraphy. It was observed that CT scan was done in all 24 patients, but panoramic view was done in only 10 patients, (Utumi *et al.*, 2010; Peroz *et al.*, 2002; Jaffee, 1961; Cimino *et al.*, 2003; Holmlund *et al.*, 2004; Gonzalez-Otero *et al.*, 2009; Ord *et al.*, 2010) MRI was done in only 3 patients (Peroz *et al.*, 2002; Cimino *et al.*, 2003; Ord *et al.*, 2010) and bone scintigraphy was done in only 3 patients (Utumi *et al.*, 2010; Saito *et al.*, 2001; Ord *et al.*, 2010).

Although bone scintigraphy is indicated in only growing patients to evaluate the growing potential of the tumour, the other investigations should also be standardized for complete comparison. Also the correlation of the tumour size with the surgical plan done is of utmost importance to know the surgical

outcome and its effect on the dentition and ultimately the functional rehabilitation. Most of the patients had postero-lateral openbite and mandibular deviation causing shift in the dental midline. However 1 study has not described the dental malocclusion in detail. As the tumour size increases, the severity of the dental malocclusion increases and thus the surgical treatment plan requires modification. It is here that additional that additional orthognathic procedures may be required for extensive tumour size. The surgical procedures performed for these kind of tumour excision are basically of two types-A more conservative procedure called condyloplasty where only the tumour is excised and the condylar fossa and a more radical approach where the condyle is completely excised i.e. the osteotomy cut is placed at the condylar neck, the procedure termed as condylectomy. Of the 25 cases, 14 underwent condyloplasty and 10 underwent condylectomy. Here again it was noticed that because the tumour size is not documented in every case, its correlation with the surgical procedure cannot be done. 12 patients required additional orthognathic procedures like ipsilateral vertical ramus osteotomy (Holmlund *et al.*, 2004; Gonzalez-Otero *et al.*, 2009; Ord *et al.*, 2010) and contralateral saggital split ramus osteotomy (Holmlund *et al.*, 2004). Additional procedures like minor orthodontic correction and physiotherapy were documented in 6 patients only. (Utumi *et al.*, 2010; Kim *et al.*, 2015) The post-operative follow-up period of all the patients varied from minimum of 3 months to a maximum of 7 years 1 month. All these patients were recurrence free except 1 (Peroz *et al.*, 2002), but she did not require a secondary procedure as she was symptom free and maintained a good mouth-opening. Two patients had transient marginal mandibular weakness and one of them had transient inferior alveolar nerve weakness too. (Ord *et al.*, 2010) Our observation states that all included studies are either single case reports or a case series of 4-5 patients. The drawback of these studies is that the tumour size is not documented in all cases, hence its effect on surgical outcome cannot be analysed. Although the surgical outcome in terms of post-operative result is very good in all cases, the follow-up period varies to a large extent.

### Limitations

During the course of study we have come across a few limitations. These are as follows

1. Access to full text of all relevant studies was not possible.
2. All the available articles do not have a common standard protocol. Because of this comparison of few parameters like tumour size was not possible.
3. There is a vast variation of follow-up period of different patients.
4. Some patients have required additional orthognathic procedures, but in these cases, the authors have not mentioned the tumour size. So the co-relation between tumour size and the management protocol of radical versus conservative condylar resection cannot be achieved.

### Conclusion

We have observed that in the initial years conservative approach was done. This was overtaken by a more radical approach in the middle years. But towards the most recent years, a more of conservative approach is preferred over the

radical approach. Mandibular condylar osteochondroma is thought to be a relatively rare lesion occurring in the facial skeleton. Gradual facial asymmetry over the years is the most striking feature. The treatment modality for osteochondroma of mandibular condyle could be conservative condylectomy or total condylectomy. Both the procedures are curative. Additional procedures like orthognathic surgery may be required in extensive tumours. The decision, however, depends on the tumour size and how much swing of mandible is required post-surgery for correction of asymmetry and occlusion.

### Future implications

Both conservative condylectomy and radical condylectomy are curative in treating osteochondroma of mandibular condyle. Additional procedures may be required in extensive tumours where condylectomy is a must. With condylectomy, problems like openbite and malocclusion may occur and restoration of the vertical height and condylar head may be achieved with either costochondral grafting or superiorly repositioned vertical ramus osteotomy. These procedures would achieve a more stable result and better function in the long run. We thus advocate the readers to kindly follow proper documentation of tumour size, take proper radiographs/ CT scan and have a minimum follow-up of 1 year for these kind of benign tumour.

### Funding

None received.

### Competing interests

None declared.

### Ethical approval

Not required.

### Patient Consent

Not required.

### Acknowledgements

We gratefully acknowledge the support of Dr. Pradnya Kakolkar.

### REFERENCES

- Cimino R, Steenks M. H, Michelotti A, Farella M, Francesco N. P. 2003. Mandibular Condyle Osteochondroma. Review of the Literature and Report of a Misdiagnosed Case. *J Orofac Pain*, 17: 254-261.
- Gonzalez-Otero S, Navarro-Cuellar C, Escrig-de T, Fernandez-Alba-LuengoJ, Navarro-Vila C. 2009. Osteochondroma of the mandibular condyle: Resection and reconstruction using vertical sliding osteotomy of the mandibular ramus *Med Oral Patol Oral Cir Bucal.*, 14(4): E194-7.
- Holmlund A. B, Gynther G. W, Reinholt F. P. 2004. Surgical treatment of osteochondroma of the mandibular condyle in the adult A 5-year follow-up. *Int. J. Oral Maxillofac. Surg.*, 33: 549-553.
- Jaffee HL. 1961. Tumours and tumorous conditions of the bones and joints. Philadelphia: Lea & Febiger, 150-166.

- Karras SC, Wolford LM, Cottrell DA. 1996. Concurrent osteochondroma of the mandibular condyle and ipsilateral cranial base resulting in temporomandibular joint ankyloses: report of a case and review of the literature. *J Oral Maxillofac Surg.*, 54: 640-6.
- Kim D. S, Kim J, Jeong C, Park K, Huh J. 2015. Conservative condylectomy alone for the correction of mandibular asymmetry caused by osteochondroma of the mandibular condyle: a report of five cases, *J Korean Assoc Oral Maxillofac Surg.*, 41: 259-264.
- Obwegeser HL, Makek MS. 2002. Hemimandibular hyperplasia-hemimandibular elongation. *J Cranio-Maxillofac Surg.*, 30: 355-360.
- Ord R. A, Waeburton G, Caccamese J. F. 2010. Osteochondroma of the condyle: review of 8 cases. *Int. J. Oral Maxillofac. Surg.*, 39: 523-528.
- Ortakoglo K, Akcam T, Sencimen M, Karakoc O, Ozyigit HA, Bengi O. 2007. Osteochondroma of the mandible causing severe facial asymmetry: a case report. *Oral Surg Oral Med Oral Pathol Oral Radiol Endod.*, 103: e21-28.
- Peroz I, Scholman J, Hell B. 2002. Osteochondroma of the mandibular condyle: a case report. *Int. J. Oral Maxillofac. Surg.*, 31: 455-456.
- Porter DE. and Simpson AH. 1999. The neoplastic pathogenesis of solitary and multiple osteochondromas. Review. *J Oral Pathol.*, 188: 119-125.
- Roychoudhary A, Bhatt K, Yadav R, Bhutia O, Roychoudhary S. 2011. Review of osteochondroma of mandibular condyle and report of a case series. *J Oral Maxillofac Surg.*, 69: 2815-23.
- Saito T, Utsunomiya T, Furutani M, Yamamoto H. 2001. Osteochondroma of the mandibular condyle: a case report and review of the literature. *Journal of Oral Science*, 43(4): 293-297.
- Seki H, Fukuda M, Takahashi T, Ino M. 2003. Condylar Osteochondroma with Complete Hearing Loss: Report of a case. *J Oral Maxillofac Surg.*, 61: 131-133.
- Slootweg PJ, Muller H. 1986. Condylar hyperplasia. A clinicopathological analysis of 22 cases. *J Max-Fac Surg.*, 14: 209-214.
- Utumi E. R, Pedron I. G, Perrella A, Zambon C. E, Cecchetti M. M, Cavalcanti M. G. P. 2010. Osteochondroma of Temporomandibular Joint: A Case Report. *Braz Dent J.*, 21(3): 253-258.
- Veazeau J, Fridrich KL, Vincent SD. 1995. Osteochondroma of the mandibular condyle: Literature review and report of two cases. *J Oral Maxillofac Surg.*, 53: 954-963.
- Wolford LM, Mehra P, Franco P. 2002. Use of conservative condylectomy for treatment of osteochondroma of mandibular condyle. *J Oral Maxillofac Surg.*, 60: 262-8.
- Wolford LM, Movahed R, Dhameja A, Allen WR. 2014. Low condylectomy and orthognathic surgery to treat mandibular condylar osteochondroma: a retrospective review of 37 cases. *J Oral Maxillofac Surg.*, 72: 1704-28.
- Wu W, Hu X, Lei D. 2007. Gaintosteochondroma derived from pterygoid process of sphenoid. *Int J Oral Maxillofac Surg.*, 36: 959-962.

\*\*\*\*\*