



## REVIEW ARTICLE

### PERIODONTAL ABSCESS

**\*Shende, Sumit, Ansari, Salman, Gattani, Deepti, Bhutada, Girish, Meshram, Sneha and Jirafe, Sanjana**

Swargiya Dadasaheb Kalmegh Smruti Dental College and Hospital, Department of Periodontology

#### ARTICLE INFO

##### Article History:

Received 16<sup>th</sup> November, 2017  
Received in revised form  
23<sup>rd</sup> December, 2017  
Accepted 10<sup>th</sup> January, 2018  
Published online 18<sup>th</sup> February, 2018

##### Key words:

Thermal and Electric Tests,  
Periodontal Abscess,  
Multifactorial,  
Anamnesis,  
Host Tissue Response.

#### ABSTRACT

Abscesses in the periodontium always poses a unique challenge for a clinician as they are associated with severe bone loss, intrabony defects and deep periodontal pockets. Periodontal abscess is multifactorial in nature as gram negative organisms predominated over gram positive organisms. It is the third most common dental emergency. Periodontal abscess is associated with non periodontitis periodontal lesions and in patients with periodontitis. Diagnosis of periodontal abscess depends upon source of infection, prognosis, clinical signs and symptoms, clinical history, radiographic and histologic findings. Treatment of periodontal abscess is confined to its control of acute conditions and management of preexisting lesions. Treatment of periodontal abscess also includes systemic antimicrobial therapy in patients with general symptoms like fever, chills and rashes. As, It is a mixed infection, broad spectrum antibiotics like Metronidazole, Augmentin and Tetracyclines are used.

Copyright © 2018, Shende, Sumit et al. This is an open access article distributed under the Creative Commons Attribution License, which permits unrestricted use, distribution, and reproduction in any medium, provided the original work is properly cited.

Citation: Shende, Sumit, Ansari, Salman, Gattani, Deepti, Bhutada, Girish, Meshram, Sneha and Jirafe, Sanjana. 2018. "Periodontal abscess", *International Journal of Current Research*, 10, (02), 65097-65102.

#### INTRODUCTION

Periodontium of tooth confines to the periodontal ligament, alveolar bone, gingiva and cementum. Odontogenic infections involving periodontium may lead to emergencies such as dental abscesses in dental practice. Abscesses in periodontium are caused by improper oral hygiene following surgical therapy, pulpal infections leading to periodontal involvement, pericoronitis and trauma to underlying periosteum. Periodontal infections including periodontitis, pericoronitis and perio-endo lesion may give rise to abscesses in the periodontium if left untreated. Abscesses in the periodontium includes gingival, pericoronal and periodontal abscess. Abscesses in the periodontium can be defined as 'a lesion with an expressed periodontal breakdown occurring during a limited period of time, and with easily detectable clinical symptoms, including a localized accumulation of pus located within the gingival wall of the periodontal pocket'. Among all the dental emergencies, abscesses were seen 41% associated with first molar, 24% with second molar, 17% with upper premolars, 7% with lower premolars, 7% with incisors and 3.5% with upper third molars. Among all the abscesses of periodontium, the periodontal abscess is the most important one.

The periodontal abscess is the third most common dental emergency (6-14 %), first is the Dentoalveolar abscess/pulpal infection (14-25 %) followed by pericoronitis (10-11 %). There was one study conducted in US in and he found that among all total emergencies in dentistry, periodontal abscess comprised of almost 14% (Ahl, 1999). Periodontal abscess is defined as 'A periodontal abscess is a localized, purulent infection involving a greater dimension of the gingiva, extending apically and adjacent to a periodontal pocket. A periodontal abscess can also be termed as lateral abscess or parietal abscess; however, when marginal soft tissues such as marginal gingiva are affected in isolation, it is called a gingival abscess. Periodontal abscess and gingival abscess are identical histologically and differ only in location. According to international workshop for a classification of periodontal diseases and conditions (1999):

They are classified as –

- Periodontal
- Periapical
- Gingival
- Pericoronal (Meng, 1999).

Periodontal abscess is classified according to its etiology, course of the lesion, number of abscess and location of abscess.

\*Corresponding author: Shende Sumit, MDS II

Swargiya Dadasaheb Kalmegh Smruti Dental College and Hospital,  
Department of Periodontology.

According to etiology of the lesion, periodontal abscess can be classified as –

- **Periodontitis related periodontal abscess** – periodontal abscess occurs in previously present periodontitis or previously present biofilm in deepened periodontal pocket (DeWitt *et al.*, 1985).
- **Non periodontitis periodontal abscess** - periodontal abscess can develop in healthy sites or from another local source for e.g. impacted food particles or foreign body (pieces of dental floss, toothbrush bristles) and alteration in root morphology (Gillette, 1980; Pini Prato *et al.*, 1988).

According to course of the lesion, periodontal abscess can be classified as

- **Acute periodontal abscess** – An acute periodontal abscess can manifest as painful swelling with red inflamed area. Swelling is usually tender on palpation and suppuration can occur upon gentle pressure. Pain is usually throbbing in nature and lymphadenopathy can be present.
- **Chronic periodontal abscess** – An acute periodontal abscess can become chronic periodontal abscess when drainage is established through the deepened periodontal pocket, gingival sulcus and sinus tract. Abscess can be asymptomatic and develops as an acute exacerbation of acute periodontal abscess. There may be bleeding and pain is usually of low intensity. Tooth may have mobility and it may be tender on percussion (Pini Prato *et al.*, 1988).

According to location, periodontal abscess can be classified as

- **Gingival abscess** – when abscess is confined to marginal gingiva or interdental papilla and swelling is localized and with purulent infection. Impacted subgingival calculus or any other foreign body particles can cause purulent suppuration (De Witt *et al.*, 1985).
- **Periodontal abscess** – when localized purulent infection involves the periodontium and swelling is confined to periodontal tissues (De Witt *et al.*, 1985).
- **Pericoronal abscess**- it is mainly associated with partially impacted tooth (lower third molar usually) or the tooth covered with pericoronal flap i.e. pericoronitis. A localized purulent infection develops within the pericoronal flap which is tender on palpation and causes pus discharge on gentle light pressure. Sometimes, condition is associated with trismus. (Inability to open the mouth). Pain in case of pericoronal abscess ranges from mild to severe throbbing pain.

According to number of abscesses, periodontal abscess can be classified as

- **Single abscess**- when abscess is confined to single tooth.
- **Multiple abscess**- when abscess is confined to more than one tooth (Topollo, 1990).

### Etiology of periodontal abscess

Periodontal abscess can develop in periodontitis affected sites and in non-periodontitis affected sites. In periodontitis periodontal abscess may develop with an acute exacerbation of previously present periodontitis with deep periodontal tortuous

pockets, teeth with furcation involvement and vertical defect which may lead to spread of infection into the surrounding periodontal tissues. Decreased host tissue response and alteration of composition of subgingival bacteria results in diminished capacity to drain the suppuration (Dello Russo, 1985; Carranza *et al.*, 2003).

Periodontal abscess in previously present periodontitis can occur by following ways-

- After nonsurgical periodontal therapy- Following scaling and root planing, dislodged calculus and food particles may gain entry into the deep periodontal pockets which may cause inflammation and suppuration of periodontal tissues (Dello Russo, 1985; Carranza *et al.*, 2003; Dello Russo, 1985; DeWitt, 1985).
- After surgical periodontal therapy- It is associated with the foreign bodies such as resorbable or nonresorbable membranes and bone grafts used for periodontal regenerative procedures (Dello Russo, 1985; DeWitt, 1985).
- Acute exacerbation of untreated periodontitis (Dello Russo, 1985).
- Acute exacerbation of refractory periodontitis (Chace, 1993; McLeod, 1997).
- Acute exacerbation of supportive periodontal therapy (Chace, 1993; McLeod, 1997).
- Systemic antimicrobials without mechanical debridement of subgingival calculus may lead to abscess formation (Topollo, 1990).
- Treatment with nifedipine therapy (Koller-Benz, 1992).
- Resorbable and nonresorbable membranes in guided bone regeneration (Garrett, 1997).

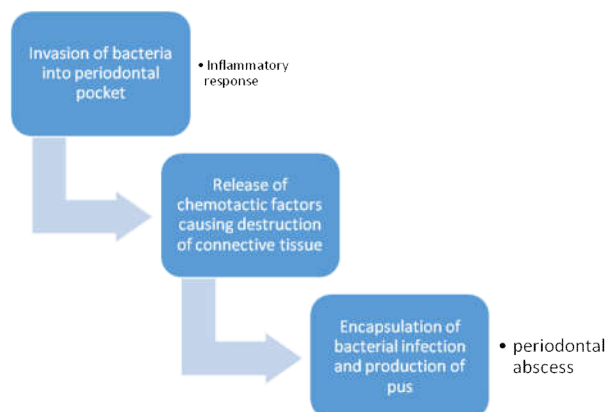
Periodontal abscess can occur in previously healthy sites i.e. non periodontitis patients such as

### Foreign bodies

Orthodontic brackets/elastics/wires, a piece of dental floss, piece of toothbrush bristles or toothpicks, dislodged cemental tear and pieces of nails in nail biting patients. Oral hygiene abscess is the term given for abscess caused by the use of oral hygiene aids (Pini Prato, 1988).

### Alteration in the morphology of root surfaces

Perforation by an endodontic instrument, cervical cemental tears, external root resorption, invaginated tooth and cracked tooth syndrome (Greenberg, 1996; Chen, 1990).



## Course of periodontal abscess

The rate of destruction of periodontal abscess is depending upon following factors

- PH of local tissues (an acidic environment favors the activity of lysozomal enzymes)
- Growth of bacteria inside the focus
- Their virulence

## Histopathology of periodontal abscess

Dewitt GV *et al*, 1985 studied 12 biopsy samples of periodontal abscess patients and observed the following clinical findings

- A normal oral epithelium and lamina propria
- An acute inflammatory infiltrate
- An infiltration of neutrophils and lymphocytes present in area of destroyed and necrotic connective tissue.

Electron microscopy of periodontal abscess revealed that there are more gram negative bacteria, invasion of pocket epithelium and the affected connective tissues shows amorphous, granular and acidophilic debris (De Witt, 1985).

## Microbiology of periodontal abscess

Purulent oral infections are usually multibacterial and are caused by commensal bacteria. In microbiological reports on periodontal abscesses, gram negative bacteria and rods predominated over gram positive bacteria and cocci. The most prevalent bacterial species identified in periodontal abscesses, using culture-based or molecular-based diagnostic techniques, is *Porphyromonas gingivalis*, with a range in prevalence of 50–100% (Topoll, 1990). Other strict anaerobes which are incorporated are *Prevotella intermedia*, *Prevotella melaninogenica*, *Fusobacterium nucleatum*, *Tannerella forsythia*, *Treponema spp.*, *Parvimonas micra*, *Actinomyces spp.* and *Bifidobacterium spp.* Among the facultative anaerobic gram-negative bacteria, *Campylobacter spp.*, *Capnocytophaga spp.* and *Aggregatibacter actinomycetemcomitans*. It is polymicrobial and dominated by nonmotile, anaerobic, gram negative and rod shaped species (Van Winkelhoff, 1985).

## Diagnosis of periodontal abscess

Periodontal abscess is multifactorial in origin, so all the local, systemic and aggravating factors should be taken into consideration while diagnosing periodontal abscess. Diagnosis is based on overall evaluation, past medical and dental history, patient symptoms, together with clinical and radiographic signs (Corbet, 2004).

## Symptoms of periodontal abscess (Ahl, 1999; Herrera, 2000)

### Signs in periodontal abscess patients

Presence of an ovoid elevation in the gingiva, along the lateral part of the root, although abscesses located deep in the periodontium may be more difficult to identify and it may found as a diffuse swelling as a red area (Ahl *et al.*, 1999; Herrera *et al.*, 2000).

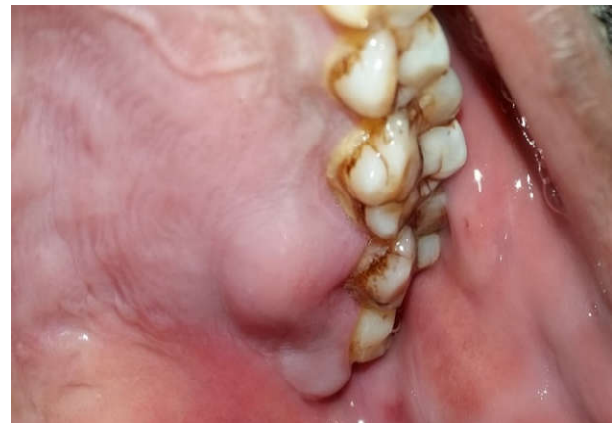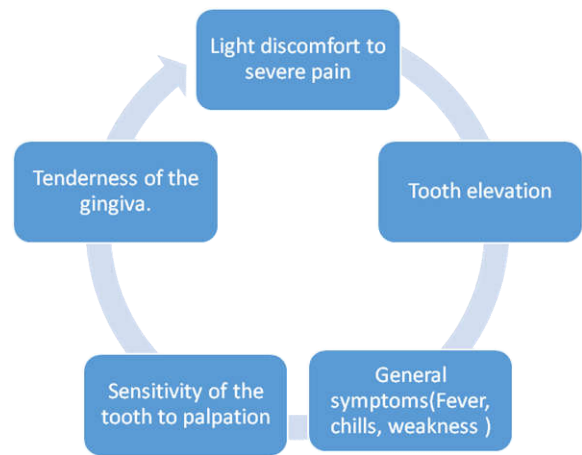


Fig. 1. Palatal periodontal abscess associated with maxillary left second and third molar

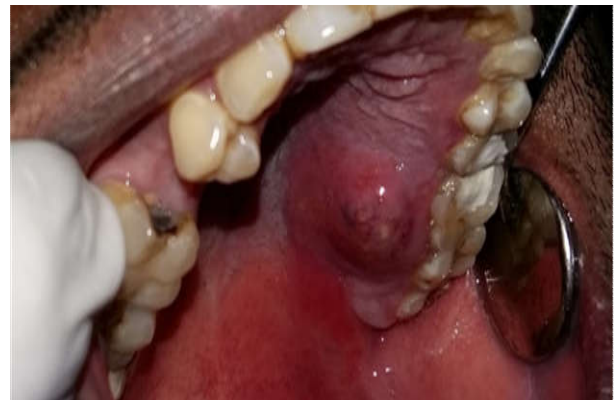

Fig. 2. Periodontal abscess present palatally with maxillary second and third molar

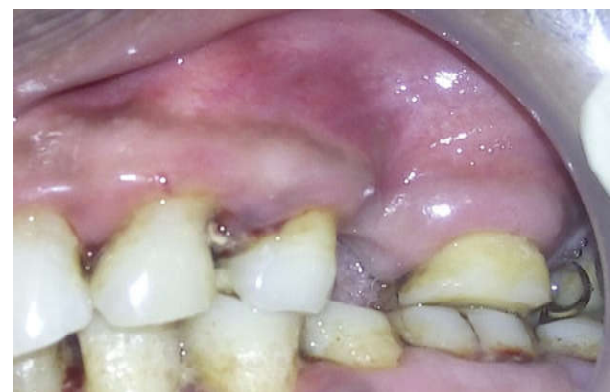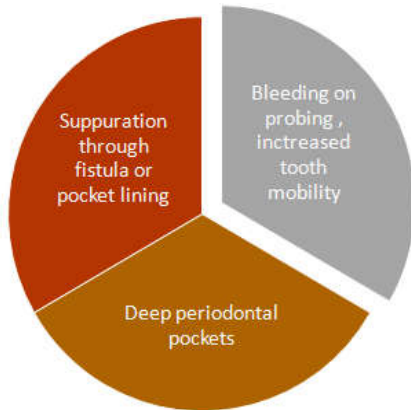


Fig. 3. Gingival abscess associated with maxillary premolar and first molar

## Investigations

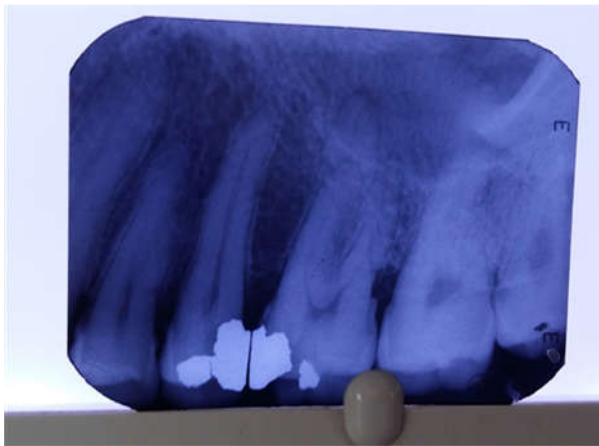
### Radiographs

Intraoral Periapical radiograph, digital orthopantomogram and bite wing radiographs (in case of perio-endo lesion suspecting interdental bone loss) are used to assess the amount of bone loss and periapical condition of involved teeth.



Gutta-percha points placed through the sinus may reveal a source of infection. Following features can be seen

- may reveal a normal appearance or evident bone loss
- widening of periodontal ligament space
- may reveal about the size, shape, location and source of infection (Herrera, 2000).



**Fig. 4. Periodontal abscess radio graphically showing discontinuation of lamina dura and marginal bone loss associated with maxillary premolar and first molar**

### Pulp vitality test

Pulp vitality tests like thermal and electric tests are generally used to assess the vitality of pulp (Herrera, 2000).

### Microbial tests

Samples of pus from sinus/abscess or collected through gingival sulcus sent for microbiological culture and antibiotic sensitivity testing (Herrera, 2000).

### Laboratory investigations

Complete blood count and other hematologic investigations reveals the percentage of increase in neutrophils or monocytes

count which shows the proinflammatory response of bacterial toxins in the periodontal abscess (Herrera, 2000).

### Others

Multiple periodontal abscesses are usually associated with systemic factors like increased blood sugar and with an altered immune response in diabetic patients. Therefore, the assessment of the diabetic status through the testing of random blood glucose, fasting blood glucose or glycosylated hemoglobin levels is necessary to rule out the etiology of the periodontal abscess.

### Anamnesis

It gives the basic information about the etiology and pathogenesis of periodontal abscess, Especially, associated with previous treatments or non-oral therapies such as systemic antimicrobials or periodontal treatment. It is helpful in case of abscess which are related to impaction of foreign bodies or particles. Sometimes the interview with patient depicting the clinical history and other variables may be great help for further treatment planning.

### Differential diagnosis

#### Periodontal abscess may be misundertaken with the following infections or lesions

1. Periapical or Dentoalveolar abscess (Ahl, 1986).
2. Lateral Periapical cyst (Ahl, 1999).
3. Endo-perio lesions.
4. Oral diseases like squamous cell carcinoma, pyogenic granuloma and metastatic carcinoma (Kerr, 1971; Kim *et al.*, 2012).
5. Self-inflicted gingival injuries (Rodd, 1995).

### Treatment plan

Treatment of periodontal abscess depends upon its etiology, local and aggravating factors, host immune response and prognosis.

It includes two phases

- Control of the acute condition to arrest tissue destruction and control the symptoms (Lewis *et al.*, 1989; Abrams *et al.*, 1983).
- Management of pre-existing and / or residual lesion, especially in patients with periodontitis.

### Control of the acute condition

#### There are four therapeutic alternatives

- Drainage of abscess – Drainage of abscess with light and digital pressure through gingival sulcus or periodontal pocket should be carried out under local anesthesia (Lewis *et al.*, 1989; Ahl *et al.*, 1999).
- Debridement- Mechanical debridement of subgingival calculus and removal of any foreign body present in gingival sulcus or deep periodontal pocket should be done in order to rule out the etiology of periodontal abscess (Lewis *et al.*, 1989; Ahl *et al.*, 1999).



- Systemic or local antimicrobials- Broad spectrum antibiotics should be given to arrest the growth of predominant gram negative cocci present in periodontal abscess. Antibiotics including metronidazole, Augmentin, Amoxicillin and broad spectrum antibiotics like doxycycline and tetracyclines also can be given. (Lewis *et al.*, 1989; Ahl *et al.*, 1999).
- Surgery- Subgingival calculus if left after scaling and root planing or any impacted foreign body particle present in deepened periodontal pocket should be debrided (especially furcation defects) through periodontal flap surgery.
- Tooth extraction – Teeth with hopeless prognosis or teeth with grade IV furcation or mobility should be indicated for extraction.

### Studies

- Smith and Davies – He examined 22 abscesses in a 3 year study, and he concluded that together with adjunctive role of systemic antimicrobials like metronidazole (200mg, 3 times in a day, for 5 days) (Smith, 1986).
- Hafstrom *et al* – He stated that drainage through the periodontal pocket, irrigation with sterile saline solution, supragingival scaling and use of tetracyclines for two weeks (1g/day) provides better results as well as better patient compliance (Hafstrom *et al.*, 1994).
- Herrera D *et al*- He compared azithromycin versus amoxicillin plus clavulanate solution and concluded that both are having similar effects (Herrera *et al.*, 2000).
- Eguchi *et al*- He evaluated the comparison of 2% minocycline HCL ointment and irrigation with sterile saline versus irrigation with sterile solution without local antibiotics (Eguchi *et al.*, 2008).
- Taani DS *et al* – A case series evaluating a combination of an access flap with deep scaling and irrigation with doxycycline is also available and have reported good results (Taani, 1996).
- Various surgical procedures have also been proposed mainly for abscess associated with deep vertical defects or in cases occurring after periodontal treatment or debridement in which residual calculus is left after scaling and root planing.

### Management of a pre-existing / residual lesion

- Proper evaluation of periodontal therapy after resolution of the acute phase.
- Cases which have not been treated previously, the appropriate treatment should be provided.
- Those patients receiving supportive periodontal therapy, careful evaluation of recurrence of abscess should be made as well as assessment of tissue damage and prognosis should be done.
- Once the acute lesion has been treated, the periodontal therapy should be completed.

### Summary

The occurrence of periodontal abscesses in patients who are under supportive periodontal treatment has been frequently described. Early diagnosis and appropriate intervention are extremely important for the management of the periodontal

abscess, since this condition can lead to the loss of the involved tooth. A single case of a tooth diagnosed with periodontal abscess that responds favourably to adequate treatment does not seem to affect its longevity. In addition, the decision to extract a tooth with this condition should be taken, while taking into consideration, other factors such as the degree of clinical attachment loss, the presence of tooth mobility, the degree of furcation involvement, and the patient's susceptibility to periodontitis due to the associated systemic conditions.

### REFERENCES

- Abrams H, Kopczyk RA. 1983. Gingival sequela from a retained piece of dental floss. *J Am Dent Assoc* 106: 57–58.
- Ahl DR, Hilgeman JL, Snyder JD. 1986. Periodontal emergencies. *Dent Clin North Am.*, 30: 459–472.
- Carranza, F.A., Camargo, P.M. 2003. The periodontal pocket, in: M.G. Newman MG, H.H. Takei, F.A. Carranza (Ed.), Carranza's clinical periodontology, 9(Philadelphia: Saunders Elsevier), 349.
- Chace, R. and Low, S. 1993. Survival characteristics of periodontally involved teeth: a 40-year study, *J Periodontol* 64, 701-705.
- Chen RJ, Yang JF, Chao TC. 1990. Invaginated tooth associated with periodontal abscess. *Oral Surg Oral Med Oral Pathol*: 69: 659.
- Corbet EF. 2000- 2004. Diagnosis of acute periodontal lesions. *Periodontol*: 34: 204–216.
- Dello Russo, M.M. 1985. The post-prophylaxis periodontal abscess: etiology and management, *Int J Periodont Rest Dent* 1, 29-3.
- Dello Russo, M.M. 1985. The post-prophylaxis periodontal abscess: etiology and management, *Int J Periodont Rest Dent* 1, 29-37.
- DeWitt GV, Cobb CM, Killoy WJ. 1985. The acute periodontal abscess: microbial penetration of the soft tissue wall. *Int J Periodontics Restorative Dent.*, 5: 38-51.
- DeWitt, G.V., Cobb, C.M. and Killoy, W.J. 1985. The acute periodontal abscess: Microbial penetration of the soft tissue wall, *Int J Periodont Rest Dent.*, 5, 39.
- Eguchi T, Koshy G, Umeda M, Iwanami T, Suga J, Nomura Y, Kawanami M, Ishikawa I. 2008. Microbial changes in patients with acute periodontal abscess after treatment detected by PadoTest. *Oral Dis.*, 14: 180–184.
- Garrett, S., Polson, A.M., Stoller, N.H., Drisco, C.L., Caton, J.G., Harold, C.Q., Bogle, G., Greenwell, H., Lowengath, R.A., Duke, S.P., and DeRouen, T.A. 1997. Comparison of a bioresorbable GTR barrier to a non-absorbable barrier in treating human class II furcation defects: A multicenter, parallel design, randomized, single-blind trial, *J Periodontol* 68, 667-675.
- Gillette WB, Van House RL. 1980. Ill effects of improper oral hygiene procedure. *J Am Dent Assoc.*, 101: 476–480.
- Greenberg MS. 1996. Herpesvirus infections. *Dent Clin North Am*: 40: 359–368.
- H.H. Topollo, D.E. Lange, and R.F. Muller, 1990. Multiple periodontal abscesses after systemic antibiotic therapy, *J Clin Periodontol* 17, 268-272
- Hafstrom CA, Wikstrom MB, Renvert SN, Dahlen GG. 1994. Effect of treatment on some periodontopathogens and their antibody levels in periodontal abscesses. *J Periodontol.*, 65: 1022–1028.
- Herrera D, Roldan S, Gonzalez I, Sanz M. 2000. The periodontal abscess (I). Clinical and microbiological findings. *J Clin Periodontol.*, 27: 387–394.

- Kerr DA, McClatchey KD, Regezi JA. 1971. Allergic gingivostomatitis (dueto gum chewing). *J Periodontol* 42: 709–712.
- Kim OS, Uhm SW, Kim SC, Lee BA, Kim OJ, Kim YJ, Chung HJ. 2012. A case of squamous cell carcinoma presenting as localized severe periodontitis in the upper gingiva. *J Periodontol*: 83: 753–756.
- Koller-Benz, G., Fritzsche, A. and Krapf, R. 1992. Nifedipine induced gingival Abscesses, *Br Med J.*, 304, 1225.
- Lewis MA, Meechan C, MacFarlane TW, Lamey PJ, Kay E. 1989. Presentation and antimicrobial treatment of acute orofacial infections in general dental practice. *Br Dent J.*, 166: 41–45. 178.
- McLeod, D.E., Lainson, P.A. and Spivey, J.D. 1997. Tooth loss due to periodontal abscess: a retrospective study, *J Periodontol* 68, 963-966.
- Meng HX. 1999. Periodontal abscess. *Ann Periodontol*: 4: 79–83.
- Pini Prato GP, Cortellini P, Clauser C. 1988. Fibrin and fibronectin sealing system in a guided tissue regeneration procedure. A case report. *J Periodontol.*, 59: 679–683.
- Rodd HD. 1995. Self-inflicted gingival injury in a young girl. *Br Dent J.*, 178: 28–30.
- Smith RG, Davies RM. 1986. Acute lateral periodontal abscesses. *Br Dent J.*, 161: 176–178.
- Taani DS. 1996. An effective treatment for chronic periodontal abscesses. *Quintessence Int*: 27: 697–699.
- Topoll HH, Lange DE, Muller RF. 1990. Multiple periodontal abscesses after systemic antibiotic therapy. *J Clin Periodontol*: 17: 268–272.
- Van Winkelhoff AJ, Carlee AW, de Graaff J. 1985. *Bacteroides endodontalis* and other black-pigmented *Bacteroides* species in odontogenic abscesses. *Infect Immun*: 49: 494–497.

\*\*\*\*\*