



RESEARCH ARTICLE

EVALUATION OF SIMULTANEOUS FEMTOSECOND-ASSISTED MYORING IMPLANTATION AND INTRASTROMAL POCKET CORNEAL COLLAGEN CROSS-LINKING FOR MANAGEMENT OF PROGRESSIVE POST LASIK ECTASIA

*Nour Elden A Abdelhalim and Mahmoud A Saleh

Department of Ophthalmology, Faculty of Medicine, Al-Azhar University, Egypt

ARTICLE INFO

Article History:

Received 21st November, 2017
Received in revised form
17th December, 2017
Accepted 09th January, 2018
Published online 28th February, 2018

Key words:

Post Lasik ectasia,
Femtosecond laser,
Myo Ring,
CXL.

ABSTRACT

Purpose: To evaluate femtosecond assisted implantation of MyoRing and Corneal Collagen Cross-Linking in an Intrastromal Pocket in One Session for management of progressive post Lasik ectasia. **Methods:** In this study, 20 eyes of 14 patients with progressive post Lasik ectasia a MyoRing (Dioptex, GmbH, Austria) was implanted using a femtosecond laser and Corneal Collagen Cross-Linking in an Intrastromal Pocket in One Session. Uncorrected and corrected distance visual acuity, refraction, keratometry, central corneal thickness, corneal biomechanical profile, and corneal aberrometry were evaluated preoperatively and at 1, 3, and 6 months, and 1 year postoperatively. **Results:** Twelve months postoperatively there was a statistically significant improvement in Uncorrected distance visual acuity and Corrected distance visual acuity (1.01 ± 0.31 , 0.50 ± 0.11 to 0.29 ± 0.01 , 0.3 ± 0.14 respectively) ($P < 0.001$). Mean keratometry changed significantly from 51.18 ± 4.82 to 42.91 ± 2.91 ($P < 0.001$), and sphere (-4.97 ± 3.06 diopters Improved to -0.55 ± 1.63 diopters ($P < 0.001$). Corneal hysteresis and corneal resistance factor showed no significant change during follow up Mean \pm SD follow-up was 13 ± 5 months. **Conclusions:** Combination of these two minimally invasive MyoRing and Corneal Collagen Cross-Linking in an Intrastromal Pocket in One Session procedures had the capability in halting the progression of post Lasik ectasia and can be considered an acceptable method to achieve corneal remodeling and alternative to lamellar or penetrating lamellar keratoplasty.

Copyright © 2018, Nour Elden A Abdelhalim and Mahmoud A Saleh. This is an open access article distributed under the Creative Commons Attribution License, which permits unrestricted use, distribution, and reproduction in any medium, provided the original work is properly cited.

Citation: Nour Elden A Abdelhalim and Mahmoud A Saleh, 2018. "Evaluation of simultaneous femtosecond-assisted myoring implantation and intrastromal pocket corneal collagen cross-linking for management of progressive post lasik ectasia", *International Journal of Current Research*, 10, (02), 65943-65947.

INTRODUCTION

Post-LASIK ectasia or corneal ectasia is a rare but serious complication of LASIK laser eye surgery. (Pallikaris *et al.*, 2001) The major risk factors for ectasia after refractive laser surgery are deep ablation, residual stromal thickness of less than 250 μ m, (Kim *et al.*, 2007; Randleman *et al.*, 2003) retreatments, and pre-existing abnormal corneal topography such as forme fruste keratoconus and pellucid marginal degeneration. (Binder, 2003) Studies suggest it may occur in roughly one of every 2,000 LASIK procedures. Most cases of post-LASIK ectasia can be successfully treated; the treatments are similar to those used to treat keratoconus. In the past, the primary treatment options were rigid gas permeable (RGP or GP) contact lenses and implantation of intrastromal corneal ring segments, such as Intacs. (Hamilton *et al.*, 2008; Seiler *et al.*, 1998) The use of Intacs for post-LASIK ectasia has been previously reported with positive results. Treatment of post-

LASIK ectasia with cross-linking procedures has also shown promise. Combined ICRS implantation and collagen cross-linking produced a dramatic, stable visual outcome in many studies. (Kymionis *et al.*, 2006; Siganos *et al.*, 2002; Kymionis *et al.*, 2009) The recently proposed Myo Ring is a complete intrastromal ring designed to be placed into a corneal pocket. A potential advantage of the MyoRing over ring segments is its effectiveness on advanced keratoconus and also its ability to reduce keratometric power of the cornea much more. (Jabbarvand *et al.*, 2013; Alio *et al.*, 2011) In current study MyoRing was used to flatten the periphery of the central corneal apex, while cross-linking induces additional covalent bonds between collagen molecules to increase corneal strength for management of selected cases with progressive post Lasik ectasia.

MATERIALS AND METHODS

This was a prospective, randomized, interventional clinical study of 20 eyes of 14 patients treated with Femtosecond assisted MyoRing implantation and Corneal Collagen Cross-

*Corresponding author: Nour Elden A Abdelhalim,
Department of Ophthalmology, Faculty of Medicine, Al-Azhar
University, Egypt.

Linking in an Intrastromal Pocket in One Session for progressive ectasia after LASIK. All procedures were performed by one surgeon (author) from March 20014 to August 2015. All patients provided written informed consent. Ectasia was defined as topographic steepening of 5 diopters (D) or more compared with immediate postoperative appearance, loss of 2 lines or more of Snellen acuity, and a change in manifest refraction of 2 D or more of either sphere or cylinder. (Kymionis *et al.*, 2006) Progression was defined by an increase of maximum keratometry readings (K_{max}) of the anterior corneal surface, at 3.0 mm from the apex, of at least 1.0 D in corneal topographies over a maximum of 12 months.⁸ Central corneal thickness (CCT) by optical and ultrasonic pachymetry was at least 400um. None of the patients had a history of corneal surgery, chemical injury, or delayed epithelial healing or was pregnant or lactating during the treatment. Preoperative and postoperative examinations included CDVA, UCDVA slit-lamp evaluation, Goldmann applanation tonometry, corneal topography, and minimal and central corneal thickness by Scheimpflug imaging (Pentacam; Oculus Instruments, Wetzlar, Germany), ultrasonic pachymetry (Tomey Corporation, Nahoya, Japan). The Ocular Response Analyzer was used to measure corneal hysteresis (CH), corneal resistance factor (CRF).

Surgical Technique

After topical anesthesia by 0.5 % propacaine hydrochloride eye drops. First, the pupil center was marked with a Sinsky hook before applanation. This mark was used as a reference point to locate the incision and to center the MyoRing after implantation. A corneal pocket was created with a femtosecond laser (Victus Femto Second Laser SW version 3.2 Technolas Perfect Vision GmbH .Munich, Germany) at a depth of 80% of corneal thickness with a pocket diameter 8.0 mm, frequency 80KHz, energy 0.95micro Jules, spot spacing

and line spacing of 5.2 micrometer. A temporal upper corneal incision of 90 degrees of arc length was made, and afterwards an intra stromal pocket was created. Once the pocket was created, a continuous 360° intrastromal ring Myo Ring (DIOPTEX GmbH, Linz, Austria) with a diameter of 6 mm and thickness of 350 μ in all cases. A sterile standard dose of riboflavin without dextran (0.1% riboflavin, Mediocross-sine, Medio-HAUS Medizinprodukte GmbH, Germany) was continuously injected over 1 minute into the corneal pocket via a standard cannula of 0.3 mm diameter through the incision tunnel. The instillation of the dye resulted in a yellowish colour of the anterior and posterior stroma, visible in the slit-lamp microscopy. The cornea was irradiated with UV-A light of 365 nm (Peschke Meditrade GmbH, Switzerland) and UV intensity of 3 mW/cm² for 30 minutes. The intracorneal tunnel is self-sealing, and the procedure requires no suturing. After the procedure local antibiotics, fluorometholone 0.1% were described for one week and lubricant prescribed for two months. Slit lamp examination was performed for all patients on the first postoperative day. The patients received ophthalmic examinations at 1, 3, 6, and 12months after the operation.

Statistical Analysis

Statistical analysis was performed using SPSS statistic software, version 15.0, for Windows (SPSS, Inc., IL, USA). Preoperative data versus postoperative data were analysed using the paired *t*-test. Statistical measures are the mean ± standard deviation and significant *P* values are less than 0.05.

RESULTS

Twenty eyes of 14 patients (5 male, 9 female) with progressive ectasia after LASIK were included. The mean ± standard deviation (SD) patients age was 31±7 years (range, 21–39 years).

Table 1. Postoperative

V A	Preoperative	1month	3months	6months	12months	Pvalue
CDVA	0.50 ± 0.11	0.30 ± 0.18	0.29 ± 0.11	0.25 ± 0.11	0.3 ± 0.14	0.001
UCVA	1.01 ± 0.31	0.27 ± 0.13	0.17 ± 0.13	0.14 ± 0.16	0.29 ± 0.01	0.001

The Mean ± SD k_1 was 48.22±4.64 with axis 51.22±58.31 and the Mean ± SD k_2 51.58±5.23with axis 98.30±28.32preoperatively, the k reading improved to 42.12±3.81 with axis 39.83±29.58, and 44.76±2.18)with axis 121.30±23.62(P<0.001). The mean k reading (k_m) Mean ± SD preoperatively was 51.18±4.82 improved to 42.91±2.91 (P< 0.001) table (2) figure (1).

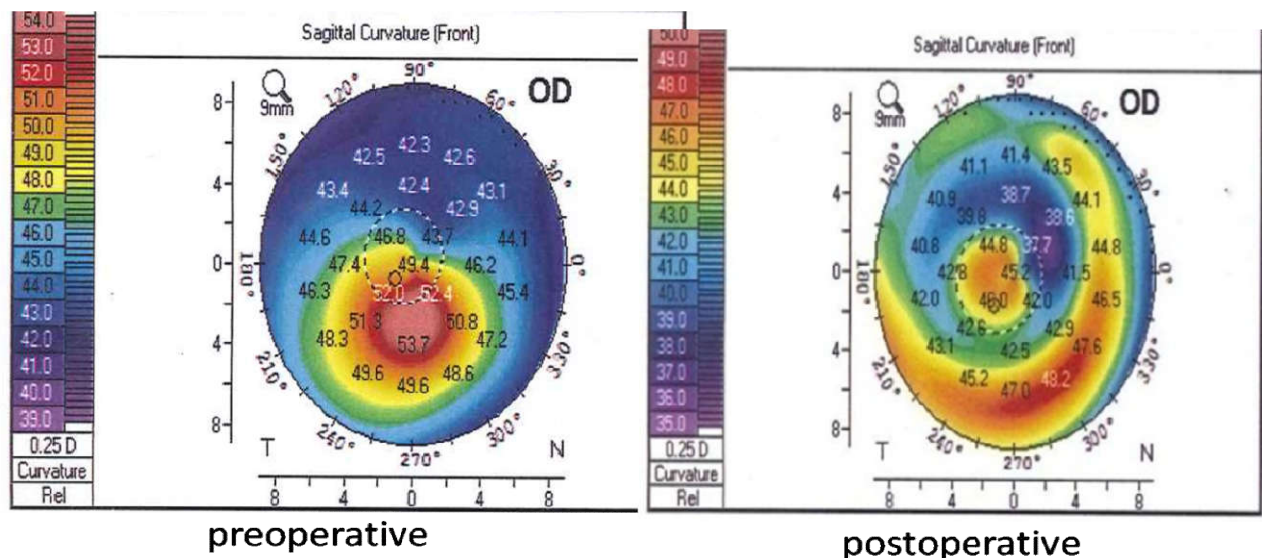


Figure 1. Preoperative and postoperative map with improvement in k_1 and k_2

Table 2.

		Preoperative	Postoperative	P- value
K1	D	48.22±4.51	42.12±3.81	0.001
	axis	51.22±58.31	39.83 ±29.58	0.423
K2	D	51.58±5.23	44.76±2.18	0.001
	axis	98.30±28.32	120.31±22.55	0.001
Meank(k _m)		51.18±4.82	42.91±2.91	0.001

Table 3.

	Preoperative	Postoperative	P-value
Rh	7.03±0.78	7.92±0.60	0.001
Rv	6.55±0.69	7.55±0.56	0.001
Rm	6.67±0.61	7.73±0.41	0.001
Back elevation	50.62±10.63	47.52±10.47	0.233
Refraction	-4.97± 3.06	- 0.55 ±1.63	0.001

Table 4. Postoperative

	Preoperative	1month	3months	6months	12months	Pvalue
CH	7.7 ± 1.79	8.2 ± 1.53	7.8 ± 1.08	7.8 ± 1.18	7.4 ± 2.09	0.332
CRF	8.1 ± 3.28	9.1 ± 2.92	8.8 ± 3.12	9.0 ± 2.72	8.4 ± 3.48	0.341
CH= corneal hysteresis		CRF= corneal resistance factor				

Eight eyes (58%) had undiagnosed keratoconus, and 6 eyes patients (12%) had a deep stromal ablation. In 6 eyes (15%), the cause of the ectasia was not clear. Mean ± SD follow-up was 13±5 months (range, 12–18 months). No eyes were lost to follow-up. Mean ± SD Corrected distance visual acuity (CDVA) was 0.5±0.11 before procedure (range, 0.1–1.0) and improved to 0.3±0.14 (range, 0.1–0.6 after 12 months of treatment. UCVA was improved from (1.01 ±0.31) to (0.29±0.1) (P<0.001) after 12 months of treatment Table (1). The corneal eccentricity Mean ± SD preoperatively was -0.34±1.16 changed to -0.85±2.43 (P= 0.355), the pupil center was 442.23±44.46 improved to 473.56±42.16 (P< 0.001). Also the thinnest location of the cornea preoperatively was 431.51±43.98 improved to 455.22±35.54 (P 0.003). The anterior chamber depth (AC) Mean ± SD was 3.39±0.31 changed to 3.12±0.20 (P< 0.002). The angle of AC was 36.48±4.47 improve to 28.80±5.58 (P< 0.000), the pupil diameter was 3.3±0.54 changed to 3.42±0.50 (P< 0.421). The corneal biomechanical properties (corneal hysteresis and corneal resistance factor) did not change significantly with MyoRing implants. Preoperatively, Corneal Hysteresis and Corneal resistant factor was (7.7 ± 1.79 and 8.1 ± 3.28 respectively) postoperatively was (7.4 ± 2.09 and 8.4 ± 3.48 respectively) (p=0.332 and 0.341 respectively) Table (4).

DISCUSSION

Combined ICRS implantation and collagen cross-linking produced a dramatic, stable visual outcome in many studies. (Kymionis *et al.*, 2006; Siganos *et al.*, 2002; Kymionis *et al.*, 2009) Although there are some studies on different aspects of clinical outcomes of MyoRing implantation in keratoconus, (Sharma and Boxer Wachler, 2006; Alio *et al.*, 2002) few study is available on MyoRing implantation for ectasia after LASIK. Recently, techniques combining intrastromal corneal ring segment and CXL with the intrastromal administration of riboflavin have been described. A theoretical advantage of this method is the combination of two effects onto the ectatic cornea. Alió *et al.* (Shetty *et al.*, 2008) report that CXL with intrastromal riboflavin injection seemed to be as effective for corneal and refractive changes as classic CXL, although with potentially less postoperative pain. The aim of current study to evaluate MyoRing implantation in the corneal periphery to

flattens the central corneal apex and Corneal Collagen Cross-Linking in an Intrastromal Pocket in One Session to induce additional bonds between collagen molecules to increase corneal strength. In current study the improvement of CDVA was slowly compared to UDVA. The improvement of UDVA was more significant compared to CDVA which was consistent with previous studies. (Mahmood *et al.*, 2011; Sharma and Boxer Wachler, 2006) It may reveal that MyoRing is more effective in reduction of refractive error and less effective in reducing corneal irregularities. Alio *et al.* (Jabbarvand *et al.*, 2013) reported a significant improvement in UDVA at the first week after surgery with no significant changes afterward. 2 Because we believe that many confounding factors, including ocular surface problems and stromal edema, may affect visual acuity in the first few postoperative days, we evaluated visual acuity of our patients 1 month after surgery. Central corneal thickness was increased significantly the mean central corneal thickness preoperatively was 443.31±45.00 increased to 474.61±42.76 in a study performed by Alio *et al.* (2002) reported significant thickening of the central cornea after MyoRing implantation. Also in this study higher-order aberrations and coma and trophile aberrations were reduced significantly after surgery this study is agree with previous studies reported reduction of aberrations after ring segment implantation in keratoconus. (Jabbarvand *et al.*, 2013; Alio *et al.*, 2002) In this study a reduction in the mean corneal keratometry, spherical power and cylindrical power was demonstrated. The changes was more significant in spherical power than the cylindrical power reduction in this study is agree with results of the Alio *et al.* (Jabbarvand *et al.*, 2013) study. If compares this study with previous studies of intrastromal ring implantation for ectasia after LASIK. The mean reduction in spherical refraction was 5.5 D in ectasia after LASIK after the 12-month follow-up visit. In previous studies, reduction in spherical power was between 4 and 6 D for MyoRing and Intacs in different studies. (Jabbarvand *et al.*, 2013; Shetty *et al.*, 2008) Previous studies reported a reduction in cylindrical value between 2.23 and 4.3 D for MyoRing implantation in keratoconus, 2,13 between 0.29 and 1.37 D for ICRS in keratoconus, (Levinger and Pokroy, 2005; Ertan and Kamburoglu, 2008) and between 1.58 and 5.69 D for ICRS in ectasia after LASIK. (Sharma and Boxer Wachler, 2006) The level of keratometry change in current study was closely

related to vision improvement. The level of keratometric changes was significant after 3 months with no significant changes afterward. The change is comparable to previous reports of MyoRing implantation in keratoconic patients. (Mahmood *et al.*, 2011; Sharma and Boxer Wachler, 2006) It is greater than the result of ICRS in the patients with ectasia after LASIK. (Alio *et al.*, 2002)

Anterior chamber depth (ACD) showed a significant decrease from 3.38 ± 0.30 to 3.11 ± 0.20 significant decrease in ACD can be secondary to the flattening of the anterior surface and also increase in the corneal thickness following MyoRing implantation. The corneal biomechanical properties (corneal hysteresis and corneal resistance factor) did not change significantly with MyoRing implants. It was possibly due to implantation of the additional material in the mid-periphery of the cornea and not in the center. The other reason may be low sensitivity of the Ocular Response Analyzer to detect minor changes. (Daxer, 2008) there was an insignificant increase of these parameters in the previous studies on MyoRing and ICRS segments. In patients with corneal ectatic disorders, corneal hysteresis and corneal resistance factor were reported to be lower than in those with normal corneas. (Twa *et al.*, 2004) The present study showed that femtosecond-assisted intracorneal Myoring implantation followed by CXL improved visual acuity and refraction, and decreased keratometric reading 3 months after the procedure in all patients. The results show a significant improvement of K-reading, sphere and cylinder as well as uncorrected distance visual acuity (UDVA) and corrected distance visual acuity (CDVA). The rate of improvement of visual indices and refraction in current study was very similar to a keratoconus studies as the study conducted by Jabbarvand *et al.* (2013) and another study performed by Alio *et al.* (2011) Also Kılıç *et al.* (2012) in their study of 131 eyes with keratoconus, treated by CXL with a riboflavin injection into the corneal channel, combined with intrastromal corneal ring segment implantation, concluded that this technique is effective and the intrastromal riboflavin injection into the tunnel is safe and may provide more penetration without epithelial removal. Daxer *et al.* described the technique of MyoRing implantation and CXL with the intrastromal application of riboflavin into the pocket in one session. Authors presented one case report with a very good result. UDVA increased by 7 lines from 0.05 to 0.25, and the average central K reading decreased by 11 diopters. They noticed corneal haze during the early postoperative period. It diminished in the first month after surgery (Daxer *et al.*, 2010).

Conclusion

The combination of these two minimally invasive therapies, MyoRing and cross-linking, for the treatment of post-LASIK ectasia appears to be a promising alternative to lamellar or penetrating lamellar keratoplasty. Longer follow-up and larger studies are needed to evaluate the refractive and topographic stability of these alternative and desirable treatment options.

REFERENCES

- Alio J, Salem T, Artola A. and Osman A. 2002. Intracorneal rings to correct corneal ectasia after laser in situ keratomileusis. *J Cataract Refract Surg.*, 28:1568-1574.
- Alio JL, Pinero DP. and Daxer A. 2011. Clinical Outcomes after Complete Ring Implantation in Corneal Ectasia Using the Femtosecond Technology: a Pilot Study. *Ophthalmology*, 118:1282–1290.
- Binder PS. 2003. Ectasia after laser in situ keratomileusis. *J Cataract Refract Surg.*, 29:2419–2429
- Dauwe C, Touboul D, Roberts CJ. *et al.* 2009. Biomechanical and morphological corneal response to placement of intrastromal corneal ring segments for keratoconus. *J Cataract Refract Surg.*, 35:1761-1767.
- Daxer A, Mahmoud HA. and Venkateswaran RS. 2010. Corneal crosslinking and visual rehabilitation in keratoconus in one session without epithelial debridement: new technique. *Cornea*, 29(10):1176–1179.
- Daxer A. 2008. Corneal intrastromal implantation surgery for the treatment of moderate and high myopia. *J Cataract Refract Surg.*, 34:194-198.
- Ertan A. and Kamburoglu G. 2008. Intacs implantation using a femtosecond laser for management of keratoconus: comparison of 306 cases in different stages. *J Cataract Refract Surg.*, 34:1521-1526.
- Hamilton DR, Johnson RD, Lee N. and Bourla N. 2008. Differences in the corneal biomechanical effects of surface ablation compared with laser in situ keratomileusis using a microkeratome or femtosecond laser. *J Cataract Refract Surg.*, 34:2049–2056
- Jabbarvand M, Salamatrad A, Hashemian H. *et al.* 2013. Continuous Corneal Intrastromal Ring Implantation for Treatment of Keratoconus in an Iranian Population *Am J Ophthalmol.*, 155:837–842.
- Kılıç A, Kamburoglu G. and Akıncı A. 2012. Riboflavin injection into the corneal channel for combined collagen crosslinking and intrastromal corneal ring segment implantation. *Journal of Cataract and Refractive Surgery*, 38(5):878–883
- Kim TH, Lee D. and Lee HI. 2007. The safety of 250 microm residual stromal bed in preventing keratectasia after laser in situ keratomileusis (LASIK). *J Korean Med Sci.*, 22:142–145
- Kymionis GD, Diakonis VF, Kalyvianaki M. *et al.* 2009. One-year follow-up of corneal confocal microscopy after corneal cross-linking in patients with post laser in situ keratomileusis ectasia and keratoconus. *Am J Ophthalmol.*, 147:774–78.
- Kymionis GD, Tsiklis NS, Pallikaris AI. *et al.* 2006. Long-term follow-up of Intacs for post-LASIK corneal ectasia. *Ophthalmology*, 113:1909–17.
- Levinger S. and Pokroy R. 2005. Keratoconus managed with intacs: one-year results. *Arch Ophthalmol.*, 123:1308-1314.
- Mahmood H, Venkateswaran RS. and Daxer A. 2011. Implantation Of a Complete Corneal Ring In An Intrastromal Pocket For Keratoconus. *J Refract Surg.*, 27: 63-68.
- Pallikaris IG, Kymionis GD. and Astyrakakis NI. 2001. Corneal ectasia induced by laser in situ keratomileusis. *J Cataract Refract Surg.*, 27:1796–1802
- Randleman JB, Russell B, Ward MA, *et al.* 2003. Risk factors and prognosis for corneal ectasia after LASIK. *Ophthalmology*, 2003;110:267–275
- Seiler T, Koufala K. and Richter G. 1998. Iatrogenic keratectasia after laser in situ keratomileusis. *J Refract Surg.*, 14:312–317
- Sharma M. and Boxer Wachler BS. 2006. Comparison of single-segment and double-segment Intacs for keratoconus and post-LASIK ectasia. *Am J Ophthalmol.*, 141:891-895.

- Shetty R, Kurian M, Anand D, Mhaske P, Narayana KM. and Shetty BK. 2008. Intacs in advanced keratoconus. *Cornea.*, 27:1022-1029.
- Siganos CS, Kymionis GD, Astyrakakis N. *et al.* 2002. Management of corneal ectasia after laser in situ keratomileusis with INTACS. *J Refract Surg.*, 18:43–6.
- Twa MD, Nichols JJ, Joslin CE. *et al.* 2004. Characteristics of corneal ectasia after LASIK for myopia. *Cornea.*, 23:447-457.
