



CASE STUDY

A BLEEDING ANGIODYSPLASIA OF THE SMALL INTESTINE: DOES UTILIZATION OF MODERN MODALITIES CHANGES THE ROLES OF DIAGNOSIS AND MANAGEMENT?

Dan Feldman, *Amir Mari, Oren Gal, Fadi Abu Baker, Roman Depsames, Baruch Ovadia and Yael Kopelman

Gastroenterology unit Hillel Yaffe Medical Center, Affiliated to the Ruth and Rappaport Faculty of Medicine, Technion Isreal of Technology, Hadera, Israel

ARTICLE INFO

Article History:

Received 20th March, 2018
Received in revised form
19th April, 2018
Accepted 15th May, 2018
Published online 28th June, 2018

Key words:

Hemangiomas,
Capsule Endoscopy,
Argon Plasma Coagulation.

*Corresponding author

Copyright © 2018, Dan Feldman et al. This is an open access article distributed under the Creative Commons Attribution License, which permits unrestricted use, distribution, and reproduction in any medium, provided the original work is properly cited.

Citation: Dan Feldman, Amir Mari, Oren Gal, Fadi Abu Baker, Roman Depsames, Baruch Ovadia and Yael Kopelman, 2018. "A bleeding angiodysplasia of the small intestine: does utilization of modern modalities changes the roles of diagnosis and management?", *International Journal of Current Research*, 10, (06), 70113-70115.

ABSTRACT

Small intestinal bleeding accounts for 5–10% of all patients presenting with gastrointestinal bleeding (GIB). In the modern era of capsule endoscopy, Angiodysplasias of the small intestine turned out to be a major cause of "obscure GIB", particularly in the elderly. Due to the multifocal nature of Angiodysplasia, effective therapy is a challenge. Recurrence rate after endoscopic treatment ranges from 20 to nearly 50%. Additional systemic therapy options are available. A 62 years old male was presented to our institute with an acute recurrent upper GI bleeding originating from several angiodysplasia foci. Using capsule video endoscopy, followed by push enteroscopy and argon plasma coagulation temporary hemostasis was done. Due to the nature of the lesions, recurrent bleeding episodes recurred and mandated the need of systemic treatment with somatostatin.

INTRODUCTION

Small intestinal bleeding accounts for 5–10% of all causes of upper GIB (Longstreth, 1997). Capsule endoscopy and push enteroscopy have improved the ability to investigate and treat small bowel bleeding sources (Gunjan, 2014). Angiodysplasia of the small intestines is the most common cause of "obscure GIB" particularly in the elderly. It is an abnormally dilated, tortuous, thin-walled vessel, involving small capillaries, veins and arteries. Gastric and colonic angiodysplasia may be markers for small bowel angiodysplasia (Gerson *et al.*, 2015). Outcomes associated with treatment of small bowel vascular lesions as sources of bleeding have been disappointing and despite endoscopic therapy (mainly argon plasma coagulation and adrenalin injection), the recurrence rate after treatment range from 20 to 50%. Risk factors for recurrent bleeding from small bowel angiodysplasia have includes the number of vascular lesions, age over 65 years, presence of lesions in the jejunum, presence of cardiac valvular disease, chronic renal failure, usage of anticoagulant medication, and need for transfusion (Lepère, 2005). Somatostatin, another treatment option, reduces bleeding potential by the inhibition of angiogenesis, decrease in splanchnic flow, increase in vascular resistance, and improved platelet aggregation (Szilagyi, 2006).

Case presentation: 62 years old male was admitted to our institute in a clinical state of an acute upper GIB. He complained about severe weakness coincided with dark tarry stool. His medical record includes heavy smoking, primary hypertension, chronic renal failure and recent ischemic stroke for which he is treated with dual anti platelet medication (aspirin and clopidogrel). Upon initial evaluation, vital signs showed borderline blood pressure and tachycardia. Melena was observed on rectal examination. Blood count revealed normocytic normochromic anemia of 7 gram/l (a drop from baseline level of 12 gram/l two weeks earlier). The patient was resuscitated and stabilized using transfusion of packed RBCs. Clopidogrel treatment was discontinued. Urgent gastroscopy findings were mild erosive duodenitis, antral gastritis and few angiodysplasia with no signs of recent bleeding. Urease test was negative. Next, on colonoscopy small internal hemorrhoids and few non bleeding angiodysplastic lesions in the right colon were found (Figure 1). Small bowel video capsule, as the next step to investigate this case of obscure small bowel bleeding, revealed many enteric angiodysplastic lesions, mostly along the proximal to mid small bowel, with several foci of intense oozing mainly in the proximal Jejunum (Figures 2, 3). Push enteroscopy was done screening approximately up to mid jejunum.

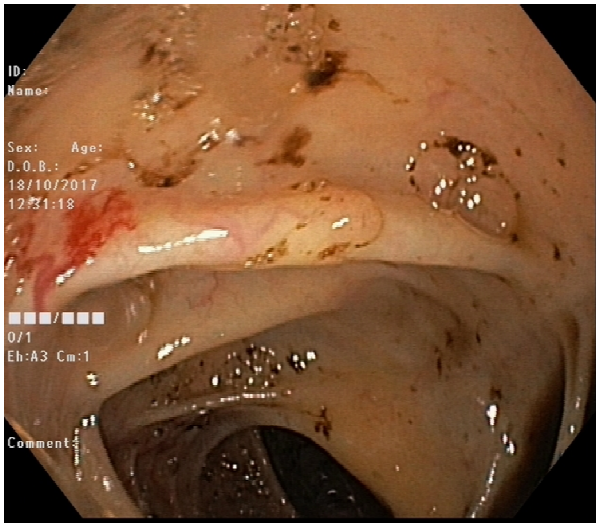


Figure 1. Angiodysplasia – right colon (colonoscopy image- Olympus)

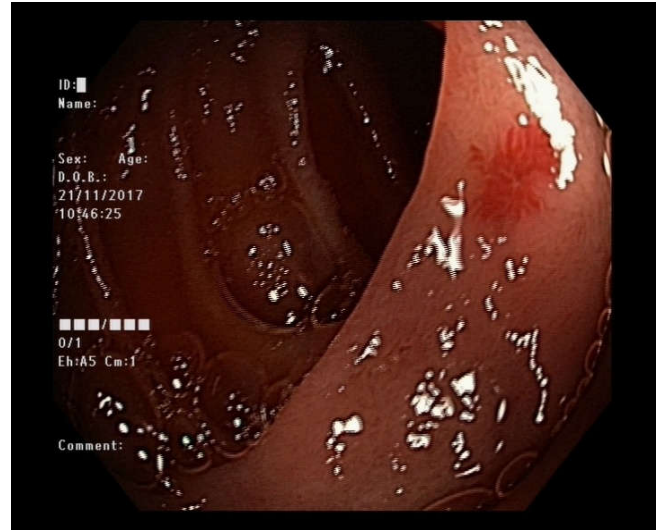


Figure 4. Angiodysplasia proximal jejunum (push enteroscopy image- Olympus)

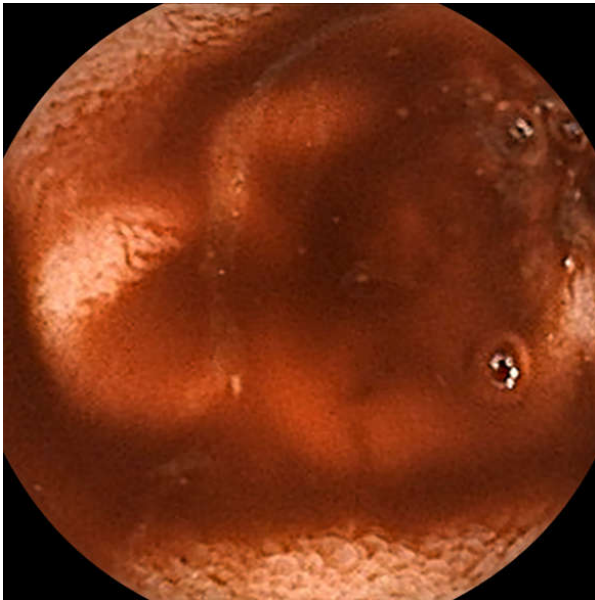
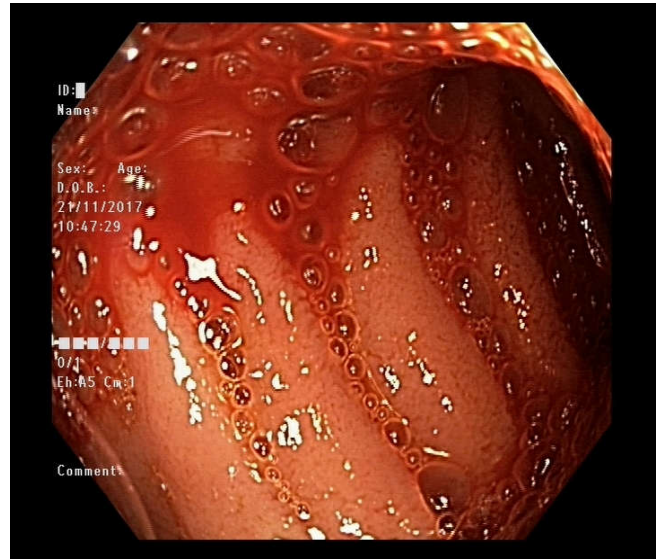


Figure 2. Angiodysplasia oozing- proximal jejunum (video capsule endoscopy image- GIVEN)



Video 1: Angiodysplasia oozing in proximal jejunum (push enteroscopy image- Olympus).

Figure 5: Angiodysplasia oozing in proximal jejunum (push enteroscopy image- Olympus)

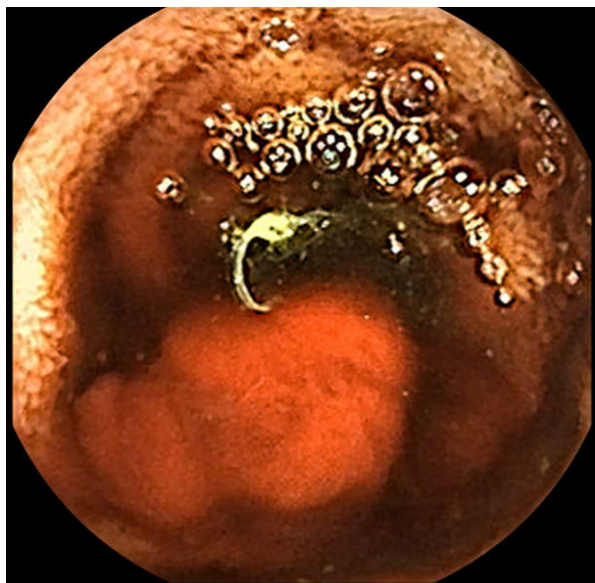


Figure 3. Angiodysplasia oozing- proximal jejunum (video capsule endoscopy image- GIVEN)

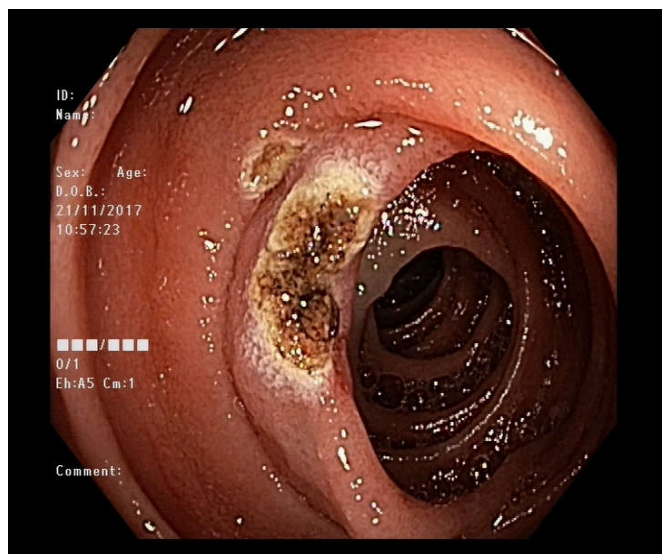


Figure 6. Angiodysplasia proximal jejunum – treated with adrenalin injection and argon plasma coagulation (push enteroscopy image- Olympus)

Consistent with the video capsule, endoscopy identified an obvious focus of active bleeding from angiodysplasia (figures 4, 5, video 1). The lesion was treated successfully with diluted adrenalin followed by argon plasma coagulation (Figure 6), the oozing stopped and patient was stabilized. Echocardiogram ruled out aortic valve stenosis. Two weeks later, the patient readmitted with recurrent upper GI bleeding. On repeated push enteroscopy, same multiple angiodysplastic lesions were observed but no source of bleeding was found, assuming that the culprit lesion is probably located more distally. Systemic treatment with somatostatin analogue was initialized with no recurrent bleeding episodes.

DISCUSSION AND CONCLUSION

Terminology shifted concerning obscure GI bleeding mainly due to the utilization of video capsule endoscopy. Angiodysplasia of the small intestines is the most common cause of “obscure GIB” particularly in the elderly. Outcomes associated with treatment (mainly in setting of multiple vascular lesions) have been disappointing with high recurrence rate. This case presents a patient with several risk factors for acute recurrent bleeding from small intestinal angiodysplastic lesion mainly dual antiplatelets use. Capsule endoscopy and argon plasma coagulation are modern tools profoundly contributed to the diagnosis and to the endoscopic treatment, however, efficacy was limited.

Conflict of interest

The authors declare no conflict of interest.

REFERENCES

- Gerson LB, Fidler JL, Cave DR, Leighton JA. 2015. ACG Clinical Guideline: Diagnosis and Management of Small Bowel Bleeding. *Am J Gastroenterol.*, 110. doi:10.1038/ajg.2015.246.
- Gunjan D, Sharma V, Rana SS, Bhasin DK. 2014. Small bowel bleeding: a comprehensive review. *Gastroenterol Rep.*, 2:262–75. doi:10.1093/gastro/gou025.
- Lepère C, Cuillerier E, Van Gossum A, Bezet A, Schmit A, Landi B, *et al.* 2005. Predictive factors of positive findings in patients explored by push enteroscopy for unexplained GI bleeding. *Gastrointest Endosc.*, 61:709–14. doi:10.1016/S0016-5107(05)00338-X.
- Longstreth GF. 1997. Epidemiology and outcome of patients hospitalized with acute lower gastrointestinal hemorrhage: a population-based study. *Am J Gastroenterol.*, 92:419–24.
- Szilagyi A, Ghali MP. 2006. Pharmacological therapy of vascular malformations of the gastrointestinal tract. *Can J Gastroenterol.*, 20:171–8.
