



ISSN: 0975-833X

Available online at <http://www.journalcra.com>

International Journal of Current Research
Vol. 10, Issue, 05, pp.69851-69853, May, 2018

INTERNATIONAL JOURNAL
OF CURRENT RESEARCH

RESEARCH ARTICLE

SUBCUTANEOUS (EXTRA PERITONEAL) CLOSURE OF VENT- COLOSTOMY, A NEW INTERVENTIONAL METHOD OF CLOSURE OF VENT- COLOSTOMY

*Luai Farhan Zghair, Jamal Khalil AL-Qaisy and Mohammed Hussein Mushrif

Faculty of medicine, AL- Iraqia University, Baghdad, Iraq

ARTICLE INFO

Article History:

Received 14th February, 2018
Received in revised form
10th March, 2018
Accepted 09th April, 2018
Published online 31st May, 2018

Key words:

Colon, Colostomy,
Extraperitoneal Closure, Vent.

ABSTRACT

A colostomy is a surgical procedure in which an opening (stoma) is formed by drawing the healthy end of the large intestine or colon through an incision in the anterior abdominal wall and suturing it into place. This opening, in conjunction with the attached stoma appliance, provides an alternative channel for feces and flatus to leave the body. It may be reversible or irreversible depending on the circumstances. Two patients were done to them right hemicolectomy with end to side ileo- transverse anastomosis with vented colostomy where done to them. Closure of vented colostomy subcutaneously where done to them. The Subcutaneous (extra peritoneal) closure of the vent- colostomy to cormorbidity patients is very save method even if fecal fistula was occurred no intraperitoneal contamination was happend because the peritoneal cavity was not opened, and no other complication were occurred.

Copyright © 2018, Luai Farhan Zghair et al. This is an open access article distributed under the Creative Commons Attribution License, which permits unrestricted use, distribution, and reproduction in any medium, provided the original work is properly cited.

Citation: Luai Farhan Zghair, Jamal Khalil AL-Qaisy and Mohammed Hussein Mushrif, 2018. "Subcutaneous (Extra peritoneal) closure of vent- colostomy, a new interventional method of closure of vent- colostomy", *International Journal of Current Research*, 10, (5), 69851-69853.

INTRODUCTION

In adults, the large bowel measures approximately 1.5 m. The caecum, ascending, transverse, descending and sigmoid colon have similar characteristic features, these are that they possess:

- **Appendices epiploicae:** these are fat-laden peritoneal tags present over the surface of the caecum and colon.
- **Teniae coli:** these are three flattened bands representing the condensed longitudinal muscular coat of the large intestine, they course from the base of the appendix (and form a useful way of locating this structure at operation) to the recto-sigmoid junction.
- **Sacculations:** because the teniae are shorter than the bowel itself the colon takes on a sacculated appearance, these sacculations are visible not only at operation but also radiographically, on a plain abdominal X ray, the colon, which appears radiotranslucent because of the gas within, has shelf-like processes (haustra) which partially project into the lumen.

The transverse and sigmoid colon are each attached to the posterior abdominal wall by their respective mesocolons and are covered entirely by peritoneum. Conversely, the ascending and descending colon normally possess no mesocolon, they are adherent to the posterior abdominal wall and covered only anteriorly by peritoneum (Omar Faiz, 2002).

*Corresponding author: Luai Farhan Zghair,
Faculty of medicine, AL- Iraqia University, Baghdad, Iraq.

The rectum occupies the posterior part of the pelvic cavity, It is continuous above with the sigmoid colon and descends in front of the sacrum to leave the pelvis by piercing the pelvic floor, here it becomes continuous with the anal canal in the perineum (Richrd Snell, 2007). The arterial supply of the large bowel are from branches of the Superior Mesenteric Artery and Inferior Mesenteric Artery. The Venous drainage are to the Portal Vein (Keith Moore, 2014). Colostomy is an artificial opening made in the large bowel to divert faeces and flatus to the exterior, where it can be collected in an external appliance, depending on the purpose for which the diversion has been necessary, a colostomy may be temporary or permanent (Gordon Carlson, 2013). The colon is the second most frequent organ injured in penetrating abdominal trauma after the small bowel (Wolff BG, 2007). Pilon, a French surgeon performed the first colostomy surgery in 1776, by bringing out the caecum onto the skin (Mc Garity, 1993). The surgical literature from the 17th century show that colostomy first arose as a result of clinical observation from spontaneous external fistula resulting from penetrating wounds to the abdomen, dismal results in general were observed with penetrating abdominal injury when spontaneous fistula did not occur (Fallon WF Jr, 1992). The treatment of colon injuries has been profoundly influenced by military experience (Wolff, 2007). During World War I, the management of colonic injuries was primary repair, but the mortality remained high, approaching 60-75% (Steele, 2011). While during World War II, the exteriorization of the injured colon or repair of colonic injury with proximal diversion were considered as the treatments of choice for colon injuries (Ogilvie, 1944, Cutler, 1945). Mortality rates decreased to 30%

at the end of World War II, this is possibly due to changes in the management of injured colon including the improved antibiotics, advances in surgical techniques and instruments, and improved evacuation times (Wolff, 2007; Cleary, 2006). Colostomy, antibiotics, fluid replacement, electrolytes monitoring and improved evacuation technique reduced the mortality rate to 12% during both the Korean and Vietnamese conflicts. However, 16-30% of patients during the war in Iraq and Afghanistan who were managed initially with primary repair or anastomosis experienced leaks, which were subsequently managed with colostomy (Vertrees, 2009, Duncan JE, 2008). The civilian trauma to the colon with small colonic wound without significant contamination can be safely treated with primary repair while patients with complex colon injuries are more appropriately treated by colostomy (Nicolas Nelken, 1989, David H-Livingston, 1989, Williams, Csepanyi, 1987). Complications associated with colostomies are both early and late; the Closure of temporary colostomies may be associated with significant complications (Wolff, 2007). The morbidity after subsequent colostomy closure varies widely; there are risk factors responsible for a high complication rate which may result from colostomy closure they found that adequate preoperative bowel preparation, secondary suture of the wound and especially delaying of colostomy closure for 2-3 months after initial procedure may be beneficial in reducing the high morbidity (Sarah Paul, 1985, Doughty, 2005). So closure of colostomy is not a minor procedure and it requires the same standards of surgical care as any anastomosis of the large intestine (Foster Leaper Williamson, 1985).

MATERIALS AND METHODS

Two patients were done to them right hemicolectomy with end to side ileo- transverse anastomosis with vented colostomy where done to them.

RESULTS

Closure of vented colostomy subcutaneously where done to them.

DISCUSSION

A colostomy is a surgical procedure in which an opening (stoma) is formed by drawing the healthy end of the large intestine or colon through an incision in the anterior abdominal wall and suturing it into place. This opening, in conjunction with the attached stoma appliance, provides an alternative channel for feces and flatus to leave the body. It may be reversible or irreversible depending on the circumstances. There are many reasons for this procedure. Some common reasons are:-

1. A section of the colon has been removed, e.g. due to colon cancer requiring a total mesorectal excision, diverticulitis, injury, etc., so that it is no longer possible for feces to exit via the anus.
2. A portion of the colon (or large intestine) has been operated upon and needs to be 'rested' until it is healed. In this case the colostomy is often temporary and is usually reversed at a later date, leaving the patient with a small scar in place of the stoma. Children undergoing surgery for extensive pelvic tumors commonly are given a colostomy in

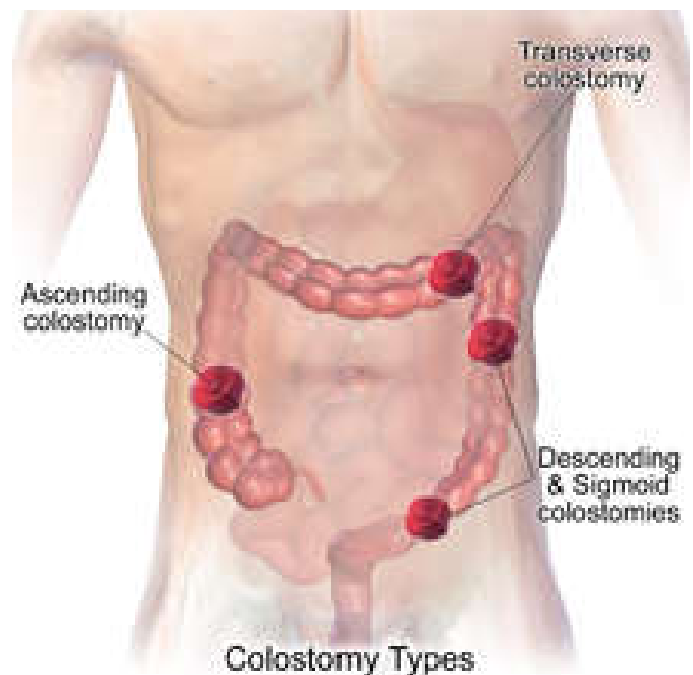
preparation for surgery to remove the tumor, followed by reversal of the colostomy.

3. Fecal incontinence that is non-responsive to other treatments. Placement of the stoma on the abdomen can occur at any location along the colon, but the most common placement is on the lower left side near the sigmoid where a majority of colon cancers occur. Other locations include the ascending, transverse, and descending sections of the colon

The types of colostomy are:-

- 1- **Loop colostomy:** This type of colostomy is usually used in emergencies and is a temporary and large stoma. A loop of the bowel is pulled out onto the abdomen and held in place with an external device. The bowel is then sutured to the abdomen and two openings are created in the one stoma: one for stool and the other for mucus.
- 2- **End colostomy:** A stoma is created from one end of the bowel. The other portion of the bowel is either removed or sewn shut (Hartmann's procedure).
- 3- **Double barrel colostomy:** The bowel is severed and both ends are brought out onto the abdomen. Only the proximal stoma is functioning.

Colostomy surgery that is planned usually has a higher rate of long-term success than surgery performed in an emergency situation (Potter et al, 2006). As showed in the Illustration below.



People with colostomies must wear an ostomy pouching system to collect intestinal waste. Ordinarily the pouch must be emptied or changed a couple of times a day depending on the frequency of activity; in general the further from the anus (i.e., the further 'up' the intestinal tract) the ostomy is located the greater the output and more frequent the need to empty or change the pouch ("Colostomy irrigation, Colostomy Guide" 2013). A pouch that can be drained is usually emptied when it is one third full, a pouch is replaced usually every 3 to 7 days or whenever the seal comes off, for which it should be replaced immediately (Taylor, 2011). In our study right hemicolectomy with end to side ileo- transverse double layers anastomosis with

transverse colon vented colostomy were done to 2 patients, were fixed in the right side of the upper abdomen, the first one is 5 years old child with terminal ileum intestinal lymphoma with intestinal obstruction with multiple mesenteric and para-aortic lymphadenopathy, and the second one is 65 years old man with caecal carcinoma with multiple mesenteric and para-aortic lymphadenopathy which suffer from hypertension and he was diabetic patient, and after completed the radio-chemotherapy of both patients after one year subcutaneous (extraperitoneal) closure of the vent- colostomy were done to them by double layers suturing, and the 65 years old man complicated by fecal fistula after 3 days of closure and closed spontaneously after 2 weeks, and no other complication were occurred.

Conclusion

Subcutaneous (extra peritoneal) closure of the vent- colostomy to cormorbidity patients is very save method even if fecal fistula was ocured no intraperitoneal contamination was happend because the peritoneal cavity was not opened, and no other complication were ocured.

REFERENCES

- "Colostomy irrigation: Colostomy Guide", United Ostomy Associations of America, Retrieved 4 February 2013.
- Cleary RK, Pomerantz RA, Lampman RM. 2006. Colon and rectal injuries. *Dis Colon Rectum*, 49: 1203–22.
- David H-Livingston, Frank B-Miller, and J-David Richardson are the risks after colostomy closure exaggerated? *Am.J. surgery*, 1989, July, 158; 17-20.
- Doughty D. Principles of ostomy management in the oncology patient. *J Support Oncol*, 2005; 3: 59.
- Duncan JE, Corwin CH, Sweeney WB, et al. 2008. Management of colorectal injuries during Operation Iraqi Freedom: patterns of stoma usage. *J Trauma*, 64: 1043–7.
- Fallon WF Jr. 1992. The present role of colostomy in management of trauma, *Dis Colon, Rectum*, 35; 1094-1102.
- Foster Leaper Williamson, changing patterns in colostomy closure the Bristol experience 1975-1982 *Br. J. Surgery*, 1985, 75 Feb: 142-145.
- Gordon Carlson, Jonathan Epstein, 2013. The small and large intestines, chapter 69, Bailey and Loves, short practice of surgery, 26th edition, CRC Press, Taylor and Francis Group, London, 1174.
- Keith L. Moore, Arthur F. Dalley, Anne M. R. Agur, the abdomen, 2014. chapter 2, Moore clinically oriented anatomy, 7th ed, Wolters Kluwer, Lippincott, Williams and Wikins, Baltimor, 246.
- Mc Garity W. 1993. Salute to ET nurses. *Journal of Enterstomal Therapy*, 19 (2): 40-41.
- Nicolas Nelken and Frank Lewis: the influence of injury severity on complication rates after primary closure or colostomy for penetrating colon trauma: *Ann surgery*, 1989. Apr.209"4": 439-47.
- Ogilvie WH. Forward Surgery in Modern War. London, UK: Butterworth; 1944. Cutler CW. Profits to peace-time practice from surgical experiences of war. *Ann Surg*. 1945; 122: 734–43.
- Omar Faiz, 2002. David Moffat, the lower gastrointestinal tract, chapter 17, Anatomy at Glance, 1st ed, Blackwell Science LTD, British, 43.
- Potter et al, Canadian Fundamentals of Nursing 3rd ed, 2006, Elsevier, Canada, 1393- 1394.
- Richrd S. Snell, 2007. The abdominal cavity, chapter 5, clinical anatomy by regions, 8th ed, Wolters Kluwer, Lippincott Williams & wikins, 204.
- Sarah Paul: complication of colostomy closure. *Am. J. Surgery*, 1985 may 109"5": 672-75.
- Steele SR, Maykel JA, Johnson EK. 2011. Traumatic injury of the colon and rectum: the evidence vs dogma. *Dis Colon Rectum*, 54, 1184–201.
- Taylor, C. R., Lillis, C., LeMone, P., Lynn, P. 2011. Fundamentals of nursing: The art and science of nursing care, Philadelphia: Lippincott Williams & Wilkins, 1327.
- Vertrees A, Wakefield M, Pickett C, et al. 2009. Outcomes of primary repair and primary anastomosis in war-related colon injuries. *J Trauma*, 66: 1286–93.
- Williams, Csepanyi, Hiatt, Wilson: Analysis of Morbidity, and cost of colostomy closure in traumatic compared with non traumatic colorectal diseases. *Dis. Colon, rectum* 1987, Mar. 30"3": 164-7.
- Wolff BG, Pemberton JH, Wexner SD, Fleshman JW. 2007. The ASCRS Textbook of Colon and Rectal Surgery. New York: Springer, 322–34.
