



RESEARCH ARTICLE

A RARE CASE OF COTYLEDONOID DISSECTING LEIOMYOMA OF THE UTERUS IN
A PREGNANT LADY- A CASE REPORT

¹Dr. Ashley Ann Varughese, ^{2,*}Dr. Alfy Ann George and ³Dr. Elizabeth K. Abraham

¹Assistant Professor, Department of Pathology, SUT Academy of Medical Sciences, Trivandrum

²Assistant Professor, Department of Pathology, Travancore Medical College, Kollam

³Professor, Department of Pathology, Travancore Medical College, Kollam

ARTICLE INFO

Article History:

Received 20th March, 2018

Received in revised form

28th April, 2018

Accepted 18th May, 2018

Published online 30th June, 2018

Key words:

Cotyledonoid,
Leiomyoma,
Pregnant, Caesarian,
Uterine, Benign.

ABSTRACT

Cotyledonoid dissecting leiomyoma of uterus is an unusual variant of uterine leiomyoma that presents with an alarming gross appearance. We report a case of cotyledonoid dissecting leiomyoma in a 36 year old, 35 weeks pregnant lady who presented with lower abdominal pain. On caesarian section, two fungating polypoidal masses (mistaken for placental tissue), arising from the anterior and anterolateral surfaces of uterus, were excised. Macroscopy revealed multiple bulbous congested nodules connected by fibrous tissue. Microscopy showed benign smooth muscle cells arranged as micronodules with prominent perinodular hydropic degeneration and rich vasculature. There was no cellular atypia, increased mitosis or necrosis. It is important to recognize this rare variant of leiomyoma to prevent overtreatment.

Copyright © 2018, Ashley Ann Varughese et al. This is an open access article distributed under the Creative Commons Attribution License, which permits unrestricted use, distribution, and reproduction in any medium, provided the original work is properly cited.

Citation: Dr. Ashley Ann Varughese, Dr. Alfy Ann George and Dr. Elizabeth K. Abraham. 2018. "A rare case of cotyledonoid dissecting leiomyoma of the uterus in a pregnant lady- A case report", *International Journal of Current Research*, 10, (06), 70644-70646.

INTRODUCTION

Leiomyomas of the uterus are the most common benign smooth muscle tumours that exhibit a wide variety of variants. One rare variant of uterine leiomyoma which is histologically benign and grossly resembles 'placental cotyledons' is called cotyledonoid leiomyoma. (Roth et al., 1996) An accurate diagnosis of cotyledonoid leiomyoma is difficult before surgery due to its exophytic growth with resemblance to placental tissue or uterine sarcoma. (Aggarwal et al., 2011; Cheuk et al., 2002; Rocha et al., 2018) Majority of the patients are diagnosed during surgery, many requiring frozen section examination. (Blake et al., 2015; Xu et al., 2016; Kim et al., 2002) This report describes a case of cotyledonoid dissecting leiomyoma in a pregnant lady along with its gross and microscopic findings.

CASE REPORT

A 36 year old lady who was 35 weeks and 5 days pregnant- gravid 5, parity 2, live births 2, abortions 2, presented with

complaints of lower abdominal pain. The patient was on regular antenatal checkups. She had previous two caesarian sections. All her routine investigations showed no abnormalities. The patient was taken up for caesarian section. A preterm baby was delivered. The placenta and membranes were retrieved completely. Peroperatively the surgeon noticed two fungating polypoidal masses arising from the anterior surface of body of uterus towards the fundal aspect measuring 6 X 5 cm and the other in the anterolateral surface near the round ligament measuring 3 X 3 cm. Both masses (mistaken for placental tissue) were excised. The specimen received for histopathological examination consisted of multiple pieces of bulbous nodules that were congested, rubbery and solid, aggregate measuring 7 X 4 X 0.6cm. Nodules were connected by thin strands of fibrous tissue. Microscopically, the tumour consisted of many micronodules of benign smooth muscle cells with prominent perinodular hydropic degeneration. The bland smooth muscle cells within the nodules were arranged in interlacing fascicles with no cellular atypia, increase in mitosis or necrosis. The intervening stroma was edematous with rich vasculature. The patient was discharged from the hospital without complications 5 days following surgery. Her postoperative period was uneventful. There is no evidence of recurrence for the past two years of follow up.

*Corresponding author: Dr. Alfy Ann George
Assistant Professor, Department of Pathology, Travancore Medical College, Kollam.



Figure 1. Gross specimen shows pieces of dark brown nodules connected by fibrous strands

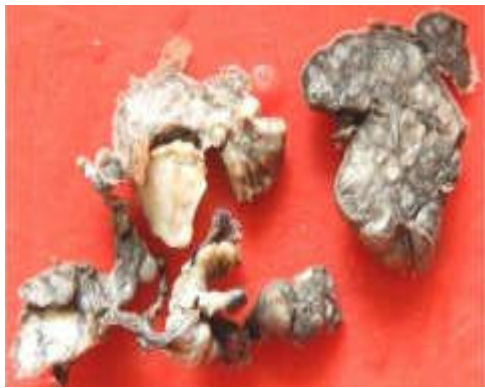

Figure 2. Cut section of the dark brown nodules

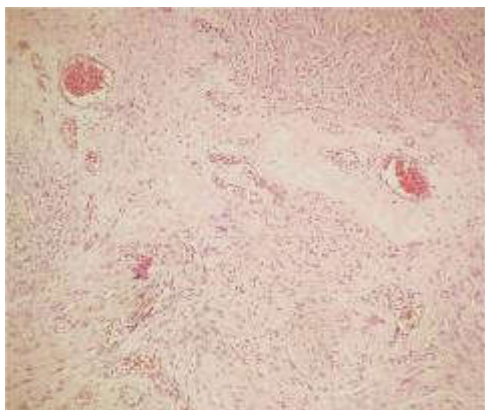
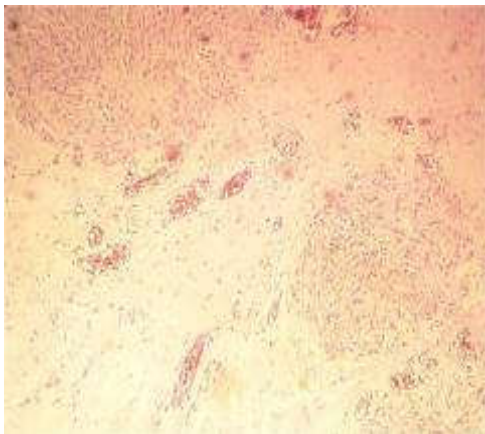


Figure 3 and 4. Nodules of smooth muscle fascicles with prominent perinodular hydropic change and rich vasculature (H&E stain, 10X)

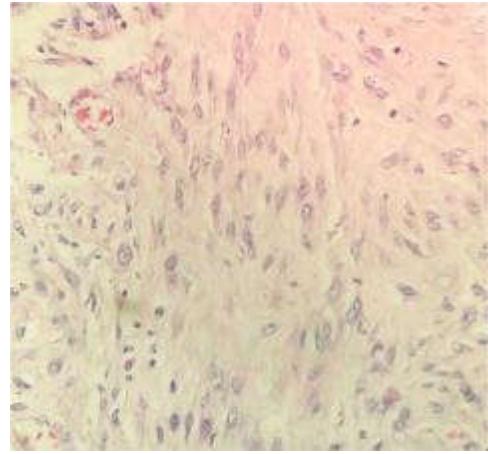


Figure 5. spindle shaped tumour cells without significant atypia, mitosis or necrosis (H&E stain, 40X)

DISCUSSION

This unusual variant of leiomyoma is also known as ‘Sternberg tumour’ after Dr William H Sternberg who first studied this tumour as ‘a red seaweed lesion’ (Sternberg *et al.*, 1979). This tumour was first described and reported by Roth *et al.* in 1996. This rare type of leiomyoma with dissecting growth within myometrium and extrauterine extension was introduced to the WHO classification of Tumours of the Female Reproductive Organs in 2003. (Tavassoli and Devilee, 2003) Less than 50 cases of cotyledonoid leiomyomas are reported in the English literature and our case is unique as it was incidentally detected during caesarian section. These tumours are commonly seen in the reproductive age group. (Roth *et al.*, 1996) The tumour arises in the lateral aspect of subserosal uterine myometrium and extends into the broad ligament and pelvic cavity. This tumour has two growth patterns: an exophytic component with spongy bulbous protuberances, congested over uterine surface resembling placenta and an intramural component with an irregular dissecting pattern of growth between the fascicles of myometrium (Weissferdt *et al.*, 2007). Roth et al described a case of cotyledonoid leiomyoma without intrauterine component and they described it to be different from cotyledonoid dissecting leiomyoma (Roth *et al.*, 2000). Kim et al warrants that it is mandatory to combine the two terms under a single lesion named as cotyledonoid dissecting leiomyoma (Kim *et al.*, 2002). Another similar tumour showing features of cotyledonoid dissecting leiomyoma with intravenous luminal growth is termed as cotyledonoid intravenous hydropic leiomyomatosis (Jordan *et al.*, 2002; Shelekhova *et al.*, 2007). The alarming gross appearance is often mistaken for placental tissue or malignant uterine lesion, which may result in inappropriate treatment. For patients in the reproductive age group who may want to preserve their fertility, myomectomy is the treatment of choice. (Saeki *et al.*, 2015; Buckshee *et al.*, 2017) There is a report of myomectomy done in a 14 weeks pregnant lady and pregnancy continued to term (Mathew *et al.*, 2007). In post menopausal women, total abdominal hysterectomy and bilateral salphingo-oophorectomy is the best choice. (Xu *et al.*, 2016) Histologically these tumours are bland looking leiomyomas with no evidence of atypia or increase in mitosis. Areas of edema and perinodular hydropic degeneration are noted in these tumours. This tumour is also highly vascularised. It has a benign course. Immunohistochemistry and ultrastructural studies are not useful in diagnosis of this

tumour. (Kim *et al.*, 2002; Menolascino-Brrata *et al.*, 1999) But these techniques will confirm the smooth muscle origin of the tumour. Recurrences are rare with only one documented case following conservative treatment which must have been regrowth from incomplete excision of the tumour.(Smith *et al.*2012; Roth *et al.*, 2013)

Conclusion

This case represents an extremely rare variant of leiomyoma with an aggressive gross appearance and a benign nature. Hence awareness of this entity amongst pathologists and surgeons is of paramount importance to avoid overtreatment.

Conflicts of Interest: Authors declare that they have no conflicts of interest.

Funding Agency: No subsidies or grants contributed to this work.

REFERENCES

- Aggarwal, S., Arora, V.K. 2011. An unusual variant of leiomyoma masquerading preoperatively as sarcoma.*Indian J Cancer*, 48:120-1
- Blake, E.A., Cheng, G., Post, M.D., Guntupalli, S. 2015. Cotyledonoid dissecting leiomyoma with adipocytic differentiation: A case report. *Gynaecol Oncol Rep*,11:7-9
- Buckshee, K., Harsh, R., Deepshikha, A., Tanya, R.B. 2017. A bizarre highly vascular tumour with alarming presentation: a diagnostic dilemma. *Int J Reprod Contracept Obstet Gynecol*, 6(12):5621-5624.
- Cheuk,W., Chan, J.K.C., Liu, J.Y.S. 2002. Cotyledonoid leiomyoma: a benign tumour with alarming gross appearance. *Arch Pathol Lab Med*,126:210-3
- Jordan, L.B., Al-Nafussi, A., Beattie, G. 2002. Cotyledonoid hydropic intravenous leiomyomatosis: a new variant leiomyoma. *Histopathology*, 40(3); 245-52.
- Kim, M.J., Park, Y.K., Cho, J. 2002. Cotyledonoid dissecting leiomyoma of the uterus: a case report and review of the literature.*J Korean Med Sci.*, 17:840-4
- Mathew, M., Gowri, V., Al Hamdani, Machado, L., Rao, K. *et al.* 2007. Cotyledonoid leiomyoma in pregnancy. *Obstet Gynaecol* ,109(suppl):509-511.
- Menolascino-Brrata, F., Garcia, de Barriola, V., Navajo, de Gomez *et al.* 1999. Cotyledonoid dissecting leiomyoma (Sternberg tumour): an unusual form of leiomyoma. *Pathol Res Pract* ,195:435-8
- Rocha, A.N., Oliveira, M., Luis, P., Nogueira, M. 2018. Cotyledonoid Dissecting Leiomyoma of the uterus: An unexpected diagnosis after delivery *Acta Med Port* ,31(4):223-227
- Roth, L.M., Kirker, J.A., Insull, M. *et al.* 2013. Recurrent cotyledonoid dissecting leiomyoma of the uterus. *Int J Gynaecol Pathol*, 32(2):215-20
- Roth, L.M., Reed, R.J. 2000. Dissecting leiomyomas of the uterus other than cotyledonoid dissecting leiomyoma: a report of eight cases. *Am J Surg Pathol.*, 1032-39
- Roth, L.M., Reed, R.J., Sternberg, W.H.1996. Cotyledonoid dissecting leiomyoma of the uterus. The Sternberg tumour. *Am J Surg Pathol*, Dec, 20(12):1455-61.
- Saeki, H., Suzuki, C.,Yamasaki, S., Hashizume, A., Izumi, H., *et al.* 2015. Cotyledonoid dissecting leiomyoma of the uterus: Report of two cases. *Arch Gynaecol Obstet*, 291:357-361.
- Shelekhova, K.V., Kazakov, D.V., Michal, M. 2007. Cotyledonoid dissecting leiomyoma of the uterus with intravascular growth: report of two cases. *Virchows Archiv*, 450(1): 119-21
- Smith, C.C., Gold, M.A., Wile, G., Fadare, O. 2012. Cotyledonoid dissecting leiomyoma of the uterus: a review of clinical, pathological and radiological features.*Int J Surg Pathol*, 20(4):330-41.
- Sternberg, W.H. Proliferating pelvic angioleiomyomatosis (red seaweed lesion) 1979. In Proceedings of the 9th George Papanicolou Memorial. Seminar in Gynaecological Pathology, Las Vegas, NV.
- Tavassoli, F. and Devilee, P. 2003. World Health Organization Classification of tumours of the Breast and Female genital Organs. IARC Press,Lyon, p241.
- Weissferdt, A., Maheshwari, M.B., Downey, G.P., Rollason, T.P., Ganesan, R. 2007. Cotyledonoid dissecting leiomyoma of the uterus:a case report.*Diagnostic Pathology*, 2:18.
- Xu, T., Wu, S., Yang, R., Zhao, L., Sui, M. *et al.* 2016. Cotyledonoid dissecting leiomyoma of the uterus: A report of four cases and review of literature. *Oncol Lett*, 11: 2865-68.
