



RESEARCH ARTICLE

BUCCOLINGUAL ROOT DILACERATIONS DEPICTED IN RADIOVISIOGRAPHY
(RVG) – AN IN VITRO STUDY

*Dr. Shweta Varma, Dr. Ajay Bhoosreddy, Dr. Sonal Patil, Dr. Kalyani Vaijwade
and Dr. Mala Jaisinghani

Dept. of Oral Medicine and Radiology, MGV KBH'S Dental College, Nashik, Maharashtra, India

ARTICLE INFO

Article History:

Received 09th April, 2018
Received in revised form
05th May, 2018
Accepted 12th June, 2018
Published online 31st July, 2018

Key words:

Dental Radiovisioigraphy,
Root Dilaceration,
2D radiograph, 3D radiograph.

ABSTRACT

Purpose: The purpose of the present study was to see the appearance of buccolingual dilacerations of the root on RadioVisioGraphy.

Material and Methods: 50 buccolingually dilacerated extracted teeth were collected and graded based on the degree of severity of root curvature. They were then mounted on wax and examined on RVG. These RVG images were then categorized into five types as per Young Ho Kim et al.

Objectives:

- I. To group the extracted dilacerated tooth based on the degree of severity of root curvature.
- II. To categorize the RVG views based on the degree of severity of root curvature:
 1. Indistinct type
 2. Clear blunt on the root tip
 3. Stepping on root tip
 4. Bull's eye
 5. Normal type

Results: Of all the teeth 1st molars were more common buccolingually dilacerated teeth followed by premolars, 3rd molars, 2nd molars and canine. As the degree of severity of root curvature increases, the blunt type and the stepping type were more commonly observed on RVG.

Conclusions: Within the scope of our study we can conclude that although 3D imaging has been used as diagnostic confirmatory test for buccolingual root dilaceration 2D imaging can be used as diagnostic screening test.

Copyright © 2018, Dr. Shweta Varma, et al. This is an open access article distributed under the Creative Commons Attribution License, which permits unrestricted use, distribution, and reproduction in any medium, provided the original work is properly cited.

Citation: Dr. Shweta Varma, Dr. Ajay Bhoosreddy, Dr. Sonal Patil, Dr. Kalyani Vaijwade and Dr. Mala Jaisinghani. 2018. "Buccolingual root dilacerations depicted in radiovisioigraphy (RVG) – An in vitro study", *International Journal of Current Research*, 10, (07), 71883-71887.

INTRODUCTION

The term *dilaceration* was first used by Tomes (Tomes, 1846-1848) in 1848 and is defined as an acute deviation of the long axis of the tooth, located to the crown or the root portion and originating from a traumatic nonaxial displacement of already formed hard tissue in relation to the developing soft tissue (Andreasen, 1972). The criteria for recognizing root dilaceration vary in the literature, some authors, consider to have a dilaceration toward the mesial or distal direction if there is a 90-degree angle or greater along the axis of the tooth or root, whereas others defined dilaceration as a deviation from the normal axis of the tooth of 20 degrees or more in the apical part of the root (Hamasha, 2002). Dilacerations were reported to account for 3% of "injuries" to developing teeth (Andreasen, 1972).

*Corresponding author: Dr. Shweta Varma,

Dept. of Oral Medicine and Radiology, MGV KBH'S Dental College,
Nashik, Maharashtra, India

DOI: <https://doi.org/10.24941/ijcr.31427.07.2018>

There are two possible causes of dilacerations out of which the most widely accepted cause is the mechanical trauma to the primary predecessor tooth, which results in dilaceration of the developing succedaneous permanent tooth. The calcified portion of the permanent tooth germ is displaced in a way that the remaining permanent tooth germ forms at an angle to it (Kilpatrick, 1991). Other possible contributing factors that have been reported include scar formation, developmental anomaly of the primary tooth germ, facial clefting, advanced root canal infections, ectopic development of the tooth germ and lack of space, the presence of an adjacent cyst, tumor, or odontogenic hamartoma (for example, odontoma and supernumerary tooth), the effect of anatomic structures (for example, the cortical bone of the maxillary sinus, the mandibular canal, or the nasal fossa, which might deflect the epithelial diaphragm), mechanical interference with eruption (for example, from an ankylosed primary tooth that does not resorb), tooth transplantation, extraction of primary teeth, and hereditary factors (Jafarzadeh, 2007). Dilaceration can be seen in both the dentition i.e. permanent and deciduous with the frequency in permanent

dentition to be highest (Bimstein, 1978). There is no sex predilection for occurrence of dilaceration (Eversole, 2002). Various literatures have reported that the prevalence is greater in posterior teeth and in the maxilla with fewer occurrences among anterior teeth and in the mandible (Andreasen, 1972). Crown dilacerations are less common than root dilacerations (Asokan, 2004). These root dilacerations can occur in two planes i.e. in the mesiodistal plane or the buccolingual plane. So when the dilaceration occurs in mesiodistal plane, the two dimensional (2D) radiographs can easily identify this dilacerations but when it occurs in the buccolingual directions, they are easily missed out. Direct digital radiography (DDR) is an imaging system that uses an intraoral sensor instead of a film. There are two types of intraoral sensors out of which the most common type, containing a charge-coupled device, is seen in the RadioVisioGraphy (RVG) system. Dr. Francis Mouyen invented the first RVG system that was introduced to the international market in 1987 and was approved by the Food and Drug Administration in 1989 (Nelvig, 1992). Studies done by Horner et al (Homer, 1990), concluded the minimal inherent distortion of the RVG image was a distinct advantage over Conventional film. Taking into consideration the advantages of RVG, the present study was conducted to see whether there exists any pattern on 2D radiographs for the buccolingual root dilacerations. Various other studies have been performed to visualize the buccolingual root dilacerations on 3D radiographs but the present one is one of a kind study wherein this dilaceration was visualized on a 2D radiograph. Within the search of literature, this is the only study wherein RVG have been used to visualize the buccolingual root dilaceration. So the aim of the present study was to visualize the buccolingually dilacerated extracted tooth root on Radiovisio-graphy (RVG).

MATERIALS AND METHODS

This in-vitro study was conducted at the Department of Oral Medicine and Radiology, from May 2017 to August 2017. A total of 50 buccolingually dilacerated extracted teeth were collected from the oral surgery department. SUNI Medical Imaging Inc, Digital Radiography System unit (Fig 1) was used to visualize the dilacerations. The curvature of the teeth was measured (Fig 2). The tooth was placed on the plane surface wherein the dilaceration was facing the upper surface. A line was drawn along the long axis of the tooth root and another line was drawn at the beginning of the curvature of the root. A protractor was then used to measure the angle between the intersections of these two lines. The teeth were then classified based on the degree of severity of root curvature. Various authors have suggested that the dilaceration is considered when the root is bent up to 20 degrees. So we have tried to classify these dilacerated roots into following three groups (Fig 3):

- Group I: < 20 degrees of curvature
- Group II: 20 – 40 degrees of curvature
- Group III: > 40 degrees of curvature

These teeth were then mounted on modeling wax and a RVG image was obtained (Fig 4). This image was classified based on Young Ho Kim et al classification [Young Ho Kim, 2010] into following five types (Fig 5):

- Type 1: Indistinct type (Figure 5.1)
- Type 2: Blunt type (Figure 5.2)
- Type 3: Stepping type (Figure 5.3)
- Type 4: Bull's eye type

Type 5: Normal type (Figure 5.4)

Three specialized oral and maxillofacial radiologists separately evaluated the RVG images. All the obtained data was collected, tabulated and entered in MS excel.

RESULTS

Of all the teeth 54% were molars followed by 36 % premolars and 10 % canines. Of these 28% teeth were 3rd molars followed by 2nd and 1st premolar (18%) followed by 1st molar (16%) with the least occurrence in 2nd molar and canine (10%). The dilaceration was seen in 22 out of 50 (44%) of Group III followed by 16 out of 50 (32%) in Group II followed by 12 out of 50 (24%) in Group I [Table1 / Chart 1].

Table 1. Percentage of extracted teeth based on degree of severity of root curvature

	Group I	Group II	Group III
Number of teeth	12	16	22
Percentage	24%	32%	44%
Total	50		

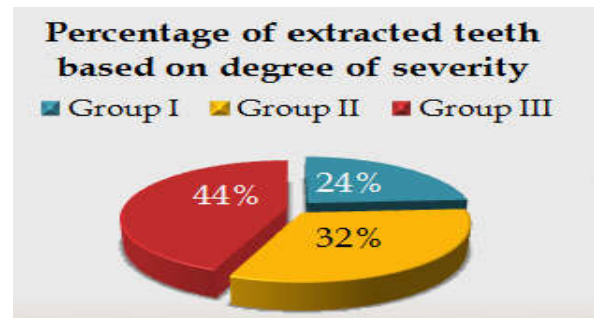


Chart 1. Percentage of extracted teeth based on degree of severity of root curvature

Table 2. RVG views based on degree of severity of root curvature

	Group 1	Group 2	Group 3
Type 1	8	2	0
Type 2	1	0	12
Type 3	0	3	10
Type 4	0	0	0
Type 5	3	11	0
Total	12	16	22

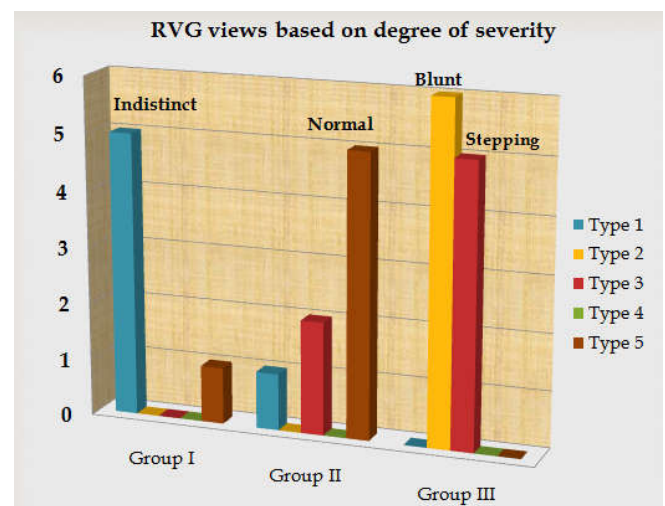


Chart 2. RVG views based on degree of severity of root curvature

The results showed that in Group I the most commonly seen RVG view was Type 1 followed by Type 5, in Group II it was Type 5 followed by Type 3 followed by Type 1 whereas in Group III it was Type 2 followed by Type 3 [Table2 / Chart 2].



Fig. 1. RVG unit used for taking the radiograph

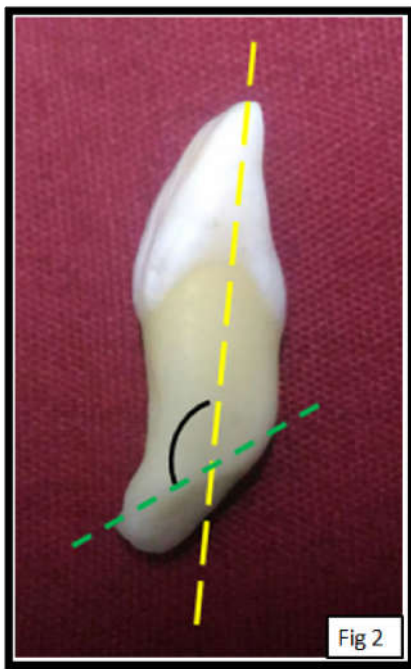


Fig. 2. Measuring the curvature of the dilacerated root

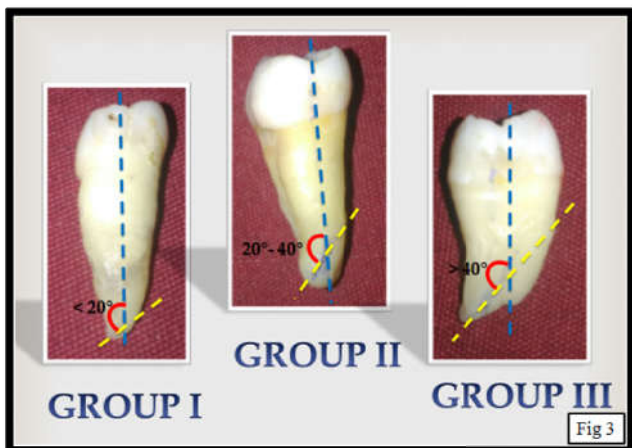


Fig. 3. Classifying the dilacerated root based on degree of curvature

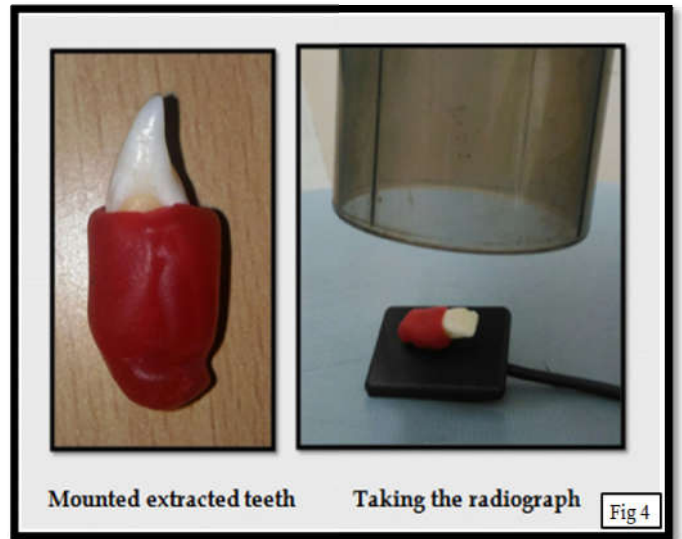


Fig. 4. Mounting the extracted teeth and taking the radiograph

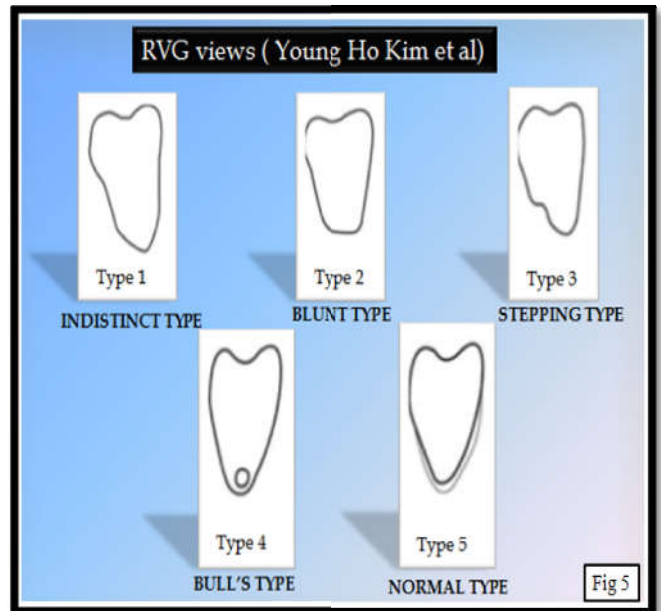


Fig. 5. Classifying the RVG views based on Young Ho Kim et al classification

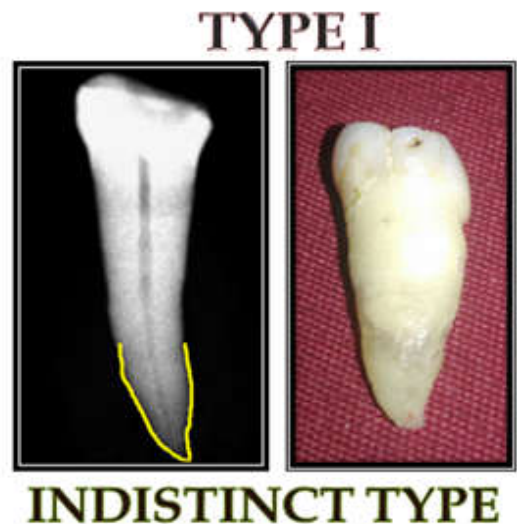


Fig. 5.1. Indistinct Type

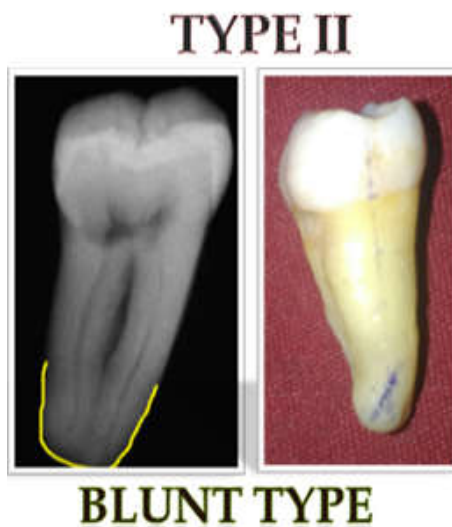

Fig 5.2. Blunt Type

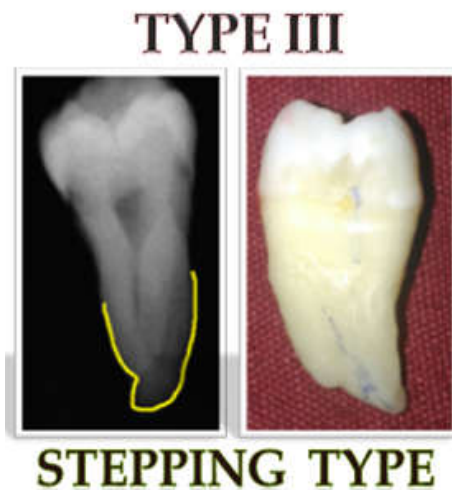

Fig. 5.3. Stepping type

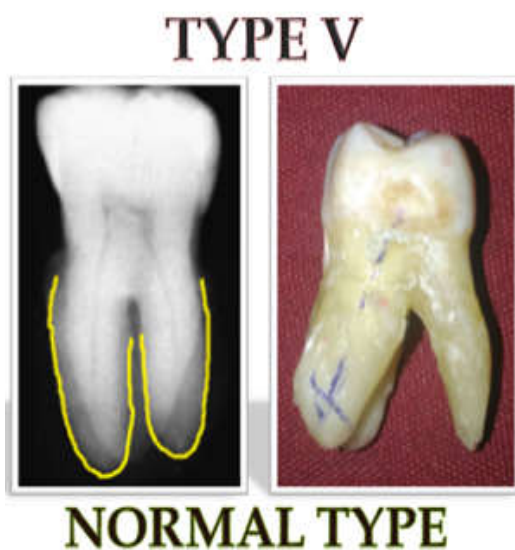

Fig 5.4. Normal Type

The presence of a dilaceration must be identified before treatment, and this can be achieved by a thorough clinical and radiographic examination. The most appropriate method for evaluating unextracted teeth for root dilaceration is radiographic examination (White, 2000). Diagnosing root

dilaceration before endodontic treatment is an important objective in gaining control as endodontic instruments to curves in root canals. A frequent error in endodontic procedure is the failure to maintain root canal curvature, resulting in ledging, apical cavitation (transport and zipping), perforation, and instrument breakage (Walton, 1996). The teeth showing the highest prevalence of root dilaceration is 3rd molars followed by premolars, 1st molar with the least occurrence in 2nd molars & canine which is in accordance to the study done by Malcic et al [15] wherein the mandibular 3rd molars (24.1%) were the most commonly dilacerated teeth, followed by maxillary first molars (15.3%), second molars (11.4%), and third molars (8.1%). In one of the study done by Hamasha et al (Hamasha, 2002), showed that dilaceration was highest in lower third molars (19.2%), lower first molars (5.6%), and upper second premolars (4.7%) which are in contradictory to the present study. Based on the degree of severity of root curvature Group I i.e. less than 20 degrees showed the indistinct type of RVG, Group II i.e. between 20 to 40 degrees showed the normal type followed by the stepping type of RVG view whereas Group III i.e. greater than 40 degrees showed blunt type of RVG view followed by the stepping type. The present study showed that the more the curvature the more the appearance of blunt and stepping type on the 2D radiograph which is in accordance with the study done by Young Ho Kim et al (Young Ho Kim, 2010), where he included 48 buccolingually dilacerated teeth and compared their appearance on panoramic and CT scan. We also found that less than 20 degrees showed indistinct type of RVG view whereas more than 40 degrees showed clear blunt and stepping type of radiographic appearance.

Conclusions

The present study showed that the more the curvature the more the appearance of blunt and stepping type on the 2D radiograph. This finding can be helpful for the clinicians as well as practitioners to have an early access for the visualization of buccolingually dilacerated tooth to avoid any mishap. So, within the scope of our study we concluded that although 3D imaging has been used as diagnostic confirmatory test for visualizing buccolingual root dilaceration 2D imaging can be used as diagnostic screening test.

Acknowledgments and Disclosure Statements

The authors report no conflicts of interest related to this study.

REFERENCES

- Andreasen JO. Traumatic Injuries to the Teeth. 2nd ed. St Louis: Mosby; 1972. p. 273-320.
- Andreasen, J.O.: Traumatic Injuries of the Teeth, ed. I, Copenhagen, 1972, E. Munksgaard, p. 266.
- Asokan S, Rayen R, Muthu MS, Sivakumar N. 2004. Crown dilaceration of maxillary right permanent central incisor: a case report. *J Indian Soc Pedod Prev Dent*, 22:197-200.
- Bimstein E. 1978. Root dilaceration and stunting in two unerupted primary incisors. *ASDC J Dent Child*, 45:223-5.
- Eversole LR. Clinical outline of oral pathology: diagnosis and treatment. 3rd ed. Hamilton, Ontario, Canada: BC Decker Inc, 2002:350.
- Hamasha AA, Al-Khateeb T, Darwazeh A. 2002. Prevalence of dilaceration in Jordanian adults. *Int Endod J*, 35: 910-2.
- Hamasha, AA, Al-Khateeb, T., Darwazeh, A. 2002. Prevalence of dilaceration in Jordanian adults. *Int Endod J*, 35:910 -2.

- Homer K, Shearer AC, Walker A, Wilson NHF. 1999. Radiovisiography: an initial evaluation. *Br Dent J* 168:244-8.
- Jafarzadeh and Abbott Dilaceration: Review of an Endodontic Challenge *JOE* — Volume 33, Number 9, September 2007
- Kilpatrick NM, Hardman PJ, Welbury RR. 1991. Dilaceration of a primary tooth. *Int J Paediatr Dent* 1:151-3.
- Malcic A, JuKic S, Brzovic V, Miletic I, Pelivan I, Anic I. Prevalence of root dilaceration in adult dental patients in Croatia. *Oral Surg Oral Med Oral Pathol Oral Radiol Endod*, 102 : 104-9.
- Nelvig P, Wing K, Welander U. 1992. Secs-A-Ray: a new system for direct digital intraoral radiography. *Oral Surg Oral Med Oral Pathol.*, 74:818-23.
- Tomes J. A course of lectures on dental physiology and surgery (lectures I-XV). London: 1846 –1848
- Walton RE, Torabinejad M. 1996. Principles and Practice of Endodontics. 2nd ed. Philadelphia: WB Saunders; p. 330-2.
- White S, Pharoah M. 2000. Oral Radiology Principles and Interpretation. 4th ed. St. Louis: Mosby; 2000. p. 313-4
- Young-Ho Kim, Hwan-Seok Jeong, Kyung-Hoe Huh, Won-Jin Yi, Min-Suk Heo, Sam-Sun Lee. 2010. A study of the panoramic radiographic images of the buccolingual dilaceration. *Korean J Oral Maxillofac Radiol.*, 40: 39-44.
