



RESEARCH ARTICLE

A CONE BEAM COMPUTED TOMOGRAPHIC STUDY OF PNEUMATIZATION OF ARTICULAR
EMINENCE AND ROOF OF GLENOID FOSSA: IT'S PREVALENCE AND CHARACTERISTICS

*Dr. Vaijwade Kalyani, A., Dr. Bhadage Chetan, J., Dr. Bhoosreddy Ajay, R.,
Dr. Jaisinghani Mala, R. and Dr. Varma Shweta, S.

Department of Oral Medicine and Radiology MGV's KBH dental College, Nasik, Maharashtra, India

ARTICLE INFO

Article History:

Received 08th May, 2018
Received in revised form
19th June, 2018
Accepted 30th July, 2018
Published online 30th August, 2018

Key Words:

Articular eminence,
Cone beam computed tomography
Glenoid fossa,
Pneumatization,

ABSTRACT

Introduction: It is very important to detect pneumatization that is air filled cavities adjacent to temporomandibular joint as they represent sites of minimal resistance and help in spread of pathologies into the joints like inflammation, tumour, fracture and also complicated factor in TMJ surgery. To prevent surgical complications, the diagnosis of these air cells is important.

Aim: To assess the prevalences and characteristics of pneumatized articular eminence and pneumatized roof of glenoid fossa using cone beam computed tomography (CBCT).

Materials and methods: CBCT scans of patient was evaluated to detect frequency of pneumatization at articular eminence and roof of glenoid fossa. Age and gender was recorded for all patients. Certain characteristics (type, lateral spread etc.) were studied for all the selected joints.

Results: Of the 200 regions, 12 (6%) presented with PAT and 56 (28%) with PRGF. Unilateral PAT and PRGF were found in 9(75%) and 23 (41.07%) patients, respectively. PAT prevalence was 33.33% in females and 66.66% in males and out of 200 regions, 66 % had grade 0 pneumatization, 24 % had grade 1, 6 % had grade 2, and 4 % had grade 3.

Conclusion: CBCT images are accurate and reliable means to detect the exact size and type of pneumatization and their relationship to adjacent tissues. Detection of pneumatization is necessary before a surgical intervention is planned, in order to prevent complications.

Copyright © 2018, Vaijwade Kalyani et al. This is an open access article distributed under the Creative Commons Attribution License, which permits unrestricted use, distribution, and reproduction in any medium, provided the original work is properly cited.

Citation: Dr. Vaijwade Kalyani, A., Dr. Bhadage Chetan, J., Dr. Bhoosreddy Ajay, R., Dr. Jaisinghani Mala, R. and Dr. Varma Shweta S., 2018. "A cone beam computed tomographic study of pneumatization of articular eminence and roof of glenoid fossa: It's prevalence and characteristics", *International Journal of Current Research*, 10, (07), xxxxxxxxxx.

INTRODUCTION

Pneumatizations are development of air filled cavities that are more commonly found in the skull. Ten sites of air cells can be found within the temporal bone. When they exist in the zygomatic process of the temporal bone, they are known as the pneumatized articular eminence (PAT) and when they exist in the roof of the glenoid fossa they are called as pneumatized roof of glenoid fossa (PRGF) (Ladeira et al., 2013; Ilguy et al., 2015). PAT is also called Zygomatic Air Cell Defects (ZACDs) (Carter et al., 1999). The term PAT given by Tyndall and Matteson (Tyndall and Matteson, 1985). It is important to detect pneumatization (air filled cavities) adjacent to temporomandibular joint (TMJ) as they represent sites of minimal resistance and facilitate the spread of various pathologies into the joint which causes inflammation, tumour or fractures.

Tumours of the mastoid process and ear otitis or mastoiditis may involve the TMJ and can result in ankylosis (Tyndall and Matteson, 1985). In addition, pneumatization should be considered as a complicating factor in patients needing surgical procedure of articular tubercle because of higher chances of perforation (Ladeira et al., 2013; Hasnaini and Ng, 2000; Miloglu et al., 2011). Previously, panoramic radiographs were taken during routine examination, which were commonly used for evaluation of these defects (Carter et al., 1999; Orhan et al., 2005). But because of anatomic complexity of TMJ, conventional techniques are inadequate for TMJ examinations. Al-Faleh and Ibrahim (Al-Faleh and Ibrahim, 2005) conducted a conventional tomographic study, in which they used a grading system from 0 to 3, where grade 0 was defined as pneumatization limited to the mastoid process, grade 1 as pneumatization between the mastoid process and the glenoid fossa, grade 2 as pneumatization between the deepest point of the glenoid fossa and the tip of the articular eminence, and grade 3 as pneumatization extending beyond the crest of the articular eminence. Carter et al. (1999) has given a classification of these structures based on panoramic

*Corresponding author: Dr. Vaijwade Kalyani, A.,
Department of Oral Medicine and Radiology MGV's KBH dental College,
Nasik, Maharashtra, India.
DOI: <https://doi.org/10.24941/ijcr.31773.08.2018>

radiographs according to their appearances, as unilocular, trabecular, or multilocular. Recently Cone Beam Computed Tomography (CBCT) is used as an alternative modality because it provides an adequate image quality associated with lower radiation exposure, fast scanning time, lower number of image artefacts and real time image analysis with higher accuracy for maxillofacial diagnostic purposes, such as the evaluation of cases with PAT and PRGF. Also, the medial portion of the articular eminence could only be thoroughly assessed on CT or CBCT (Ladeira *et al.*, 2013; Hasnaini and Ng, 2000; Miloglu *et al.*, 2011; Orhan *et al.*, 2005; Yavuz *et al.*, 2009; Shokri *et al.*, 2013; Barbosa *et al.*, 2014). So aim of the study was To assess the prevalences and characteristics of pneumatized articular eminence and pneumatized roof of glenoid fossa using CBCT.

MATERIALS AND METHODS

The study retrospectively reviewed 200 regions of 100 patients (64 males and 36 females) who had undergone CBCT examination for various purposes with a field of view including the TMJ were randomly selected from the archives of the Department of oral medicine and Radiology. Since this was a retrospective study involving CBCT images obtained for other reasons, no ethical regulation was required. Patient had scanned with CBCT (ORTHOPHOS XG 3D/Ceph manufactured by SIRONA, Germany) at 90KVp, 12mA, Digital Flat panel Detector with CMOS technology, integrated for 3D exposure technique. On axial view, the long axis of the condylar head was traced, and the reconstructed lateral and frontal cross-sectional imaging perpendicular and parallel, respectively, to the long axis of the condyle. In this study we used sagittal sections. CBCT scans with distorted images, severe artefacts, incomplete component of TMJ, Paediatric patients, anatomical pathology or a history of maxillofacial fractures in the zygomatic arch were excluded from the study. A maxillofacial radiologist assessed the CBCT scan in the room where low ambient light is present and image contrast and brightness were adjusted to ensure optimal visualization. The patients age, sex, presence of PAT and PRGF, their locations (unilateral or bilateral), their internal structure (unilocular or multilocular) were assessed on CBCT. The images were classified by radiologist according to the study conducted by Al- Faleh and Ibrahim (Al-Faleh and Ibrahim, 2005) as follows: grade 0, pneumatization limited to the mastoid process (Fig.A); grade 1, pneumatization between the mastoid process and the glenoid fossa (Fig.B); grade 2, pneumatization between the deepest point of the glenoid fossa and the tip of the articular eminence (Fig.C); grade 3, pneumatization extending beyond the crest of the articular eminence (Fig. D). Grade 2 and grade 3 pneumatizations were accepted as pneumatization of the articular eminence.

RESULTS

The study sample consisted of 200 regions of 100 patients (PAT and PRGF). 64 participants were females and 36 were males. Out of 200 regions PAT was found in 6%(12) and PRGF was found in 28% (56). Of the 12 with PAT, 66%(8) were male and 33.33%(4) were female. (Fig-E) Of the 28%(56) with PRGF, 69.64%(39) were male and 30.35%(17) were female (Table-1, Fig- F). The mean age of participants was 51.29 ± 13.38 years, with a range of 18–68 years. In individuals with PAT, 9 (75%) presented unilaterally, and 3 (25%) bilaterally. In individuals with PRGF, 23 (41.07%)

presented with unilateral and 33 (58.92%) with bilateral PRGF (Table-2). Of the 200 investigated areas, 66%(132) had grade 0 pneumatization, 24%(8) had grade1 that is pneumatization found between the mastoid process and the glenoid fossa, 6% (12) had grade 2, and 4% (8) had grade 3 that is pneumatization extending beyond the crest of the articular eminence (Table-3, Fig- G)

Table 1. PAT AND PRGF According to gender

	PAT	PRGF
Male	8(66.66%)	39(69.64%)
Female	4(33.33%)	17(30.35%)
Total	12	56

Table 2 . Prevalence and distribution of pneumatization cases with respect to localization, laterality and type

	Sample	PAT	%	PRGF	%
TMJ	200	12	6%	56	28%
LATERALITY					
Unilateral		9	75%	23	41.07%
Bilateral		3	25%	33	58.92%
TYPE					
Unilocular		4	33%	4	8%
Multilocular		8	66%	52	92%

Table 3. Prevalence of Degree of Pneumatization

	No of scans	Percentage
Grade 0	132	66%
Grade 1	48	24%
Grade 2	12	6%
Grade 3	8	4%
Total	200	100%

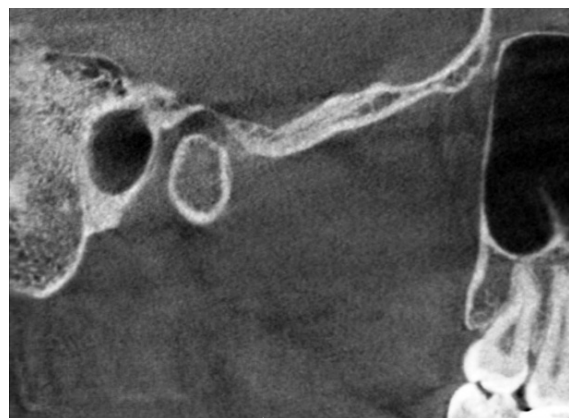


Fig. A. Grade 0 pneumatization

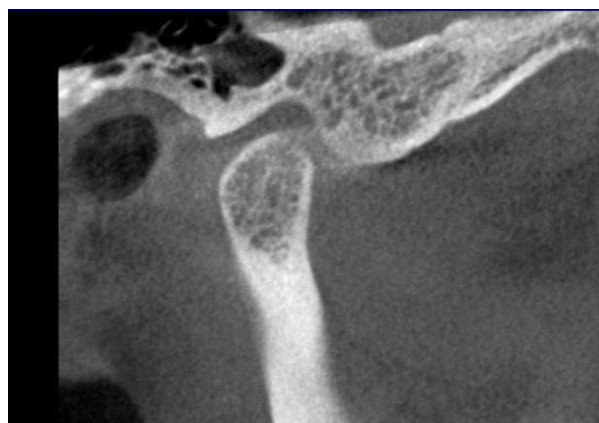


Fig. B. Grade 1 pneumatization

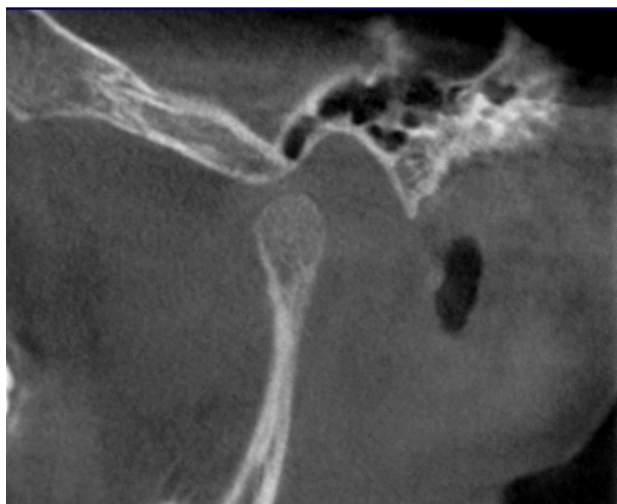


Fig. C. Grade 2 pneumatization

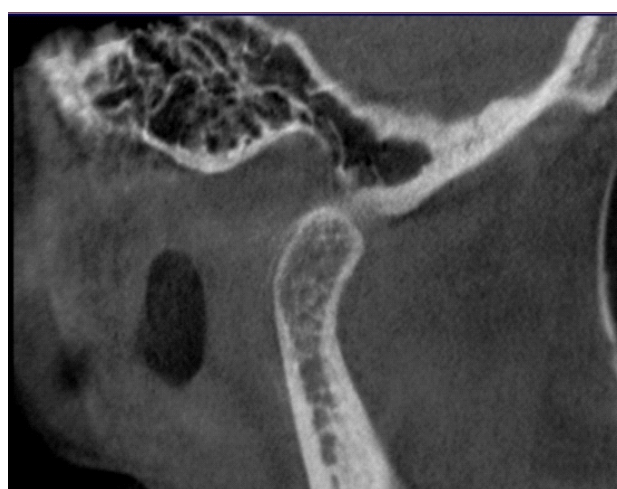

Fig. D. Grade 3 pneumatization

DISCUSSION

Detection of pneumatization can help to prevent undesirable complications. Most of the studies were carried out on panoramic radiographs. The prevalence of pneumatization has been reported to be between 1.0% and 3.42% in these studies. The study by Miloglu *et al.*, 2011, used CBCT images to evaluate the frequency of PAT. The prevalence increased to 8% with CBCT, a significant difference when compared to the rates found in panoramic images. The use of conventional panoramic radiographs to evaluate PAT is expedient because the radiographs are obtained during routine examination of many patients because of its low cost, low radiation dose and good visualization of the articular eminence. An innate problem of panoramic radiographs is the superimposition of adjacent structures. For that reason, three dimensional (3D) examination is considered the method of choice for the assessment of bony structures and air spaces in the base of the skull.⁶ Not only does CBCT not result in superimposition but it is also more diagnostically accurate compared to panoramic radiographs, for the assessment of air spaces in the skull base.¹² Hence we used cone beam computed tomography images in this study. We found the study concerning Prevalence and Characteristics of Pneumatized Articular Tubercle and Pneumatized Roof of Glenoid Fossa on Cone Beam Computed Tomography in Selected Iranian Population (Farzaneh Mosavat *et al.*, 2015) and that was 21.3% and 5.9%, respectively, this compares with 6% and 28%, respectively, in the present study.

In the current study, the prevalence of unilateral and bilateral PAT was 9 (75%) and 3(25%), respectively. This is consistent with previous studies by Farzaneh Mosavat *et al.* 2015. In case of PRGF, previous studies performed by Laderia *et al.* 2013 and Groell *et al.* 1999 reported the prevalence to be 38.3% and 51%, respectively (1, 2) and these studies differ in sample size and composition of the populations. However, in the present study, the prevalence was found to be 26%. The prevalence reported by Groell *et al.* 1999 was higher as compared to our results and this difference might be attributed to the sample source, as Groell *et al.* 1999 studied an Austrian population. In terms of type of pneumatization, most studies reported an almost equal distribution of unilocular and multilocular types (Orhan *et al.*, 2015; Shokri *et al.*, 2013; Barbosa *et al.*, 2014), except Laderia *et al.* 2013, Farzaneh Mosavat *et al.* 2015, Zamaninaser *et al.* 2012, who reported a higher prevalence of the multilocular type, consistent with our study. In our study, grade 2 and grade 3 pneumatizations were suitable for indicating pneumatization of the articular eminence, because grade 2 was defined as pneumatization between the deepest point of the glenoid fossa and the tip of the articular eminence and grade 3 was defined as pneumatization extending beyond the tip of the articular eminence. We found that 10 % of the 200 investigated areas had grade 2 and grade 3 pneumatizations and these findings are compatible with those of Groell and Fleischmann (Groell *et al.*, 1999).

Pneumatization facilitates the spread of various disease processes along the joint such as tumours, inflammation and fractures due to minimal resistance, so it is important to diagnose pneumatization (Miloglu *et al.*, 2011). Also, the PAT should be considered as a complicating factor, in cases where it is necessary to surgically manipulate the articular eminence (Tyndall and Matteson, 1985), because perforation can occur owing to firm dissection or forceful flap retraction (Miloglu *et al.*, 2011). Therefore, professionals have to be aware of these conditions. Because of knowledge about these structures, the interpretation of images can be easy and provides valuable information to understand the spread and differential diagnosis of pathological entities in this region (Miloglu *et al.*, 2011). Treatment of PAT or PGRF is unnecessary. If a professional observes pneumatization without symptoms, it should be kept under observation. The differential diagnosis includes aneurysmal bone cyst, hemangioma, giant cell tumour, eosinophilic granuloma, fibrous dysplasia and metastatic tumor (Tyndall and Matteson, 1985; Orhan *et al.*, 2006). All these entities are characterized by painful enlargement of the cheek and seen radiographically as expansive and destructive lesions.

Conclusion

It is concluded that the prevalence of PAT and PRGF should be assessed in every population due to the importance of temporal air cells. CBCT images are accurate and reliable means to detect the exact size and type of pneumatization and their relationship to adjacent tissues. Detection of pneumatization is necessary before a surgical intervention is planned, in order to prevent complications. Further research should be carried out in larger populations and specific groups of patients to provide a more accurate picture of this issue.

Support: No support in financial or other manner

Conflicts of interest: No conflicts of interest

REFERENCES

- Al-Faleh W, Ibrahim ME. 2005. A tomographic study of air cell pneumatization of the temporal components of the TMJ in patients with temporomandibular joint disorders. *Egypt Dent J.*, 51:1835-42.
- Barbosa GL NM, Ladeira DB, Bomtorim VV, da Cruz AD, Almeida SM. 2014. Accuracy of digital panoramic radiography in the diagnosis of temporal bone pneumatization: A study in vivo using cone-beam-computed tomography. *J Craniomaxillofac Surg.*, 42:477-81.
- Carter LC, Haller AD, Calamel AD, Pfaffenbach AC. 1999. Zygomatic air cell defect (ZACD). Prevalence and characteristics in a dental clinic outpatient population. *Dentomaxillofac Radiol.*, 28(2):116-22.
- Carter LC, Haller AD, Calamel AD, Pfaffenbach AC. 1999. Zygomatic air cell defect (ZACD). Prevalence and characteristics in a dental clinic outpatient population. *Dentomaxillofac Radiol.*, 28: 116-22
- Farzaneh Mosavat, Ahura Ahmadi, 2015. Pneumatized Articular Tubercle and Pneumatized Roof of Glenoid Fossa on Cone Beam Computed Tomography: Prevalence and Characteristics in Selected Iranian Population, *Journal of Dentomaxillofacial Radiology, Pathology and Surgery*, 14 (3).
- Groell R, Fleischmann B. 1999. The pneumatic spaces of the temporal bone: relationship to the temporomandibular joint. *Dentomaxillofac Radiol.*, 28:69-72.
- Hasnaini M, Ng SY. 2000. Extensive temporal bone pneumatization: incidental finding in a patient with TMJ dysfunction. *Dent. Update*, 27: 187-9.
- Hofmann T, Friedrich RE, Wedl JS, Schmelzle R. 2001. Pneumatization of the zygomatic arch on pantomography. *Mund Kiefer Gesichtschir.*, 5:173-9.
- Ilguy M, Dolekoglu S, Fisekcioglu E, et al. 2015. Evaluation of pneumatization in the articular eminence and roof of the glenoid fossa with cone-beam computed tomography. *Balkan Med J.*, 32(1):64-8.
- Ladeira DB, Barbosa GL, Nascimento MC, Cruz AD, Freitas DQ, Almeida SM. 2013. Prevalence and characteristics of pneumatization of the temporal bone evaluated by cone beam computed tomography. *Int J Oral Maxillofac Surg.*, 42:771-5.
- Miloglu O, Yilmaz AB, Yildirim E, et al. 2011. Pneumatization of the articular eminence on cone beam computed tomography: prevalence, characteristics and a review of the literature. *Dentomaxillofac Radiol.*, 40: 110-4.
- Orhan K, Delilbasi C, Cebeci I, Paksoy C. 2005. Prevalence and variations of pneumatized articular eminence: a study from Turkey. *Oral Surg Oral Med Oral Pathol Oral Radiol Endod.*, 99:349-54.
- Orhan K, Delilbasi C, Orhan AI. 2006. Radiographic evaluation of pneumatized articular eminence in a group of Turkish children. *Dentomaxillofac Radiol.*, 35:365-70.
- Shokri A, Noruzi-Gangachin M, Baharvand M, Mortazavi H. 2013. Prevalence and characteristics of pneumatized articular tubercle: First large series in Iranian people. *Imaging Sci Dent.*, 43(4):283-7.
- Tyndall DA, Matteson SR. 1985. Radiographic appearance and population distribution of the pneumatized articular eminence of the temporal bone. *J Oral Maxillofac Surg.*, 43:493-7.
- Yavuz MS, Aras MH, Güngör H, Büyükkurt MC. 2009. Prevalence of the pneumatized articular eminence in the temporal bone. *J Craniomaxillofac Surg.*, 37:137-9
- Zamaninaser A, Rashidipoor R, Mosavat F, Ahmadi A. 2012. Prevalence of zygomatic air cell defect: Panoramic radiographic study of a selected Esfahanian population. *Dent Res J (Isfahan)*, 9(Suppl 1):S63-8.
