



ISSN: 0975-833X

Available online at <http://www.journalcra.com>

INTERNATIONAL JOURNAL
OF CURRENT RESEARCH

International Journal of Current Research
Vol. 10, Issue, 11, pp.75648-75650, November, 2018

DOI: <https://doi.org/10.24941/ijcr.33230.11.2018>

RESEARCH ARTICLE

DOES MEDULLARY CYTOLOGY STILL HAVE A PLACE IN HEMATOLOGY?

*Zahir Hanane, Mouhib Hanane, Ait Ameur Mustapha and Chakour Mohammed

Laboratory of Hematology, Avicenna Hospital of Marrakech, Faculty of Medicine and Pharmacy, Sidi Abbad, B.P. 7010, Marrakech 40000, Morocco

ARTICLE INFO

Article History:

Received 06th August, 2018
Received in revised form
13th September, 2018
Accepted 11th October, 2018
Published online 30th November, 2018

Key Words:

Medullary cytology,
Myelogram, Hemopathies,
Limits.

ABSTRACT

Background: The study of medullary cytology is essential for the diagnosis, management and follow-up of many haematological disorders. The myelogram allows a cytological analysis of the bone marrow after aspiration of the medullary sap. **Objective:** This work aims to determine the indications of the myelogram in our context and to review the contribution of this examination to the diagnosis process. **Results:** We present the results of a retrospective study, covering all myelograms performed in the hematology laboratory of Avicenna Hospital in Marrakech between May 2016 and June 2018. The prevalence of hematological diseases was 36% of all myelograms studied. The indications were dominated by disturbances of the hemogram (66%). Out of 350 cases reported, medullary plasmocytosis accounted for 15% of pathologies diagnosed against 9.5% of leukemias, 6% of megaloblastosis and 5% of myelodysplastic syndromes. Twenty-two percent of the marrow was reactive, while 31% of the samples were diluted and uninterpretable. **Conclusion:** The contribution of the myelogram to the diagnosis depends on a good interpretation, therefore the quality of realization. Its indication must be rational and its interpretation requires a good knowledge of the clinical and biological context.

Copyright © 2018, Zahir Hanane et al. This is an open access article distributed under the Creative Commons Attribution License, which permits unrestricted use, distribution, and reproduction in any medium, provided the original work is properly cited.

Citation: Zahir Hanane, Mouhib Hanane, Ait Ameur Mustapha and Chakour Mohammed, 2018. "Does medullary cytology still have a place in hematology?", *International Journal of Current Research*, 10, (11), 75648-75650.

INTRODUCTION

The cellular composition of the bone marrow is analyzed by the myelogram, performed after aspiration puncture of medullary sap. The myelogram is one of the main diagnostic tools for most hematological diseases. Its indications include diagnosis, staging and therapeutic follow-up of hematological diseases. Medullary aspiration puncture also allows more bone marrow samples to be obtained for other types of examinations, such as karyotyping, immunophenotyping, or microbiological testing (Letestu, 2003). The realization of the myelogram justifies in all cases a dialogue between, the clinician and the biologist in order to prioritize the examinations to be carried out, to discuss the clinical and biological elements allowing to reach a diagnosis certainty and allow optimal patient follow-up. This work aims to clarify the indications of the myelogram in our context and to review the contribution of this examination to the diagnosis process.

PATIENTS AND METHODS

This is a retrospective, descriptive study conducted over a period of two years (from May 2016 to June 2018), at the

*Corresponding author: Zahir Hanane

Laboratory of Hematology, Avicenna Hospital of Marrakech, Faculty of Medicine and Pharmacy, Sidi Abbad, B.P. 7010, Marrakech 40000, Morocco.

hematology laboratory of Avicenna Hospital in Marrakech. Covering all myelograms performed in outpatients or hospitalized patients at the same hospital. The medullary punctures were all performed at the level of the sternum with regard to the 2nd intercostal space for adults, and the anterior superior and posterior superior iliac spines for children. The punctures were performed with Jamshidi type trocar, spread on glass slides (medullary smear), then observed under a microscope after staining of May-Grünwald-Giemsa (MGG). As for the blood count, the blood count was determined on a calibrated and controlled "Sysmex® XT 4000" automated system, completed by a blood smear stained with a May-Grünwald-Giemsa (MGG), and then observed under a microscope. Data was collected from myelogram records at the hematology laboratory level. Data mining was performed using Excel © software and statistical analysis was performed using SPSS version 10 for Windows.

RESULTS

During this period, the prevalence of haemopathies was 36% of all myelograms studied. The average age of the patients was 47, with age extremes ranging from 1 year to 89 years. Of 350 cases, 54% were male, hence a sex ratio of 1.15. The indications were dominated by disturbances of the hemogram (66%), followed by gammopathies revealed mainly by a bone

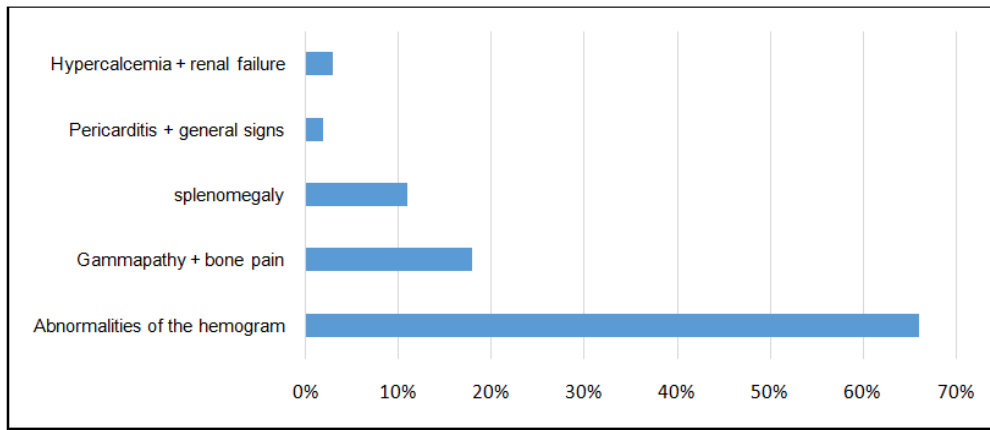


Figure 1. Indications of the myelogram

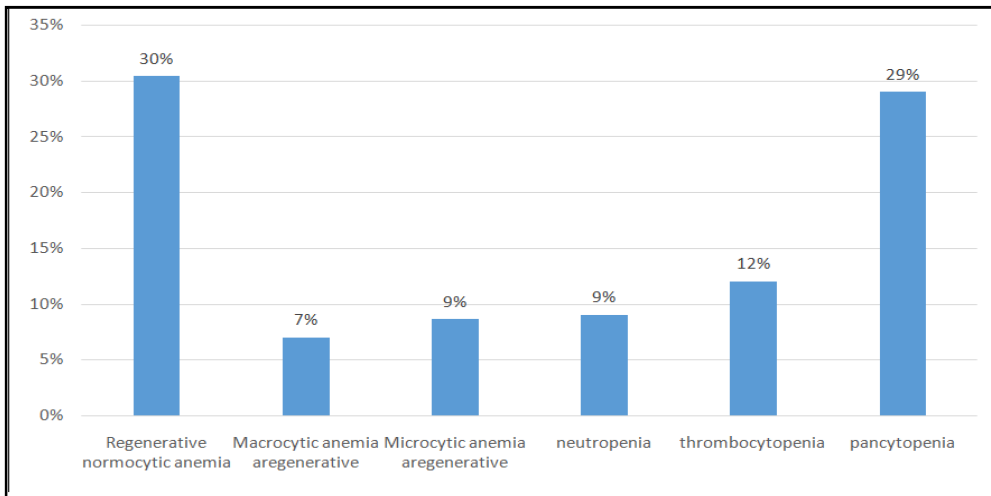


Figure 2. Frequency of hemogram abnormalities in our series

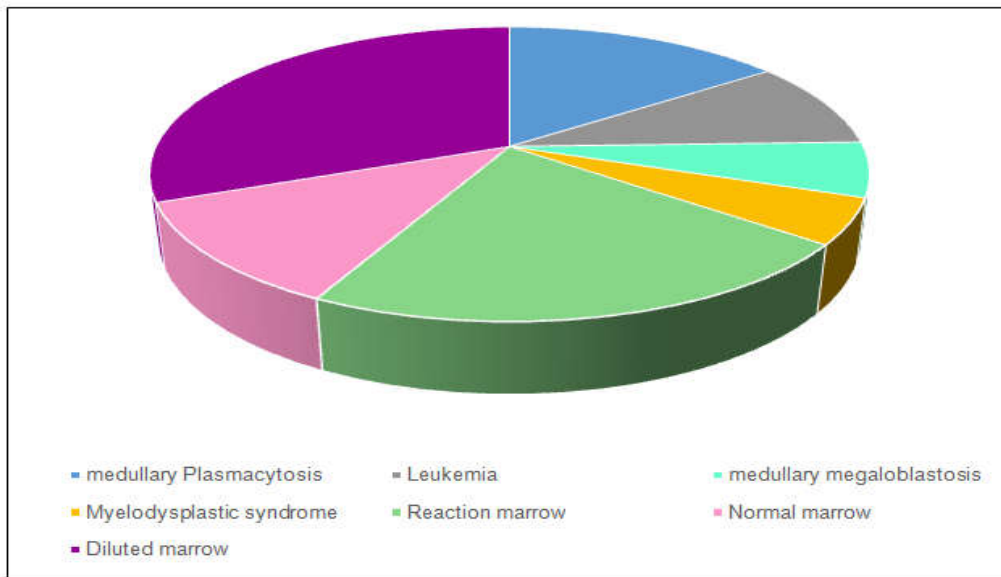


Figure 3. The results of the myelogram

syndrome (18% of cases), then splenomegaly isolated or associated with other clinical signs in third position (Figure 1). Among the disturbances in the blood count, anemia was the most frequent abnormality with a rate exceeding 46%, followed by thrombocytopenia found in 12% of cases, and leucopenia also found in 9.1% of cases. Pancytopenia accounted for 29.1% of all disturbances (Figure 2). Out of 350 cases collected, the medullary plasmocytosis accounted for

15% of pathologies diagnosed against 6% of megaloblastosis medullary, 5% of myelodysplastic syndromes and 9.5% of leukemias, divided as follows: 2 cases of Acute Lymphocytic Leukemia (ALL), 23 cases acute myeloid leukemia (AML), 7 cases of chronic myeloid leukemia (CML) and 1 case of chronic lymphocytic leukemia (CLL). 11.5% of the marrows were normal, 22% reactive, while 31% of the samples were diluted and uninterpretable (Figure 3).

DISCUSSION

The study of medullary cytology is important in the diagnosis and follow-up of the majority of hematological disorders. Medullary smears allow to assess the global medullary cellularity and the megakaryocyte richness, to make a differential count of the cells, to study the morphology, to evaluate the medullary reserves in iron and to look for an abnormal cellular infiltration (Baccini, 2017). The success of a myelogram depends first of all on the pre-analysis stage, i.e. the quality of the sample, smears and staining (Trimoreau, 2011). Its reading then requires an experienced cytologist who confronts the clinical and biological data and the anomalies observed on the myelogram to propose one or more diagnostic hypotheses. The abnormalities of the hemogram represented the first indication of the myelogram in our context. Studies by O. El Hamdaoui (El Hamdaoui, 2018), and S. Ouattara (Ouattara, 2008), yielded similar results concerning the frequency of abnormalities of the hemogram, with the predominance of pancytopenia in the series of S. Ouattara. In general, the myelogram is indicated on the occasion of the discovery of abnormalities of the hemogram (exploration of unexplained anemia, thrombocytopenia, leukopenia, bi- or pancytopenia, discovery of circulating blasts, etc.). Apart from abnormalities of the hemogram, the myelogram could be indicated for exploration of a monoclonal peak, splenomegaly or as part of a marrow extension assessment of a solid tumor (Charpentier, 2012). In our work, the study of the myelogram led to the diagnosis of 53 cases of medullary plasmocytosis and 22 cases of megaloblastosis. Megaloblastic anemias accounted for 35% of the pathologies found in S. Ouattara et al (Ouattara, 2000). The AML was noted in 23 cases of our series and the ALL in 2 cases. S. Ouattara et al reported 9 cases per year of acute leukemia, whether lymphoblastic or myeloblastic (Ouattara, 2000). ALL is essentially a pathology of the child, while the AML on the other hand is a pathology of the adult (Duployez, 2018). This high frequency of AML in our series could be explained by the fact that our patients were mostly adults. Reaction marrows were noted in 22% of patients in our series. This medullary reaction is not specific and is observed in a large number of pathological conditions: toxic, viroses, parasitosis. Myelogram was diluted in 31% of cases. The most common causes of these dilutions are technical errors during sampling. Other causes of diluted marrow are: fibrosis and medullary aplasia (Charpentier, 2012).

CONCLUSION

The myelogram is an invasive examination. Its contribution to the diagnosis process depends on its good interpretation, therefore the quality of realization. However, the myelogram has limitations related to the non-respect of preanalytical conditions, the detection of abnormalities in non-significant proportions, and the observation of difficult recognition cells. Similarly, the myelogram cannot always reveal cells that are heterogeneously distributed in the marrow, and a negative result does not mean that the cells are absent (Charpentier, 2012). To sum up, the myelogram is often part of a panel of complementary analyzes towards diagnosis, classification and assessment of prognosis: flow cytometry, cytogenetics and molecular biology.

Conflict of interest: none.

REFERENCES

- Baccini V, Sébahoun G. Cytologie et histologie médullaires. *EMC - Hématologie* 2017;12(2):1-10 [Article 13-000-A-30].
- Charpentier A. Myélogramme normal chez l'adulte. *EMC-Biologie médicale*. 2012 ;90 :15-0098-A.
- Duployez N, Decool G, Preudhomme C. Classification et facteurs pronostiques des leucémies aiguës. *EMC - Hématologie* 2018;13(3):1-14.
- El Hamdaoui. L'apport du myélogramme dans le diagnostic des hémopathies: expérience du laboratoire central d'hématologie de l'hôpital Ibn Sina de Rabat. Thèse de médecine. Université Mohammed V, Faculté de médecine et de pharmacie Rabat, 2018,207 p.
- Letestu F, Valensi R. La ponction aspiration médullaire à visée diagnostique. *Ann Biol Clin* 2003, 61(6): 655-65.
- Ouattara S, Danho B, Kone M et al. La pratique du myélogramme au chu de treichville: bilan de 19 années d'activité. *Médecine d'Afrique Noire* 2000 ;47(5) :240-243.
- Trimoreau F, Gachard N, Vrain A et al. Étapes préanalytiques pour la cytologie médullaire, ganglionnaire et des liquids biologiques. *EMC- Biologie clinique*. 2011 ;90 :15-0056-A.
