



ISSN: 0975-833X

Available online at <http://www.journalcra.com>

International Journal of Current Research
Vol. 11, Issue, 05, pp. 4098-4104, May, 2019

DOI: <https://doi.org/10.24941/ijcr.35518.05.2019>

INTERNATIONAL JOURNAL
OF CURRENT RESEARCH

REVIEW ARTICLE

TOOTH COLOURED CROWNS IN PEDIATRIC DENTISTRY – A REVIEW

***Amrutha, B.**

Assistant Professor, Department of Pedodontics and preventive dentistry, Rajarajeshwari Dental College and Hospital, Bangalore 560074, India

ARTICLE INFO

Article History:

Received 17th February, 2019
Received in revised form
09th March, 2019
Accepted 3rd April, 2019
Published online 30th May, 2019

Key Words:

Esthetics, Decay, Esthetic crowns,
Primary anterior teeth, Restorations.

*Corresponding author: Amrutha, B.

Copyright © 2019, Amrutha. This is an open access article distributed under the Creative Commons Attribution License, which permits unrestricted use, distribution, and reproduction in any medium, provided the original work is properly cited.

Citation: Amrutha B, 2019. "Tooth coloured crowns in pediatric dentistry – A review", *International Journal of Current Research*, 11, (05), 4098-4104.

ABSTRACT

Esthetic concerns about the smile often are the patient's main reason other than pain for seeking dental care. Esthetic problems in childhood and adolescence can have significant effect on psychosocial development and interaction with peers. A variety of esthetic restorative materials are available in the market for restoring primary incisors. So knowing in detail about the knowledge of the specific strengths, weakness, and properties of each material will enhance the clinician's ability to make the best choice of selection for each situation.

INTRODUCTION

Dental esthetics is an integral part of facial esthetics. Esthetic concerns about the smile often are the patient's main reason and then come the pain for seeking dental care. The psychological benefits of an oral esthetic improvement are potentially more important to a patient than traditional dentition procedures. Esthetic problems in childhood and adolescence can have significant effect on psychosocial development and interaction with peers. Alterations in tooth morphology like abnormalities in shape, size, color and structure of the whole part of the anterior dentition of children can affect on psychosocial development (Bryan, 2003). As there is increasing awareness towards esthetic options available, there is a greater demand for solutions to problems such as nursing bottle caries, malformed/altered and discolored teeth, hypoplastic defects, tooth fractures and bruxism in children. Esthetic restoration of primary anterior teeth can be extremely challenging to clinician due to its morphology like small size of the teeth, close proximity of pulp to tooth surface, relatively thin enamel and surface area for bonding and other issues like child behavior and management and finally cost of the treatment (Shah *et al.*, 2004). Alterations of tooth morphology may also lead to development of parafunctional habits like tongue thrusting and speech problems, psychological problems, reduced masticatory efficiency and loss of vertical dimension of occlusion (Usha *et al.*, 2007). Hence it is important to restore crowns destroyed by caries to preserve the integrity of primary dentition until its exfoliation and eruption of permanent teeth.

In a recent years concept of treatment of extensively decayed primary teeth has been shifted from extraction to restoration. Early restorations consisted of placement of stainless steel crowns on severely decayed teeth. But these crowns had few functional drawbacks, were unaesthetic and their use was limited to posterior teeth. In the last two decades there has been a change in the interest by adults in esthetic restoration of the damaged dentition. Similarly, a higher esthetic standard is expected by parents for restoration of their children's carious teeth. Thus the choice of full coverage restorations for primary teeth must provide an esthetic appearance in addition to restoring function and durability. Several studies have been done to determine the strengths and weakness of the available treatment options but unfortunately so far there has been a varied response. Even though researchers have claimed that certain restorations are better than the others, the search for the ideal esthetic restoration for the primary teeth continues (Karthik Venkataraghavan).

Indications for full coverage restoration

- Multisurface caries
- Extensive cervical decalcification
- Following pulp therapy
- Fractured anterior
- Loss most of the tooth structure
- Multiple hypoplastic defects or developmental disturbances on anterior teeth
- Discolored teeth that are aesthetically displeasing⁶

Full coverage restorations

The crowns that are available for restoring primary incisors can be placed into 2 categories:

1. Those that are preformed and held onto the tooth by a luting cement and
2. Those that are bonded to the tooth

The types of full coverage for anterior primary teeth currently available are:

Luted

- Stainless steel crowns
- Stainless steel crowns with facing
- Cheng crowns
- Kinder crowns
- Nu-smile crowns
- Dura crowns
- Whiter bite
- Pedo pearls
- Zirconia crowns

Bonded

- Polycarbonate crowns
- Strip crowns
- Pedo jacket crowns
- New millennium crowns
- Glastech crowns

In case of severely decayed teeth we can go do crown build up. Many types of crowns are available for maxillary primary incisors and canines. However, there are no crown forms available that is made specifically for mandibular incisors. If full coronal restoration of mandibular incisors is necessary, it requires the use of a maxillary lateral crown form unfortunately resulting in a very bulky looking restored incisor (Waggoner *et al.*, 2002).

Crowns for primary teeth

1. Stainless Steel Crowns (SSC) (Fig 1)

Stainless steel crowns are considered to be the most durable, economical and reliable for restoring severely carious and fractured primary incisors. They are easy to place, fracture proof, wear resistant and attaches firmly to tooth until exfoliation. However there is a compromise in esthetics due to the unsightly silver metallic appearance (Lee *et al.*, 2002). Now a day's esthetics has become more important and most parents demand esthetic restorations than metal crown's restoration which has metallic appearance. Recently veneered stainless steel crowns have become more popular. With veneered stainless steel crown, composite thermoplastic resin is bonded to the facial surface of traditional SSC which offer better esthetics combined with the durability of SSC.

Modifications of stainless steel crowns

a. Facial cut out Stainless steel crowns (Fig 2)

Here composite material is placed in a labial fenestration of SSC. Although there is an improvement in the appearance, the

technique is time consuming and metal margins are still visible. Clinicians even face problems to control hemorrhage during application of composite facing.⁷

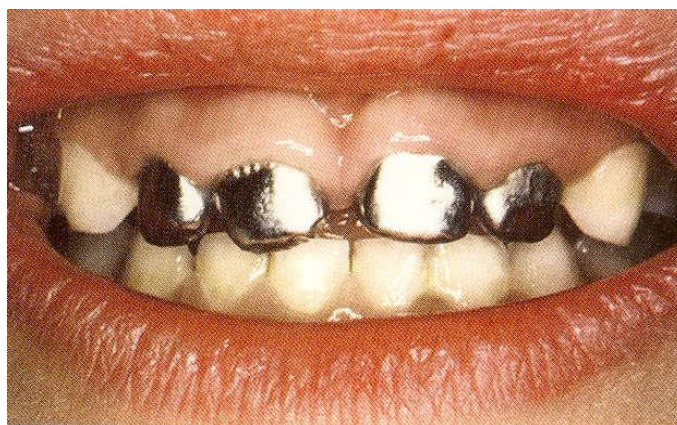

Fig. 1. Stainless steel crowns

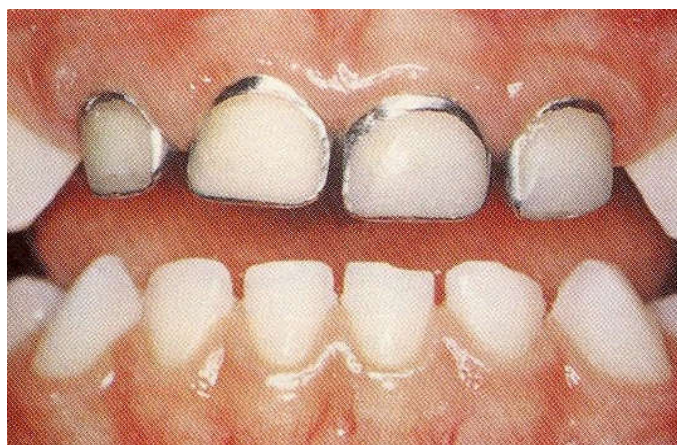

Fig. 2. Facial cut out stainless steel crown

Advantages

1. They are more esthetic than stainless steel crowns.
2. They restore the form and function of the tooth.
3. Cost is less when compared to veneered crowns.

Disadvantages

1. Time consuming procedure.
2. Metal margins are visible.
3. Operator sensitive as a variety of materials are used
4. Cutting the stainless steel metal inside the mouth can be dangerous as particles might injure the patient.
5. Facing can get dislodged

Glass ionomer as facing

Here glass ionomer is used as facing over buccal or labial surface to provide esthetic look. There was study done to compare between glass ionomer and composite resin as the facing material in open- faced stainless steel crowns for the primary dentition in vivo and in vitro. In the study stainless steel restorations with composite resin and glass ionomer cement were placed on primary anterior teeth. Replicas made at placement at one, four and twelve month interval recall appointment and later they were evaluated using a scanning electron microscope and a surface roughness analyser. Color

and retention were evaluated at each recall. Both materials exhibited increased incisal wear by 12 weeks but the average surface roughness did not change with time. By the 12 weeks, 23% of both glass ionomers and the composite resin were lost. The in-vitro micro-leakage on 30 crowns showed that the glass ionomer crowns exhibited more micro leakage than the composite facings regardless of the length of aging. These results were thought to be technique sensitive. The study revealed that the open-faced steel crowns seem to be suitable esthetic restoration for the pediatric patient (Lee, 2002).

b. Veneered Stainless steel crowns (Fig 3)

It includes bonding of composite resins and thermoplastics to the metal. This type of preveneered crown was developed to be a convenient, durable, reliable, and esthetic. Various commercially available veneered SSCs include Cheng crowns, Kinder crowns, Nu-smile and Whiter biter, pedo compu crowns and Dura crowns.

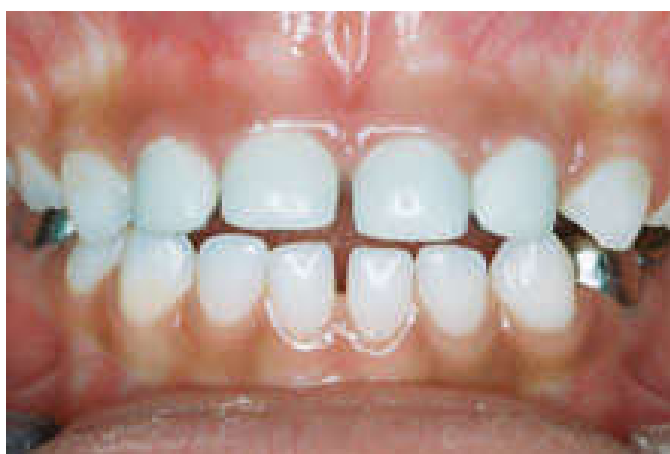

Fig. 3 Veneered stainless steel crown

Advantages

1. Durable and esthetically pleasing.
2. Less time consuming
3. Better bond strengths of the veneers to the crowns.
4. Crimping and adapting of crown is convenient.
5. Crowns can be sterile

Disadvantages

1. Operator sensitive.
2. Highly technique sensitive.
3. Cost factor.

Preveneered primary stainless steel crown

Here composite resin and thermoplastics are attached or bonded to stainless steel. These crowns are considered as superior to traditional stainless steel crowns and to the other crowns as they are comparatively more esthetic.

Advantages

1. Superior esthetics.
2. Easy to place.
3. Single appointment procedure
4. Hemorrhage and saliva does not interfere with the aesthetics of the crown.

Disadvantages

1. Crimping of the crown is limited to the lingual surface due to the facial veneer.
2. Expensive.
3. Heat sterilization of the crown can damage the veneer.
4. High failure of the esthetic facings has been reported.
5. Dentist has no control over the resin shade as they are pre-veneered.
6. Reshaping of the resin veneer is often necessary to eliminate the overly
7. Convex appearance of these crowns
8. Cannot be easily repaired

Cheng Crowns (Fig 4)

Cheng Crowns are Stainless steel pediatric anterior crowns faced with a high quality composite, mesh-based with a light cured composite. It presents a unique solution for natural-looking Stain-resistant Crowns. It is available for the right and left central and lateral as well as cuspids. Most crown procedures can be completed in one patient visit and with less patient discomfort (Baker *et al.*, 1996). It is available in short and regular lengths and sizes suitable for centrals, lateral and cuspids. They can undergo heat sterilization without significant effect on their bond strength and color. Disadvantages of all preveneered crowns are fracture of veneers during crimping and they are expensive (Baker *et al.*, 1996). It is a Stainless steel crown faced with high quality composite. It is claimed to be color stable, plaque resistant and suitable pedo-shades. It doesn't cause wear of opposing teeth. It is available in upper and lower right & left central and lateral with 6 sizes (Suzan Sahana, *et al.*, 2010).

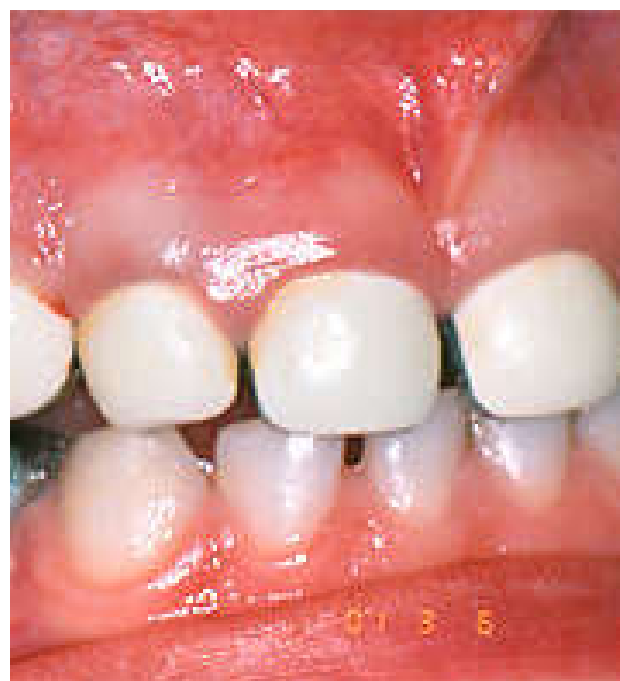

Fig. 4. Cheng crowns

Dura Crowns (Fig 5)

These crowns can be crimped labially and lingually, can be easily trimmed with crown scissors, easily festooned and has got a full-knife edge. Cheng crowns with veneer facings were significantly more retentive than the nonveneered ones when cement and crimping were combined (Guelmann *et al.*, 2003).



Fig. 5. Dura crowns

Kinder Crowns (Fig 6)

Kinder crowns offer the most natural shades and contour available for the pediatric patient. There is a great depth and vitality and reveal a natural smile without the bulky “Chiclet” look of other restorations.

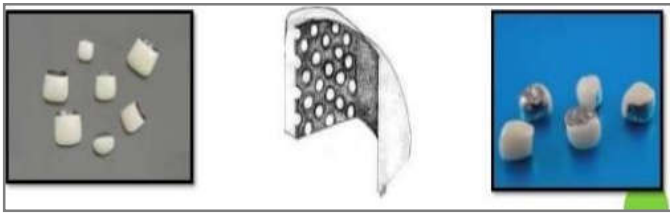


Fig. 6. Kinder crowns

They come in 2 aesthetically pleasing shades:

1. Pedo 1 - shade is for those cases when the bleached white shade is required
2. Pedo 2 - is the most natural shade.

Kinder Crowns are designed with Incisalock™ the optimal union of state-of-the-art bonding procedures and mechanical retention. By adding mechanical retention and more composite, Kinder Crowns are strong without sacrificing form or function (Baker *et al.*, 1996).

Advantages

1. Non – bulky
2. Good natural shade
3. Better retention (Baker *et al.*, 1996).

Nusmile primary crowns (Fig 7)

This is indicated when full coverage restoration is needed for longevity and for protection of remaining tooth structure.

Advantages

1. Colour compatibility
2. Stability
3. Easy placement
4. Less time consuming
5. Durable

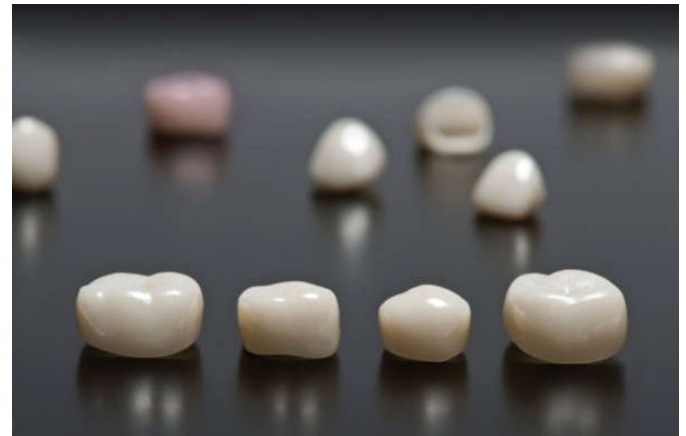

Fig. 7. Nusmile crowns

EZ pedo crowns

These are metal free prefabricated crowns which are built in Zir lock technology which increases the internal surface area reducing the possibility of clinical failure.

Advantages

1. Superior esthetics
2. High strength
3. Durable

Pedo natural crowns

- These crowns are made from polycarbonate material
- These are thin, ultra flexible and durable with superior marginal integrity and high tensile strength.

Pedo pearls (Fig 8)

These are beautiful heavy gauge aluminum crowns coated with FDA food grade powder coating and epoxy-resin. They serve as ultimate permanent crown for primary teeth.



Fig. 8. Pedo pearls

Features include

- Universal anatomy, can be used on either side
- Easy to cut and crimp without chipping or peeling.
- Composite can be added

Disadvantages

- Less durable

- Crowns are relatively soft (Yilmaz *et al.*, 2008).

Bonded crowns

1. Polycarbonate crowns (Fig 9)

Polycarbonate crowns have been used since many years because of their esthetic appearance. These crowns were first described in the literature by Mink J.W (1973) (Sherman *et al.*, 1966).



Fig. 9. Polycarbonate crowns

Advantages

- Thinner in structure and more pliable and therefore more adaptable.
- Significant functional advantages over preformed heat moulded acrylic resin crown.
- Provides for an esthetic restoration.

Disadvantages

- Cannot resist strong abrasive force.
- Fracture and dislodgement of the crown occurs frequently.
- Cannot be used in cases of bruxism and in cases of excessive abrasion to anterior teeth.
- Cannot be used in cases of deep bites.

Kudos crowns (temporary pediatric crowns) (Fig 10)

These are newer generation of pediatric polycarbonate crowns which is more users friendly & esthetically acceptable. The material is flexible, easily adaptable & reduces the chair side placement time considerably. It is also easy to use & handle along with considerably reducing the chair side working time & at the same time overcomes the difficulties reported so far pertaining to placement & retention (Karthik Venkataraghavan).

Strip crowns or celluloid crown (Fig 11)

Primary strip crowns which have been introduced in the market recently are good at delivering functional and esthetic needs in the primary dentin. These crowns were described by Grosso F.C (1987) (Roberts *et al.*, 2001) and are now being used for variety of clinical conditions both in the primary and

permanent dentition. These are commonly used Crown forms filled with composite & bonded on the tooth (Kupietzky *et al.*, 2003). Their superior esthetic appearance has made them popular among other esthetic crowns. Composite strip crowns rely on dentin and enamel adhesion for retention. Therefore the lack of tooth structure, the presence of moisture or hemorrhage contributes to compromised retention.



Fig. 10. Kudos crowns



Fig. 11. Strip crowns

Advantages

1. Highly esthetic.
2. Restores function.
3. Durable restoration.
4. Economical when compared with the preveneered crown.
5. Less injurious to the pulp in a vital tooth.
6. Causes fewer traumas to the periodontium.
7. Better retained than the polycarbonate crowns.

Disadvantages

1. Technique sensitive.
2. Retention depends on the amount of tooth structure remaining after the caries has been removed.
3. Hemorrhage during the procedure can adversely affect the esthetics of the crown.
4. Saliva contamination during the procedure also affects the retention of the crown.
5. Cannot be used in cases of severe bruxism.
6. Cannot be used in cases of excessive overbite.

Direct bonded glass ionomers crowns

Strip crowns utilizing composites as the bonding material had the disadvantage that it required adequate amount of tooth

material. So the use of glass ionomer as a bonding material came in to practice.

Advantages

1. Can be used in cases where there is inadequate tooth structure and enamel to retain a composite resin crown.
2. Leaching of fluoride from the glass ionomer gives an anti-cariogenic effect.
3. Surface hardness is superior to that of microfilled composite resins.
4. Easy repair possible.

Disadvantages

1. Low Bond strength.
2. The compressive strength is less than that of microfilled composites,
3. Wear resistance of glass ionomers are also poor.

Composite shell crowns

Recently composite shell crowns have been introduced in the market as an ideal esthetic restoration for grossly destructed anterior dentition. The direct composite strip crowns were operator sensitive and required proper isolation. So as a remedy to these problems the shell crowns were introduced, these crowns offer a durable and functional restoration and are highly esthetic.

Advantages

1. Less time consuming (impressions are not required for placing these crowns)
2. Durable restoration.
3. Esthetically superior.
4. Minimizes operator sensitivity associated with placement techniques.
5. Polymerization shrinkage associated with composites is reduced in these crowns.
6. Economically satisfactory

Disadvantages

1. Absence of required shades and sizes at present in the market.
2. Clinical trials on the crowns have not been published (Stewart *et al.*, 1974).

Recently introduced crowns

Zirconia crowns (Fig 12)

Zirconia crowns have been successfully used for permanent teeth for many years and provide excellent esthetics due to their natural appearance. Zirconia crowns are relatively new in the practice of pediatric dentistry, introduced in 2010. They are recommended for both anterior and posterior cases. Zirconia has a unique ability to resist crack propagation by being able to transform from one crystalline phase to another, and the resultant volume increase stops the crack and prevents it from propagating (Larsson *et al.*, 2011). It has demonstrated high wear resistance, excellent biocompatibility, and superior corrosion resistant (Piconi, 1990). Recently, the zirconium dioxide ceramic prefabricated crown has been used in the

treatment of primary teeth. The preparation of tooth for zirconia crown will take more time than other tooth preparation, and so this could be disadvantageous to be used for children who are fearful and unable to cooperate for longer procedures. Difficulty in adjustment as these crowns are ceramic in nature and cannot be trimmed with scissors like the one used for SSC, it is necessary to use a high speed, fine diamond burs with lots of water because excessive heat could cause fractures in the crown's ceramic structure. Occlusal and interproximal adjustments are not recommended, as these will remove the crown's glaze and possibly create a weak area of thin ceramic. It is very important that zirconia crowns fit passively because they are made of solid zirconia and do not flex, attempt to sit with force will result in fracture and adjustment with bur result in microfracture. The appropriate size crown should fit passively and completely subgingivally without distorting the gingival tissue (Karaca *et al.*, 2013; Soxman, 2015). Another concern is cementation. Etching and bonding is difficult as there is lack of silicone of glass ceramic. Conventional or self-adhesive resin cements have been recommended as luting agent for zirconia crowns (Planells del Pozo, 2014; Stawarczyk *et al.*, 2012).

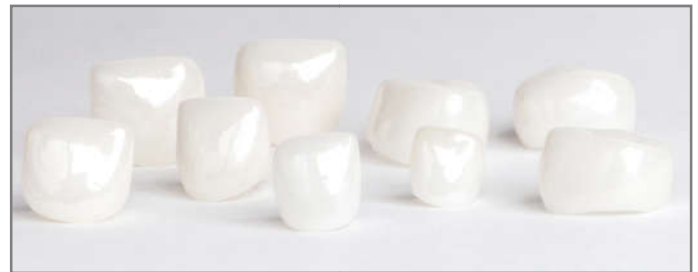

Fig. 12. Zirconia crowns

Advantages

1. High-end esthetics,
2. Superior durability, and
3. Easy placement compared to composite restorations and strip crowns (Khatri, 2017).

Disadvantages

1. It requires significantly more time to prepare the tooth for fitting the crown.
2. Bleeding from the gum
3. Adjustment of crown is difficult
4. Due to anxiety or inflammation, may hinder the setting of the cement used to bond the zirconia crown to the tooth (Planells del Pozo and Fuks, 2014).

Figaro crowns

Figaro Crowns are recently introduced crowns for primary teeth. These are said to be all white, metal-free, and BPA (Bisphenol-A)-free, and are made from the highest-quality, safest, and time-tested products used in dentistry and medicine today. Figaro Crowns are made in the U.S.A. and possess all ISO Certifications required by Canada Health and the FDA. The technique of crown preparation, selection, and delivery is similar to what is taught in dental school when placing a Stainless Steel crown (Figaro Crowns). Figaro Crowns' materials are said to be:

- **Biocompatible** – comprised of the same material currently used in pacemakers

- **Strong** - created for superior strength to withstand grinding and chewing bite force
- **Safe** - thoughtfully designed with materials that do not allow for sharp edges due to tooth grinding or shattering of the crown while clenching or chewing
- **Cost Effective** – we have virtually eliminated the risk of failure at delivery (i.e. cracking, breaking & chipping)
- **BPA and Metal Free** – provide peace of mind and reassurance for patient's parents
- **Autoclavable** - Studies yet to be done to prove the factors or advantages of Figaro crowns over other crowns.

Conclusion

Esthetic dentistry focuses on function and beauty with the values and the individual needs of the patient involving an attitude, artistic ability, intuition and technical competence. Esthetic dentistry can provide the beautiful smile that both parents and children desire. Dentists who care for children have the wonderful task and ability to create beautiful smile for these young patients. Many restorative options exist for treating primary anterior teeth. Finally the choice of restorative technique depends upon the operator preferences, esthetic demands by the parents and child's behaviour that affect the ultimate outcome of which ever restorative material chosen.

REFERENCES

Baker LH, Moon P, Mourino AP. 1996. Retention of esthetic veneers on primary stainless steel crowns. *ASDC J Dent Child.*, 63:185-9.

Bryan, Welburry Treatment of esthetic problems in pediatric dentistry. *Dent update*, 2003; 30(6):307-13

Figaro Crowns, Inc (www.Google.com)

Guelmann M, Gehring DF, Turner C. 2003. Retention of veneered stainless steel crowns on replicated typodont primary incisors: an in vitro study. *Pediatr Dent.*, 25:275-8

Karaca S, Ozbay G, Kargul B. 2013. Primary zirconia crown restorations for children with early childhood caries. *Acta Stomatol Croat.*, 47:64-71

Karthik Venkataraghavan, John Chan Polycarbonate Crowns for Primary teeth Revisited – Restorative options, Technique & Case reports.

Khatir A. 2017. Esthetic zirconia crown in pedodontics. *Int J Pedod Rehabil.*, 2:31-3.

Kupietzky A, Waggoner WF, Galea J. 2003. The clinical and radiographic success of bonded resin composite strip crowns for primary incisors. *Pediatr Dent.*, 25:577-81

Larsson C. 2011. Zirconium dioxide based dental restorations. Studies on clinical performance and fracture behaviour. *Swed Dent J Suppl.*, 213:9-84

Lee JK. 2002. Restoration of primary anterior teeth:review of the literature. *Pediatr Dent.*, 24:506-10.

Mathew Renu Ann Esthetics in primary teeth. *Int. Res. J. Pharm.*, 2013; 4(8):80-82

Piconi C, Maccauro G. 1999. Zirconia as a ceramic biomaterial. *Biomaterials.*, 20:1-25.

Planells del Pozo P, Fuks AB. 2014. Zirconia crowns – An esthetic and resistant restorative alternative for ECC affected primary teeth. *J Clin Pediatr Dent*, 38:193-5.

Roberts C, Lee JY, Wright TJ. 2001. Clinical evaluation of and parental satisfaction with resin faced stainless steel crowns. *Pediatric Dentistry.*, 23: 28-31.

Shah PV, Lee JY, Wright JT. 2004. Clinical success and parental satisfaction with anterior veneered primary stainless steel crowns. *Pediatr Dent.*, 26:391-5

Sherman G, Bugg J L, Carruth K R. 1966. Restorations of primary incisors with acrylic jacket crown, One appointment procedure, *J of Dentistry for children*, 33:182-185.

Soxman JA. 2015. The Handbook of Clinical Techniques in Pediatric Dentistry. Hoboken: Wiley-Blackwell, p. 47-50.)

Stawarczyk B, Basler T, Ender A, Roos M, Ozcan M, Hämmerle C. 2012. Effect of surface conditioning with airborne-particle abrasion on the tensile strength of polymeric CAD/CAM crowns luted with self-adhesive and conventional resin cements. *J Prosthet Dent*, 107:94-101

Steven Schwartz Crest® Oral-B® at dentalcare.com Continuing Education Course, January 9, 2012

Stewart R E, Luke L S, Pike A R. 1974. Preformed polycarbonate crowns for restorations of anterior teeth, *JADA* 88 : 103-107.

Suzan Sahana, Aron Arun Kumar Vasa, Ravichandra Sekhar Esthetic crowns for primary teeth: A review. Vol. - II Issue 2 April – June 2010

Usha M, Deepak V, Venkat S, Gargi M. 2007. Treatment of severely mutilated incisors: a challenge to the pedodontist. *J Indian Soc Pedod Prev Dent.*, 25 Suppl:S34-6

Waggoner, WF. 2002. Restoring primary anterior teeth: Review. *Pediatr Dent.*, 24:511- 6.

Yilmaz Y, Guler C. 2008. Evaluation of different sterilization and disinfection methods on commercially made preformed crowns. *J Indian Soc Pedod Prev Dent.*, 26:162-7.)
