



ISSN: 0975-833X

Available online at <http://www.journalcra.com>

International Journal of Current Research  
Vol. 12, Issue, 01, pp.9332-9334, January, 2020

DOI: <https://doi.org/10.24941/ijcr.37649.01.2020>

INTERNATIONAL JOURNAL  
OF CURRENT RESEARCH

## RESEARCH ARTICLE

### HUMAN RENAL VESSELS VARIANT CLOSE TO THE HILUM OF THE RIGHT KIDNEY: A RARE CASE REPORT

\*Mahmoud Satte and Abdoalmonim Abdoalrahman Mohammed

Department of Anatomy, Faculty of Medicine, Najran University, Najran, 55461, KSA

#### ARTICLE INFO

##### Article History:

Received 25<sup>th</sup> October, 2019  
Received in revised form  
18<sup>th</sup> November, 2019  
Accepted 29<sup>th</sup> December, 2019  
Published online 30<sup>th</sup> January, 2020

##### Key Words:

Variation, Hilum,  
Right Kidney,  
Blood Vessels.

#### ABSTRACT

**Background:** The human kidneys are supplied by renal artery and vein. Close to the kidney hilum the renal artery is divided into anterior and posterior branches and then gives five segmental arteries before entering the hilum while the renal vein is formed by the union of the segmental veins. The variations can occur in these vessels according to the previous studies and these variations are important for surgeons. **Objectives:** This study was aimed to demonstrate variations of renal vessels close to the hilum of the right kidney. **Materials and methods:** The study was conducted on the human plastinated right kidney, during routine dissection for medical students in medical college, Najran University, KSA. **Results:** We observed six right segmental arteries and aberrant upper polar artery. In addition, we founded upper anterior, upper posterior and lower inferior renal veins leaving the hilum of the right kidney, the anterior upper one received three segmental veins while the upper posterior and lower anterior are continuous without receiving segmental veins. **Conclusion:** we observed a variation on renal vessels close to the hilum of the plastinated right kidney and this knowledge is important for surgeons doing kidney transplants.

Copyright © 2020, Mahmoud Satte et al. This is an open access article distributed under the Creative Commons Attribution License, which permits unrestricted use, distribution, and reproduction in any medium, provided the original work is properly cited.

**Citation:** Mahmoud Satte and Abdoalmonim Abdoalrahman Mohammed. 2020. "Human renal vessels variant close to the hilum of the right kidney: a rare case report", *International Journal of Current Research*, 12, (01), 9332-9334.

## INTRODUCTION

The right and left kidneys are supplied by the renal artery, the renal arteries are a pair of lateral branches from the abdominal aorta at the level of the second lumbar vertebra, and each renal artery, which usually divides into anterior and posterior divisions, then gives five segmental arteries (apical, superior, middle, inferior and posterior) close to the hilum of the kidneys (Snell, 2008; Standring, 2016). Multiple renal veins contribute to the formation of the left and right renal veins, both of which are anterior to the renal arteries (Drake *et al.*, 2010). However, the presence of accessory (aberrant) renal arteries is well known. The normal renal segmental arteries make their way to the kidney through its hilum whereas the aberrant renal arteries might enter the kidney through the hilum, through the surfaces or the poles of the kidney (Dhar and Lal, 2005). Most of the abnormalities in the renal vessels are due to the various developmental positions of the kidneys (Moore and Pesaud, 2015). Sound knowledge of the variations in the segmental vessels of the kidneys is important for urologists, radiologists, and surgeons in general.

The studying of renal vasculature may also be useful to clinicians performing invasive techniques and vascular surgeries, mainly during kidneys transplantations. Many reports on the renal vessel variations of the human kidney were achieved by authors. This case report was applied to renal vessels close to the hilum of the plastinated right kidney. Plastination is the modern process for tissue preservation that successfully around the world and the produced semi-original specimens used in teaching gross anatomy for medical students (Henry and Latorre, 2007). The objective of this case report is to bring awareness to clinicians about the variations of the blood vessels close to the hilum of the right kidney.

**Case Report:** During the gross anatomy dissection of the plastinated right kidney in Department of Anatomy, College of Medicine, Najran University, KSA, the following renal vessels variations were observed close to the hilum of the plastinated right kidney: the upper posterior division of the renal artery passed above and anterior to ureter, and gives apical, superior, middle & inferior segmental arteries, namely SA1, SA2, SA3, & SA4 respectively, and the lower anterior division of the renal artery located anterior and inferior to the ureter, its gives superior & inferior segmental arteries, namely SA5 & SA6 respectively (Figures 1, 2).

\*Corresponding author: Mahmoud Satte,  
Department of Anatomy, Faculty of Medicine, Najran University,  
Najran, 55461, KSA.

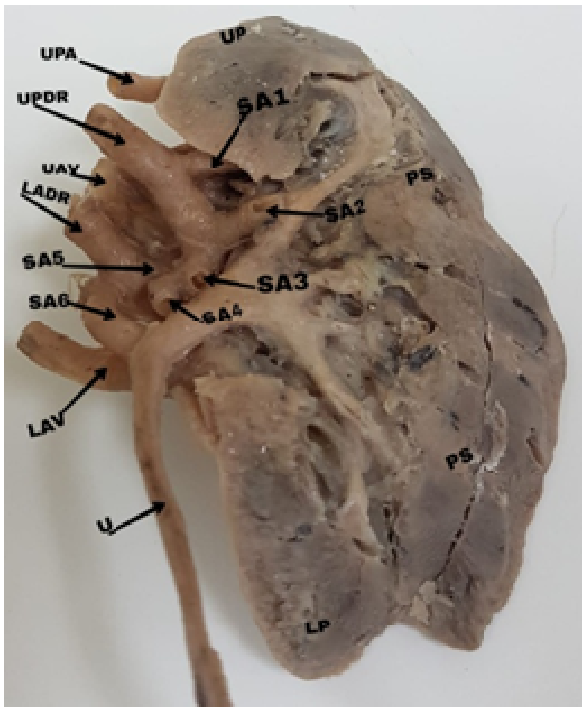


Figure 1. Posterior aspect of the right kidney: UP= upper pole, UPA= upper polar artery, UPDR= upper posterior division of renal artery, UAV= upper anterior renal vein, SA1= first segmental artery (apical), SA2= second segmental artery (superior), SA3= third segmental artery (middle), SA4= fourth segmental artery (inferior), SA5= fifth segmental artery (superior), SA6= sixth segmental artery (inferior), LADR= lower anterior division of the renal artery, LAV= lower anterior renal vein, U= ureter, PS= posterior surface of the kidney, LP= lower pole.

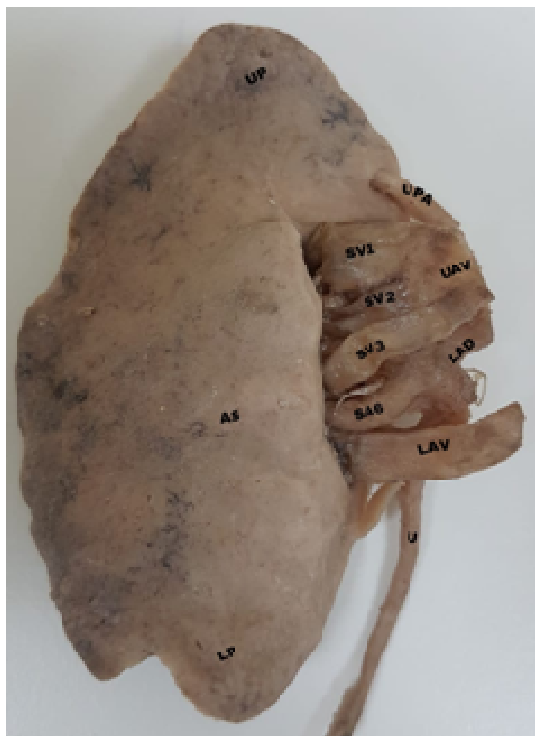

Figure 2. Anterior aspect of the right kidney: UP= upper pole, UPA=upper polar artery, UAV= upper anterior renal vein, SV1= first segmental vein, SV2= second segmental vein, SV3= third segmental vein, LAD= lower anterior division of the renal artery, SA6= sixth segmental artery, LAV= lower anterior renal vein, U= ureter, AS=anterior surface of the kidney, LP= lower pole.

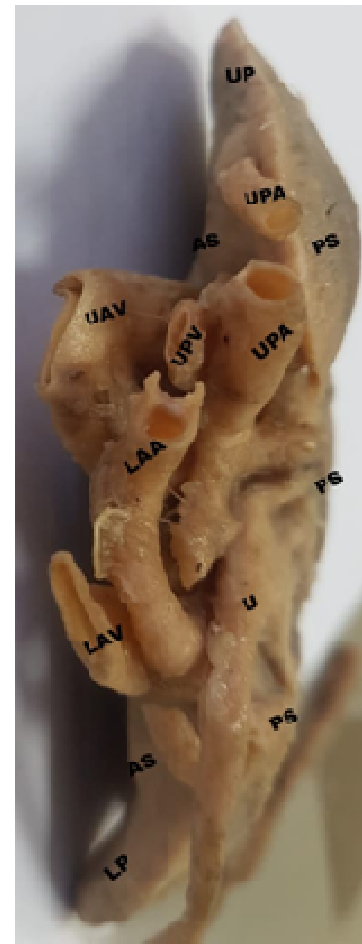


Figure 3. Medial aspect of the right kidney: UP= upper pole, UPA= upper polar artery, AS= anterior surface of the kidney, PS= posterior surface of the kidney, UAV= upper anterior renal vein, UPV= upper posterior division of renal artery, UPA= upper posterior division of the renal artery, LAA= lower anterior division of the renal artery, LAV= lower anterior renal vein, U= ureter, PS= posterior surface, AS= anterior surface, LP= lower pole.

We observed one upper polar artery, which enters the kidney close to the medial side of the upper pole (Figure 1). In addition, we founded triple veins, which named as upper anterior, upper posterior and lower anterior renal veins, the upper anterior vein received three segmental veins while the upper posterior and lower anterior veins are continuous without receiving any segmental veins (Figure 3).

## DISCUSSION

There are many studies were conducted on the variation of the segmental branches of the right renal artery and according to our knowledge they were showed that there are four to five segmental renal arteries originate from anterior and posterior division of the main right renal artery before reaching the hilum kidney, while the current study showed six segmental arteries. During routine dissection of a 49 years male cadaver, they observed that the right renal artery gave lower anterior and upper posterior divisions, the lower anterior division divided into middle and inferior segmental arteries while the upper posterior division divides into apical and superior segmental arteries and continues as the posterior segmental artery (Murudkar and Kumar, 2015). The difference is that in our findings the posterior division of the right renal artery gives apical, superior, middle and inferior segmental arteries.

The previous study showed that the anterior division of the right renal artery gives apical, upper, middle and lower segmental branches while the posterior division continued as posterior segmental artery (Rani *et al.*, 2014). In this case, the segmental arteries' origins are different, we found the anterior division of the right renal artery gives superior and inferior segmental arteries but the posterior division gives apical, superior, middle, and inferior segmental arteries. On the other hand of our study, we found aberrant renal arteries that not passing through the hilum but them passing close to the upper pole of the right kidney, namely it's the upper polar artery. Variations in presented of polar arteries were recorded in many previous cases, therefore, upper polar renal artery passing through the upper pole, and lower polar renal artery passing through the lower pole was noticed (Aritotle *et al.*, 2013; Atil and Mishra 2013; Budhiraja *et al.*, 2013). In our research, we found triple renal veins close to the hilum of the right kidney, namely the upper anterior, upper posterior and lower anterior renal veins. In the previous study of the adult male cadaver, the right kidney showed three renal veins, namely upper, middle and lower right renal (Mishra *et al.*, 2014; Femandes *et al.*, 2005). They are three but different in position pattern compared with our study, which showed two upper renal veins (anterior & posterior) and one lower. Although, in previous studies they noticed that there was one renal vein located in the hilum of the kidney and accessory right vein located inferior to the main right renal vein (Covantey *et al.*, 2017; Kanaskar, 2012). The two latter cases are different in compared with our findings, and they saw two renal veins crossed the hilum of the right kidney while in our study we found triple right veins, the upper anterior one formed by the union of three segmental veins.

## CONCLUSION

Our study presented variation in renal vasculature close to the hilum of the right kidney and these findings are usefully additional information's for clinicians and surgeons to achieve and control their procedures during abdominal operations or kidneys transplantations.

## REFERENCES

Snell, RS. 2008. Clinical anatomy by regions. 8th ed. Lippincott, Williams & Wilkins. 264-265.  
 Standing, S. 2016. Gray's anatomy: the anatomical basis of clinical practice. 41th ed. UK, London. Elsevier, 1243-1244.

Drake, R., Vogl, W., Mitchell, AWM. 2010. Gray's anatomy for students. Sec ed. Elsevier, Philadelphia, USA,: -358 359.  
 Dhar, P., Lal, K. 2005. Main and accessory renal arteries--a morphological study. *Ital J Anat Embryol.*, 2:101-10.  
 Moore, KL., Persaud, TVN. The Developing Human. 7<sup>th</sup> ed, Philadelphia, Saunders, 2015: 293-294.  
 Henry, RW., Latorre, R. 2007. Polyester plastination of biological tissue: P40 technique for brain slicing. *Journal of the international society for plastination.*, 22: 59-68.  
 Murudkar, PKH., Kumar, JA. 2015. The posterior division of the left renal artery is a direct branch of the abdominal aorta and early ramification of the renal arteries on both sides: a case report. *Int J Anat Res.*, 3:1087-91.  
 Rani, N., Singh, S., Dhar, P., Kumar, R. 2014: Surgical Importance of Arterial Segments of Human Kidneys: An Angiography and Corrosion Cast Study. *J Clin Diagn Res.*, 8: 1-3  
 Aristotle, S., Subramanian, S., Felicia, C. 2013: Anatomical Study of Variations in the Blood Supply of Kidneys. *J Clin Diagn Res.*, 7: 1555-1557.  
 Atil, SJ., Mishra, S. 2013: Inferior renal polar artery and its surgical importance. *OA Anatomy.*, 2:1-3.  
 Budhiraja, V., Rastogi, R., Anjankar, V., Babu, R., Goel, P. 2013: Supernumerary Renal Arteries and Their Embryological and Clinical Correlation: A Cadaveric Study from North India. *International Scholarly Research Notices.* 1-4  
 Mishra, GP., Bhatnagar, S., Singh, B. 2014: Unilateral triple renal veins and bilateral double renal arteries- a unique case report. *International Journal of Anatomy and Research.*, 2: 239-241.  
 Fernandes, RMP., Conte, FHP., Favorito, LA., Abidu-Figueiredo, M., Babinski, MA. 2005. Triple Right Renal Vein: An Uncommon Variation. *Int J Morphol.*, 3:231-233.  
 Covantey, S., Mazuruc, N., Belic, O. 2017: Renal Veins: Developmental Variations and Clinical Significance. *Online Journal of Health and Allied Sciences.*, 4: 1-3.  
 Kanaskar, N., Paranjape, V., Kulkarni, J., Shevade, S. 2012. Double Accessory Right Renal Arteries. *Journal of Dental and Medical Sciences.*, 5: 17-20.

\*\*\*\*\*