



ISSN: 0975-833X

Available online at <http://www.journalera.com>

International Journal of Current Research  
Vol. 12, Issue, 10, pp.14537-14541, October, 2020

DOI: <https://doi.org/10.24941/ijcr.40072.10.2020>

INTERNATIONAL JOURNAL  
OF CURRENT RESEARCH

## REVIEW ARTICLE

### SPACE MAINTAINERS: A BOON IN PREVENTIVE ORTHODONTICS

Gitarani Hazarika Bora, Meghali Langthasa and \*Swarga Jyoti Das

Regional Dental College and Hospital, Guwahati-781032, Assam, India

#### ARTICLE INFO

##### Article History:

Received 20<sup>th</sup> July, 2020  
Received in revised form  
27<sup>th</sup> August, 2020  
Accepted 19<sup>th</sup> September, 2020  
Published online 30<sup>th</sup> October, 2020

##### Key Words:

Deciduous Dentition, Mixed Dentition, Permanent Dentition, Space Maintainer, Preventive and Interceptive Orthodontics, Premature loss.

Copyright © 2020, Gitarani Hazarika Bora et al. This is an open access article distributed under the Creative Commons Attribution License, which permits unrestricted use, distribution, and reproduction in any medium, provided the original work is properly cited.

Citation: Gitarani Hazarika Bora, Meghali Langthasa and Swarga Jyoti Das. 2020. "Space maintainers: a boon in preventive orthodontics", *International Journal of Current Research*, 12, (10), 14537-14541.

#### ABSTRACT

The deciduous dentition plays a crucial role in the development and growth of a child. Premature loss of deciduous teeth can result in the discrepancies in the arch length which in turn leads to malocclusion. Early intervention in deciduous and mixed dentition can prevent the development of anomalies in the late mixed and permanent dentition. Thus, Preventive Orthodontics plays an important role in the management of the spaces, occupied previously by deciduous teeth, using the 'space maintainer' appliance. In this review article, various types of space maintainers used in our day to day clinical practices will be highlighted.

#### INTRODUCTION

The concept of space loss resulting from premature loss of primary teeth was described by Davenport in 1887 (Davenport, 1887). The primary dentition plays a very important role in the child's growth and development. The primary teeth not only help in speech, chewing and appearance but also guide the eruption of permanent teeth (Barberia and Lucavechi, 2006). Exfoliation of primary teeth and eruption of permanent teeth is a normal physiological process (Rao and Sarkar, 1999). Disruption in this physiological process of exfoliation may occur due to premature loss of primary teeth due to caries, infection, trauma, ectopic eruption. Subsequently, leads to crowding along with short arch length. Further, arch length deficiency can produce and even influences the severity of malocclusion in permanent dentition in the form of crowding, rotations, ectopic eruption, crossbite, excessive overjet, excessive overbite, impaction of permanent teeth, supraeruption of opposing teeth etc., and unfavorable molar relationships (Brothwell, 1997). The best way to avoid these problems is to preserve the primary teeth in the arch till attainment of their normal time of exfoliation. Hence it is rightly quoted that primary teeth serve as best space maintainers for permanent dentition (Setia et al., 2013). Space maintainers are the orthodontic appliances used in pediatric dentistry. The main function of these devices is to manage premature loss of primary teeth.

It has been reported that many orthodontic cases involving crowding and lack of space in the permanent dentition could have been prevented or the severity of the problems alleviated if the practitioner had maintained adequate space during the initial treatment of the mixed dentition. The safest way to prevent future malocclusions from tooth loss is to place an effective and durable space maintainer (Choonara, 2005). It is prudent to consider the space maintenance when primary teeth are lost prematurely. The following factors are to be considered (Brothwell, 1997; Dean, 2011):

- ) Specific tooth lost
- ) Time elapsed since tooth loss
- ) Occlusion and space assessment
- ) Dental age
- ) Presence and root development of permanent successor
- ) Amount of alveolar bone covering permanent successor
- ) Patient's health history and medical status patient's cooperative ability
- ) Active oral habits
- ) Oral hygiene

**Adverse effects associated with space maintainers** (Brothwell, 1997):

- ) Dislodged, broken, and lost appliances
- ) Plaque accumulation
- ) Increase in microorganisms and increase in periodontal index scores

\*Corresponding author: Swarga Jyoti Das

Professor & Head, Department of Periodontics, Regional Dental College and Hospital, Guwahati-781032, Assam, India.

- ) Caries
- ) Damage or interference with successor eruption
- ) Undesirable tooth movement
- ) Inhibition of alveolar growth
- ) Soft tissue impingement
- ) Pain

### Classification

There are numerous types of space maintainers. They range from the very simple to those with numerous bands and wires. They may be of removable or fixed, and they may be of unilateral or bilateral.

- Removable space maintainer can be removed, while fixed space maintainer is fixed (i.e., held) to a tooth or to more than one tooth by cement.
- Unilateral space maintainers are fixed to one side of the mouth, while bilateral space maintainers are fixed to both sides of the mouth. Fixed space maintainers can be unilateral or bilateral.

Developmental stage of the dentition, number of lost teeth, dental arch and occlusion, age and psychological condition of the patients, and their cooperative ability are the factors that influence the choice of the space maintainers (Beena, 2011).

### REMOVABLE SPACE MAINTAINERS

They are of two types:

- ) Simple acrylic plate: non-functional space maintainer (Rani, 2014) (Fig. 1 A, B)
- ) Removable partial denture/Functional space maintainer: It helps in mastication in the posterior region, while improves esthetics in the anterior region. It also prevents abnormal speech and tongue habits (Dean, 2011) (Fig. 1 C, D)

Again, the removable functional space maintainers may be unilateral (Fig 1 C) and bilateral (Fig. 1 D). In removable space maintainers, retention and compliance are the two major drawbacks. Attachments are added for the purpose of retention. The problem of compliance is closely related to that of retention. The children in primary dentition age group are very unreliable to taking care of removable appliances, and thus, the appliances are apt to become lost or damaged. They may not even wear it. Besides, they present swallowing and choking dangers for children (Rani, 2014).

**Fixed unilateral space maintainers:** The most frequently used fixed space maintainer is of Band and Loop type (Wright and Kennedy, 1978).

**Band and loop space maintainer:** The band and loop space maintainer is indicated for the premature loss of single, unilateral or bilateral maxillary or mandibular primary molars and is generally not recommended where multiple teeth have been lost. Band and loop space maintainer adjusts easily to accommodate changing dentition (Nayak *et al.*, 2004). Space maintenance is necessary to hold the second primary molars in position, especially as the first permanent molars erupt and create forces which otherwise would move the primary molars forward. However, it does not help in mastication and will not prevent the continued eruption of the opposing teeth (Kisling and Hoffding, 1979; Chawla *et al.*, 1985).

In its traditional design, it consists of a band around one of the teeth adjacent to the edentulous area and a 0.032 or 0.036 stainless steel wire loop that forms a cantilevered loop from soldered attachments on the buccal and lingual surfaces of the band to the tooth on the other side of the edentulous space (Fig. 2 A). The band is usually placed on the tooth distal to the extraction space (e.g., on the primary second molar to contact the primary canine or on the first permanent molar to contact the primary first molar). Placement of the band and loop traditionally involves two appointments one to fit the band and take an impression for a dental cast on which to fabricate the appliance and another to deliver the appliance. As with any of the space maintainers using bands or stainless steel crowns as abutment teeth, separators may be placed 1 - 2 weeks before the first appointment to facilitate the fitting of bands, if there are adjacent teeth. It is a technique sensitive procedure, as band displacement during pouring of the cast is common.

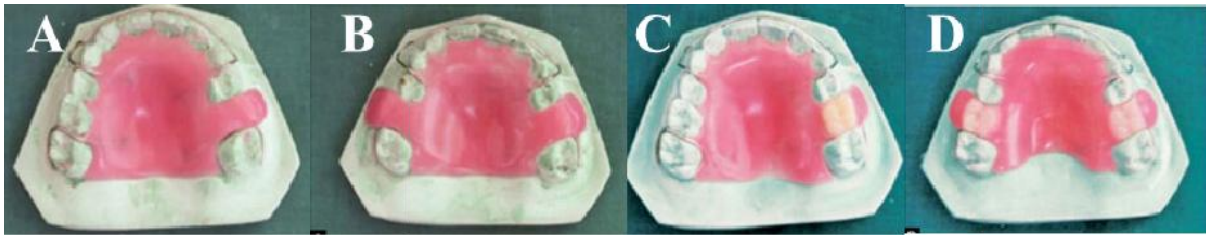### Variations on the traditional band and loop (Rani, 2014)

**Reverse band and loop:** This is used to maintain the space of the primary second molar where the permanent first molar has not erupted enough for band placement. The band may be placed on the primary first molar with the loop extending distally to contact the mesial surface of the permanent first molar. It has limited utility, as the first primary molar abutment may exfoliate before eruption of the permanent second premolar.

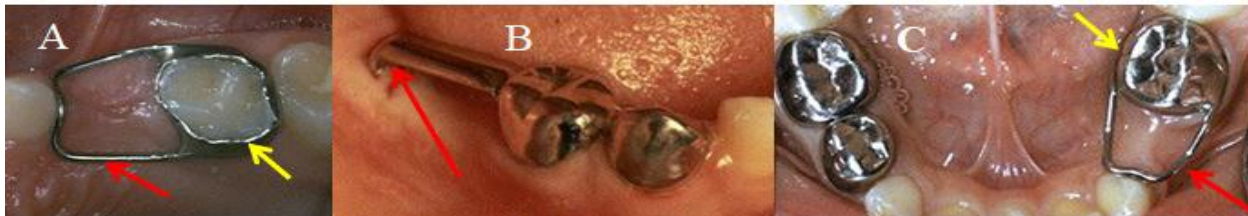**One-armed bandit:** It allows chairside fabrication and delivery. The band and half loop (occasionally referred to as a "one-armed bandit") is a premade appliance with a 0.036 wire that has already been soldered to the lingual surface of the band (Simon *et al.*, 2012). Once the correct band size has been selected, the wire is bent to contact the adjacent abutment tooth and cemented.

**Prefabricated band and loop:** The band and loop comes in two different pieces. Bands come in various sizes and include buccal and lingual tubes extending partially across the edentulous space. The wire attachments are designed to insert into the tubes and abut the tooth opposite the space. Once the proper size of band and wire is selected, the tubes can be crimped around the wires to finalize dimensions before delivery. DeNovo and Appliance Therapy Group companies carry this product (Wright and Kennedy, 1978). Bands and loops have been used since long as a space maintainer with good high success rates. In spite of good patient compliance, disintegration of cement, solder failure, caries formation along the margins of the band, embedding of wire into the gingival tissues and an inability to control for rotations or tipping of abutment teeth are the drawbacks (Baroni *et al.*, 1994; Rajab, 2002; Fathian *et al.*, 2007). Other disadvantages are the laboratory cost and the chair time for the two appointments associated with fabrication and delivery.

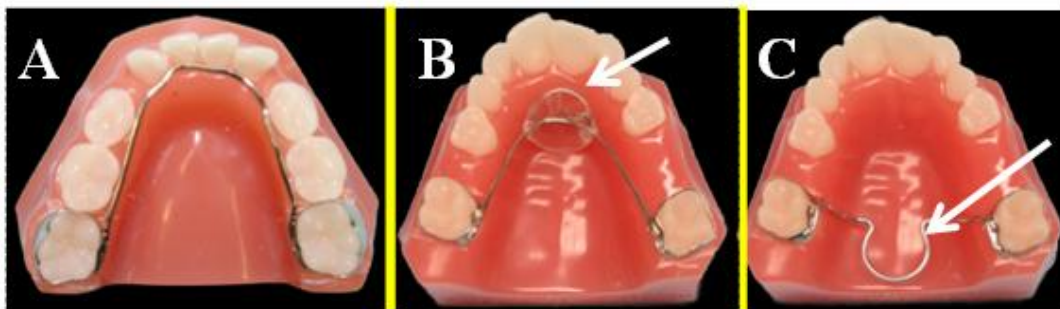
**Distal shoe space maintainer:** The distal shoe space maintainer, as introduced by Gerber in 1964 and extended by Croll, is a valuable part of the pediatric dentist's armamentarium (Croll and Sexton, 1981). It is indicated where the second primary molar is lost prematurely. Usually, mandibular permanent first molars have a mesio-occlusal eruption pattern, guided by the distal surface of the primary second molar. In the absence of the second primary molar, an unerupted first permanent molar may drift mesially within the alveolar bone before and during its eruption resulting in a loss of arch length and possible impaction of the second premolar its eruption resulting in a loss of arch length and possible impaction of the second premolar.



**Figure 1: Removable space maintainer: A. Unilateral Non-functional; B. Bilateral Non-functional; C. Unilateral Functional; D. Bilateral Functional**



**Figure 2: Fixed unilateral space maintainer: A. Band and Loop Space Maintainer. Yellow arrow indicates the band and red arrow indicates the loop. B. Distal Shoe Space Maintainer. Note that an extension segment (distal shoe) is soldered to the crown, where the segment is extended into the tissue against the unerupted first permanent molar, shown by red arrow. C. Crown and Loop Space Maintainer. Note that stainless steel wire is soldered to the stainless steel crown shown by yellow arrow and the wire is bent so that it is adapted closely to the tissue, shown by red arrow**



**Figure 3: Fixed Bilateral Space Maintainer: A. Lower Lingual Arch. Note that bands are placed on the permanent first molars and connected to stainless steel orthodontic wire extending along the lingual surfaces of the mandibular arch. B. Nance appliance. Note that a small acrylic button is embedded against the palatal tissue in the rugae region, shown by white arrow. C. Transpalatal Arch. Note that an omega loop is incorporated in the centre of the transpalatal bar (Goshgarian arch), shown by white arrow**

Thus, in absence of primary second molar, distal shoe space maintainer guides the first permanent molar into place and prevents mesial drifting of the tooth. It is a successful appliance in guiding unerupted permanent teeth into the arch. The indications and contraindications for the distal shoe appliance as well as the diagnostic and systemic considerations are outlined by Hicks in 1973 (Beena, 2011).

#### **Indications (Beena, 2011)**

- ) Premature loss or extraction of the second primary molar prior to the eruption of the first permanent molar
- ) Advanced root resorption and periapical bone destruction of the second primary molar prior to eruption of the first permanent molar
- ) A primary second molar with advanced caries that is not restorable
- ) Ectopic eruption of the permanent first molar
- ) Ankylosis of the primary second molar

#### **Contraindications (Beena, 2011)**

- ) Inadequate abutments due to multiple loss of teeth
- ) Poor patient or parental cooperation

- ) Missing permanent first molar
- ) Systemic diseases that affect healing such as diabetes mellitus
- ) Cardiac anomalies that require antibiotic prophylaxis prior to dental treatment
- ) Certain medical conditions such as blood dyscrasias, immune-suppression, congenital heart disease, history of rheumatic fever, generalized debilitation.

This appliance consists of a band or a stainless steel crown that is adapted to the primary first molar with a wire loop extending over the extraction space. There is an additional extension (of either wire or a metal guide plane) that extends subgingivally to contact the mesial surface of the unerupted permanent molar (Fig. 2 B). Without space maintenance, the permanent molar will drift mesially into the extraction space. Final adjustment in length and contour of the shoe in terms of its relationship with the unerupted first permanent molar may be made by radiographs before final placement of the space maintainer in the mouth. The depth of the intragingival extension should be about 1-1.5 mm below the mesial marginal ridge of the molar, or just sufficient to capture its mesial

surface as the tooth erupts and moves forward. After the molar has erupted, the intragingival extension is removed. If the appliance is to be used as a reverse band and loop space maintainer, it may be necessary to add a supra gingival extension to prevent the molar from tipping over the wire (Khanna *et al.*, 2015). The most important disadvantage of the distal shoe space maintainer is that subgingival extension involves continuous communication between the oral environment and the intra-alveolar space. Meticulous oral hygiene must be maintained (Foley *et al.*, 2002).

**Crown and loop space maintainers:** These crowns are used to restore carious primary molars where one or two surface carious lesions are extensive and if restoration is needed to last more than two years. These crowns are also indicated in restoration of fractured primary molars and in localized or generalized developmental problems e.g., enamel hypoplasia, amelogenesis imperfecta, and dentinogenesis imperfecta. In children, less than six years of age, stainless steel crowns are preferable to restorations. A stainless steel wire can be soldered to the crown and it can be used as a crown and loop space maintainer (Fig. 2 C).

### Fixed Bilateral Space Maintainers

#### Lingual Arch

A lingual arch is an orthodontic device which connects two molars in the upper or lower dental arch. Lingual arch space maintainer is a good preventive measure, as it helps in maintaining the arch perimeter by preventing both the mesial drifting of the molar teeth and also lingual collapse of the anterior teeth. Thus, they block off the eruption space for the premolar teeth.

#### Lower Lingual Arch

The lower lingual arch has an archwire adapted to the lingual side of the lower teeth. This is the most effective appliance for space maintenance in the mandibular arch. It is the only passive bilateral space maintenance appliance for the lower lingual holding arch.

This appliance consists of two bands, typically placed on the permanent first molars or sometimes second deciduous molar. These are connected to stainless steel orthodontic wire extending along the lingual surfaces of the mandibular arch. The wire can be soldered to the bands or inserted into lingual sheaths welded to the molar band (Rani, 2014) (Fig. 3 A). The appliance is cemented and remained in use until all the permanent teeth have erupted (Jitesh and Mathew, 2019).

#### Advantages (Rani, 2014; Jitesh and Mathew, 2019)

- )] Indicated in case of multiple missing teeth
- )] Allows free individual movement of teeth
- )] Less likely to interfere with the typical increase in intercanine distance that takes place as a child transitions from mixed to permanent dentition.
- )] Excellent source of anchorage
  - )] It also has the capacity to relieve potential crowding by allowing incisors to drift distally into the Leeway space as it resists mesial movement of the permanent first molars (Rani, 2014).

#### Disadvantages (Rani, 2014)

- )] Prolong use of the bands may cause decalcification of the tooth
- )] If placed before the loss of the primary incisors, the lingual wire may interfere with the eruption of the permanent incisors, which typically migrate facially from a lingual position during development.
- )] The lower lingual holding arch might cause proclination of the lower incisors, so it is suggested to avoid contact of the lingual arch with the mandibular incisors.
- )] The lower lingual arch is also used in order to maintain the so-called "Leeway space", which is the extra space available in the arch when the deciduous molars are exfoliated and replaced by smaller permanent premolars (Brennan and Gianelly, 2000). Preservation of Leeway space may increase the prevalence of second molar impactions.

### MAXILLARY BILATERAL SPACE MAINTAINER

There are two options if a fixed bilateral space maintainer is indicated in the maxillary arch:

- )] Nance appliance
- )] Transpalatal Arch

**Nance Appliance:** This is the most commonly used maxillary appliance. The appliance consists of a 0.032 or 0.036 stainless steel wire which is soldered to the lingual surface of the two molar bands and extends to the anterior palate where an acrylic button is embedded which contacts the palatal tissue that provides greater resistance to the mesial movement of the posterior (abutment) teeth (Fig. 3 B) (Jitesh and Mathew, 2019). However, the acrylic button interfere the oral hygiene measures and can lead to overgrowth of the surrounding tissues due to constant irritation (Rani, 2014).

#### Indications

- )] Used in maintaining the position of maxillary 1st permanent molars when there is bilateral premature loss of primary teeth, with no loss of arch space and a favourable mixed dentition analysis.
- )] Presence of deleterious habits like tongue thrusting along with premature tooth loss, where it can be used as habit-breaking appliance to break the habits.

**Transpalatal Arch:** Transpalatal arch was originally described by Robert Goshgarian in 1972 and is named after his name as the Goshgarian arch. It could possibly be used for the maintenance of the transverse arch widths, anchorage in extraction case, prevent buccal tipping of molars during Burstonian segmented arch mechanics, transverse anchorage and space maintenance. Resistance to the mesial movement of the permanent first molars comes through cross-arch stabilization between the two abutment molars and through contact with the lingual surfaces of the mandibular incisors (Jitesh and Mathew, 2019). It is not as common as the Nance appliance due to concerns about its efficiency. (Para changed pl) Bands are placed on the permanent first or primary second molars with a 0.032 or 0.036 stainless steel wire passing through the palatal vault between the two abutment teeth. The wire may extend straight across or it may incorporate an omega loop in the centre (Fig. 3 C). The wire should have no soft tissue contact and generally sits 3-5 mm from the soft tissue surfaces.

### Indications (Rani, 2014)

- ) When primary molars are lost bilaterally or when one side of the arch is intact, and several primary teeth on the other side are missing
- ) Used in maintaining the position of maxillary 1<sup>st</sup> permanent molars when there is bilateral premature loss of primary teeth, with no loss of arch space with a favourable mixed dentition analysis.

### Advantage of Transpalatal Arch

- ) Less food impaction and plaque retention as well as improved soft tissue compatibility compared to that of Nance appliance.
- ) Orthodontic benefits by providing some resistance to molar extrusion and allowing orthodontic tooth movement, mild dental expansion, derotation, and some torque (Foley *et al.*, 2002)

For a passive use, lower lingual arch and transpalatal arch are usually made out of stainless steel with a 0.032" cross section. A beta-titanium wire is more effective if they are to be activated to expand or reduce the intermolar distance and to rotate the molars (Active Use) (Brennan and Gianelly, 2000). In this way, it is possible to reshape the whole dental arch by connecting the molars to the other teeth using a buccal arch wire.

### CONCLUSION

The primary dentition plays a very significant role in the child's growth and development. The primary teeth not only help in speech, chewing and appearance but also guide the eruption of permanent teeth. The best space maintainer is a well maintained primary tooth. If these important natural space maintainers are lost before their stipulated time, it is essential to implement a space management therapy, which will protect a child from future malocclusions, in terms of esthetic and functional disfigurement.

### REFERENCES

Barberia, E., Lucavechi, T. 2006. Free end Space Maintainers: Design Utilisation and Advantages. *J Clin Pediatr Dent.* 31:5 - 8.

Baroni, C., Franchini, A., Rimondini, L. 1994. Survival of different types of space maintainers. *Pediatr Dent.* 16:360-361

Beena, JP. 2011. Distal Shoe, an Effective Space Maintainer for Premature Loss of Primary Mandibular Second Molar - A Case Report. *Int J Clin Prev Dent.* 7:209-212.

Brennan, MM., Gianelly, AA. 2000. The use of the lingual arch in the mixed dentition to resolve incisor crowding. *Am J Orthod Dentofacial Orthop.* 117: 81- 85.

Brothwell, DJ. 1997. Guidelines on the use of space maintainers following premature loss of primary teeth. *J Can Dent Assoc.* 63:753- 766.

Chawla, HS.,Kaur, P., Shamsudheen, M. 1985. Modified Space Maintainer. *J Indian SocPedodPrev Dent.* 3:48 - 49.

Choonara, SA. 2005. Orthodontic space maintenance: a review of current concepts and methods. *SADJ.* 60: 115-117.

Croll, TP., Sexton, TC. 1981. Distal extension space maintenance: a new technique. *Quintessence Int. Dent Digest.* 12:1075-1080.

Davenport, IB. 1887. The significance of the natural form and arrangement of the dental arches of man, with a consideration of the changes which occur as a result of their artificial derangement by filling or by the extraction of teeth. *Dent Cosmos.* 29:413- 439.

Dean, JA. 2011. McDonald & Averys: Dentistry for the child & adolescent. 8<sup>th</sup> ed. Reed Elsevier India Pvt. Ltd., India.

Fathian, M., Kennedy, DB., Nouri, MR. 2007. Laboratory made space maintainers a 7 years retrospective study from private pediatric dental practice. *Pediatr dentistry.* 29:500-506.

Foley, T., Aggarwal, M., Hatibovic-Kofman, S. 2002. A comparison of *in vitro* enamel demineralization potential of 3 orthodontic cements. *Am J Orthod Dentofacial Orthop.* 121:526-530.

Jitesh, S., Mathew, MG. 2019. Space maintainer-A review. *Drug invention today.* 11 (Spl issue): 21-25.

Khanna, P., Sunda, S., Mittal, S. 2015. Keep My Space- A Review Article. *International Journal of Oral Health Dentistry.* 1:11-15

Kisling, E., Hoffding, J. 1979. Premature loss of primary teeth--after loss of adjoining teeth. *J Dent Child.* 46:34-38.

Nayak, UA.,Loius, J., Sajveer, R., Peter, J. 2004. Band and loop space maintainer--made easy. *J Indian Soc Ped Prev Dent.* 22:134-136

Rajab, LD. 2002. Clinical performance and survival of space maintainers: Evaluation over a period of 5 years. *J Dent Child.* 69:156-160.

Rani M.S. 2014. Textbook of orthodontics. Revised 3<sup>rd</sup> edition. AITBS publishers, India.

Rao, AK., Sarkar, S. 1999. Changes in arch length following premature loss of deciduous molars. *J Indian Soc Pedo Prev Dent.* 17:29-32.

Setia,V., Pandit, IK., Srivastava, N., Gugnani, N., Sekhon, HK. 2013. Space maintainers in dentistry: Past to present. *J Clin Diagn Res.* 7: 2402–2405.

Simon, T., Nwabueze, I., Oueis, H., Stenger, J. 2012. Space maintenance in the primary and mixed dentitions. *J Mich Dent Assoc.* 94:38-40.

Wright, CZ., Kennedy, DB. 1978. Space control in the primary and mixed dentitions. *Dent Clin North Am.* 22:579 - 601

\*\*\*\*\*