



ISSN: 0975-833X

Available online at <http://www.journalera.com>

International Journal of Current Research
Vol. 13, Issue, 01, pp.16027-16030, January, 2021

DOI: <https://doi.org/10.24941/ijcr.40621.01.2021>

INTERNATIONAL JOURNAL
OF CURRENT RESEARCH

RESEARCH ARTICLE

OESOPHAGOGASTRECTOMY WITH JEJUNE INTERPOSITION IN A PATIENT WITH ACHALASIA. A CASE REPORT AND LITERATURE REVIEW

Efstathios K. Metaxas,^{1,*} Nikolaos Soupos,² Theodoros Margioliis, ³AntoniosKatsipoulakis,⁴ DimitriosTsitsimelis, ⁵ Nikolaos Anastasiou⁶

¹Department of Thoracic Surgery, General Hospital of Nicaea –Piraeus Greece

²Oncology Department, Oncological Hospital of Kifisia – Agioi Anargiroi, Athens Greece

³Department of General Surgery Oncological Hospital of Kifisia – Agioi Anargiroi, Athens Greece

⁴Anaesthesiology Department, Oncological Hospital of Kifisia – Agioi Anargiroi, Athens Greece

⁵Radiology and Imaging Department, Oncological Hospital of Kifisia-Agioi Anargyroi, Athens Greece

⁶Department of Thoracic Surgery, Oncological Hospital of Kifisia – Agioi Anargiroi, Athens Greece

ARTICLE INFO

Article History:

Received 14th October, 2020

Received in revised form

25th November, 2020

Accepted 10th December, 2020

Published online 30th January, 2021

ABSTRACT

It is about a 77 year old patient diagnosed initially with achalasia of the oesophagus, and finally with adenocarcinoma of the stomach grade III. He underwent successfully Oesophagogastrectomy with jejunum interposition on achalasia oesophagus. Analyze strategy of treatment operative technique and literature review.

Key Words:

Achalasia, Gastroesophagean Cancer,
Jejunum Interposition.

Copyright © 2021, Efstathios K. Metaxas et al. This is an open access article distributed under the Creative Commons Attribution License, which permits unrestricted use, distribution, and reproduction in any medium, provided the original work is properly cited.

Citation: Efstathios K. Metaxas, Nikolaos Soupos, Theodoros Margioliis, Antonios Katsipoulakis, Dimitrios Tsitsimelis, Nikolaos Anastasiou. 2021. "Oesophagogastrectomy with jejunum interposition in a patient with achalasia. a case report and literature review", *International Journal of Current Research*, 13, (01), 16027-16030.

INTRODUCTION

The oesophagus with achalasia is no peristaltic and the Jejunum does.¹ In case of anastomosis this is quite difficult, otherwise is a challenge for surgery.

Description of the case in chronological order: PMH of the patient with not known drug allergies. He used to smoke for 30 years 2 packs per day but he cut it the last 20 years. He underwent appendectomy 1965, cholecystectomy 2013. Hypertension well controlled under Triatec 25mg once a day, Lopressor 50mg x 2, Salospir 100mg x1. Hypercholesterolemia well controlled under Atorvastatin 20mg x1. COPD under medication and achalasia of the oesophagus since 2003. The oesophagoscopy revealed presence of food in huge quantity. The sphincter was measured at 39cm with stenosis. The gastroscopy demonstrated intense inflammation, oedematous and atrophy.

*Corresponding author: Efstathios K. Metaxas,
Department of Thoracic Surgery, General Hospital of Nicaea – Piraeus Greece.

Achalasia and Chronic gastritis Biopsies taken. The Histopathology report showed adenocarcinoma. The case was discussed at the MDT meeting, according to the protocol and patient received preoperative Neo adjuvant chemotherapy.

Operation technique: Left thoracoabdominal incision. Mobilization of oesophagus above aortic arch to Hiatus. Open diaphragm and preserved phrenic nerve. Mobilization of the stomach. Subcarinal and Celiac nodes excised. Inferior ligament node (station nr9) was removed. The lower part of the oesophagus was cut approx 3cm and stomach longitudinal 28cm. Resection of the Oesophagus completed. Hepatoduodenal ligament nodes (4) excised. Mobilization of the Jejunum (8,5cm intestine was cut, mucosal was checked macroscopically with no pathology) and transposition anatomical to the chest through Hiatus. End to side anastomosis was performed with EndoGIA Reticulator. Oesophagogastrectomy with jejunum position to Hiatus, interposition in a patient with achalasia was successfully done. Patient was extubated in the operation theatre and was transferred to the ward.

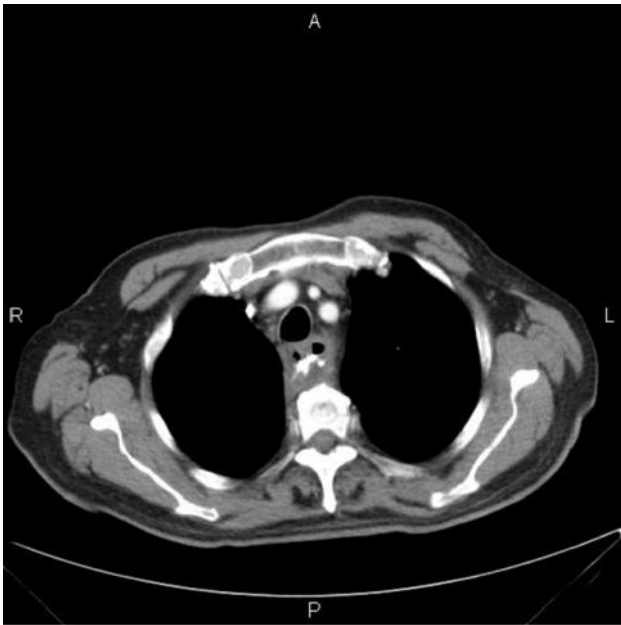


Image 1. Post procedure CT

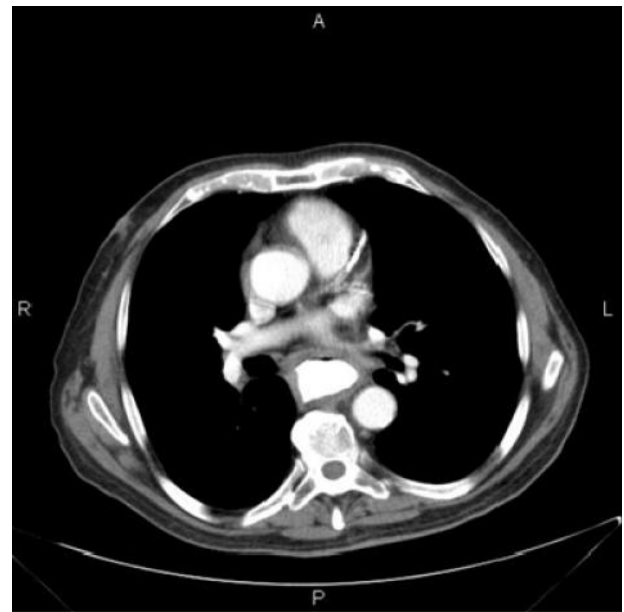

Image 3. Post procedure CT

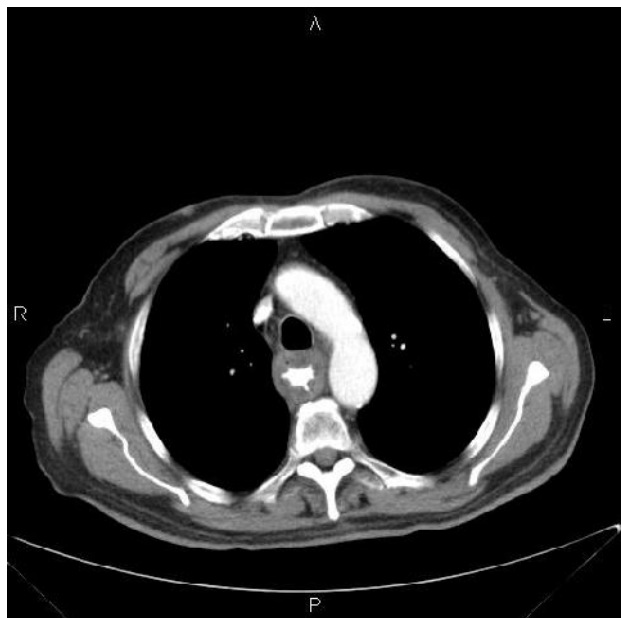


Image 2. Post procedure CT

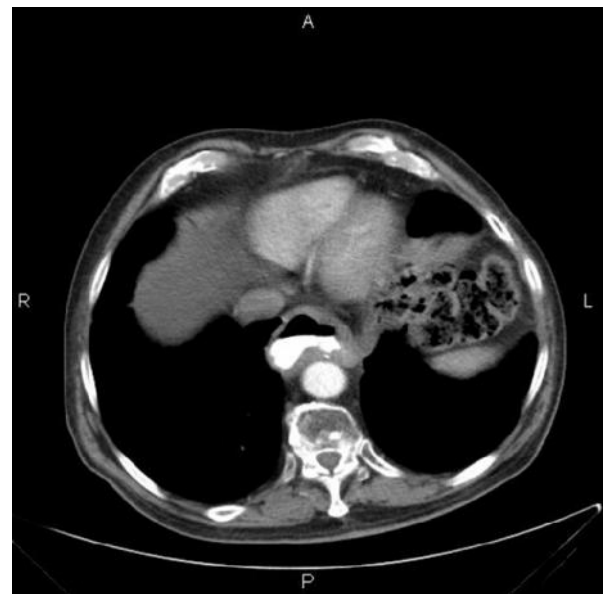


Image 4. Post procedure CT

Parenteral nutrition started immediately post procedure. Nutrition tube (NG Tube) was removed 48 h post procedure and oral intake was started according our protocol. The fifth post operative day patient underwent gastrografin swallow –no liquids found. On 12th postoperative day patient underwent CT chest abdomen with gastrografin. The anastomosis was intact so TPN was stopped and started feed with semi liquids. He had a good postoperative recovery and finally was discharge the 15th post operative day. Patient underwent successfully and uncomplicated chemotherapy and Radiotherapy. At the regular follow up he still asymptomatic and with no disease, three years post surgery.

DISCUSSION

Achalasia is a heterogeneous disease with abnormal contractility of the oesophagus.¹ Dysphagia to solids and liquids, regurgitation and chest pain are typical symptoms. Weight loss is present in many, but not all patients.

The diagnosis is based on history taken – anamnesis, on oesophageal motility testing, oesophagogastrroduodenoscopy and barium swallow. Achalasia may be caused by a loss of nerve cells in the esophagus. Also viral infection or autoimmune responses, an inherited genetic disorder or infection, there are theories suspected by researchers.

Manometrically can be categorized in 3 types.

-) **Type I** (classic) with minimal contractility in the esophageal body,
-) **Type II** with intermittent periods of pan esophageal pressurization,
-) **Type III** (spastic) with premature or spastic distal esophageal contractions

Radiological can be divided into stages where

-) Early **achalasia** (esophageal diameter <4 cm)
-) Moderate **achalasia** (esophageal diameter 4–6 cm),
-) Severe **achalasia** (esophageal diameter >6 cm) are present with their respective symptom patterns.

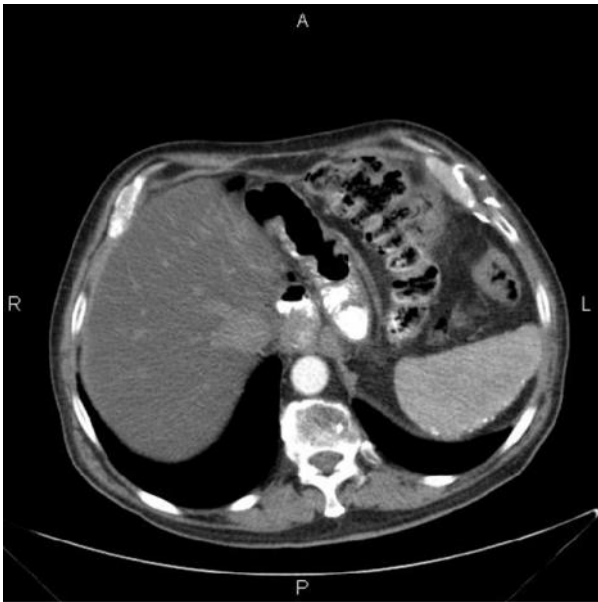

Image 5. Post procedure CT

Diagnostic procedures like oesophageal manometry, Oesophagram and upper endoscopy are very helpful.

- J) **Oesophageal manometry.** This test measures the rhythmic muscle oesophageal contractions when swallow, is the most helpful because determining the type of motility problem. High-resolution manometry has now identified three subtypes of achalasia, with therapeutic implications.
- J) **Oesophagram.** X-rays of the upper digestive system with contrast. Allows to see a silhouette of the oesophagus, stomach and upper intestine.
- J) **Upper endoscopy.** Can be used to define a partial blockage of the oesophagus if symptoms or results of a barium study indicated. Can be used also to collect a sample of tissue (biopsy) to be tested for complications of reflux such as Barrett's oesophagus.

Current medical (pharmacological agents) and surgical therapeutic options like pneumatic dilation, endoscopic surgical myotomy aim at reducing the LES pressure and facilitating oesophageal emptying by gravity and hydrostatic pressure of retained food and liquids. Surgery considered definitive treatment and laparoscopic surgical myotomy with a partial fundoplication is highly recommended. Botulinum toxin injection into the lower oesophageal sphincter should be reserved for those who cannot undergo definitive therapy. The prognosis in achalasia patients is excellent. Most patients who are appropriately treated have a normal life expectancy but the disease does recur and the patient may need intermittent treatment. So, close follow-up is highly recommended. Patients with achalasia require repeated invasive therapies and may experience multiple complications.¹

Life expectancy, complications, and causes of death in patients with achalasia: results of a 33-year follow-up investigation analyzed by Volker F Eckardt et al. The population study 253 patients consisted of two groups. Group A comprised 177 patients with newly diagnosed achalasia; group B consisted of 76 patients in whom the diagnosis had been established in external institutions. The observation period for group A ranged from 2 to 33 years and for group B from 2 to 26 years (disease duration: 4-68 years).

The most frequent complications were reflux esophagitis (group A: 6.2%, group B: 19.7%) and megaesophagus (group A: 6.2%, group B: 21.0%). Finally patients with achalasia experience a significant number of complications. Causes of death and life expectancy, however, do not differ from those of the average population.

Does Achalasia predispose to cancer of the oesophagus? The answer of this question was given by Aggestrup et al.³ In a follow-up study of 147 patients with achalasia of the esophagus treated by myotomy, 146 patients were traced (58 female and 88 male patients aged 4 to 83 years; median 46 years). The living persons were contacted in writing or by telephone. The mean follow-up time after the operation was 23.2 years (range, six to 41 years). The cause of death was established for 71 patients. There were three postoperative deaths and two deaths following recurrence. In comparison with the Danish population, the 66 remaining patients were found to have a relatively higher cancer mortality (34.9% percent). Contrary to the expected less than one, ten of 23 patients who died of cancer had a malignant tumor in the esophagus. The mortality rate after 30 years was 66.1 percent, 11.9 percent of the deaths caused by esophageal cancer.

In conclusion there is a connection between achalasia and oesophageal cancer.⁴ Surgery for achalasia by Just-Viera et al, improves symptoms. Long term follow up (endoscopy and biopsies) considered absolute necessary for detection of malignancy in early stage because cancer of the oesophagus still arises many years later.⁴ Long term outcome and risk of esophageal cancer after surgery for achalasia was analyzed by Zaninotto et al.⁵ The study was focused to identify if there is oesophageal cancer in long term patients underwent myotomy and partial fundoplication for achalasia. Between the years 1980 and 1992 checked 228 patients traced 182 of 184 survivors and the cause of death was found in 41 of 42 patients. At a median follow-up of 18.3 years, almost 90 per cent of patients were satisfied with the treatment. Four had developed squamous cell oesophageal carcinoma 2, 8, 13 and 18 years after surgery, one of whom was still alive. The standardized mortality ratio for oesophageal carcinoma was significantly higher than expected in men. In conclusion Cardiomyotomy and partial fundoplication is an excellent long-term treatment for achalasia.^{5,6} Men with achalasia have an increased risk of developing oesophageal cancer.^{5,6}

Conclusion

Achalasia is a heterogeneous disease with abnormal contractility of the oesophagus. Dysphagia to solids and liquids, regurgitation and chest pain are typical symptoms. Diagnostic procedures like oesophageal manometry, Oesophagram and upper endoscopy are very helpful. Cardiomyotomy and partial fundoplication is an excellent long-term treatment for achalasia. Long term follow up (endoscopy and biopsies) considered absolute necessary for detection of malignancy in early stage because cancer of the oesophagus still arises many years later. So patients with achalasia have an increased risk of developing oesophageal cancer. Oesophagogastrectomy with jejune interposition on achalasia oesophagus considered as challenge surgery (achalasia is no peristaltic and the Jejunum does). Experience team required.

REFERENCES

1. Volker F Eckardt, Tom Hoischen, Gudrun Bernhard. Life expectancy, complications, and causes of death in patients with achalasia: results of a 33-year follow-up investigation. *Eur J Gastroenterol Hepatol.* 2008 Oct;20(10):956-60.
2. Ates F, Vaezi MF. Gut. The Pathogenesis and Management of Achalasia: Current status and Future Directions. *Gut Liver.* 2015 Jul;9(4):449-63.
3. Aggestrup S, Holm JC, Sørensen HR. Does achalasia predispose to cancer of the esophagus ? *Ugeskr Laeger*1994 Jan 31;156(5):637-9. PMID: 8184495 Danish.
4. Just-Viera JO, Haight C. Achalasia and carcinoma of the esophagus. *Surg Gynecol Obstet.* 1969 May;128(5):1081-95.
5. Zaninotto G, Rizzetto C, Zambon P et al. Long term outcome and risk of esophageal cancer after surgery for achalasia. *Br J Surg.* 2008 Dec;95(12):1488-94
6. Ota M, Narumiya K, Kudo K, Yagawa Y et all. Incidence of esophageal carcinomas after surgery for achalasia: Usefulness of long – term and periodic follow-up. *Am J Case Rep.* 2016 Nov 14;17:845-849.
