



ISSN: 0975-833X

## CASE STUDY

### PENICILLIUM MARNEFFEI CAUSING ONYCHOMYCOSIS: 2 RARE CASE REPORTS

\*Dr. Sangeeta Das Ghosh, Dr. MandiraChakraborty, Dr. AbhisekMitra and Dr. Indrani  
Bhattacharyya

Calcutta School of Tropical Medicine, Department of Microbiology, India

#### ARTICLE INFO

##### Article History:

Received 10<sup>th</sup> March, 2015  
Received in revised form  
17<sup>th</sup> April, 2015  
Accepted 25<sup>th</sup> May, 2015  
Published online 27<sup>th</sup> June, 2015

##### Key words:

Onychomycosis,  
Immunocompetent,  
*Penicilliummarneffeii*,  
Ketoconazole

#### ABSTRACT

Onychomycosis caused by nondermatophyte molds are rare. Here we are reporting 2 cases of onychomycosis in apparently immunocompetent individuals, caused by *Penicillium marneffeii* –the fungus which is generally considered either as a contaminant or an opportunistic pathogen capable of producing disease only in immunocompromised individuals. Previous therapy with Griseofulvin, assuming that the infection might be due to one of the members of dermatophytes, was proved to be unsuccessful and after initiation of Ketoconazole therapy gradual recovery occurred both clinically and microbiologically.

Copyright © 2015 Dr. Sangeeta Das Ghosh et al. This is an open access article distributed under the Creative Commons Attribution License, which permits unrestricted use, distribution, and reproduction in any medium, provided the original work is properly cited.

**Citation:** Dr. Sangeeta Das Ghosh, Dr. MandiraChakraborty, Dr. AbhisekMitra and Dr. Indrani Bhattacharyya, 2015, "Penicillium marneffeii causing onychomycosis: 2 rare case reports", *International Journal of Current Research*, 7, (6), 17040-17042.

## INTRODUCTION

Onychomycosis is traditionally referred to non-dermatophytic infection of nail but now used as general term to denote all fungal infection of nail. The term onychomycosis is derived from the Greek word *onyx*–nail and *mykes*–fungus. (JagdishChander). The etiological agents are dermatophytes, candida and rarely moulds. Among the moulds *Aspergillus* species, *Fusarium* species, *Hendersenulatarulesidea*, *Scapularlosisbravicaulisetc* have been reported as causative organisms of onychomycosis but only few case reports are there depicting *Penicillium marneffeii* as the causative agent and that also in immunocompetent individuals. *Penicillium marneffeii* has attained more prominence during last decade of 20<sup>th</sup> century when it was isolated as a progressive, disseminated and potentially fatal fungal infection in advanced stages of HIV infection. (Mudita Gupta, NandLal Sharma) Here we are reporting 2 cases of onychomycosis, caused by red pigment producing strain of penicillium- *Penicillium marneffeii*, in patients with no apparent immunosuppression.

\*Corresponding author: Dr. Sangeeta Das Ghosh,  
Calcutta School of Tropical Medicine, Department of Microbiology,  
India.

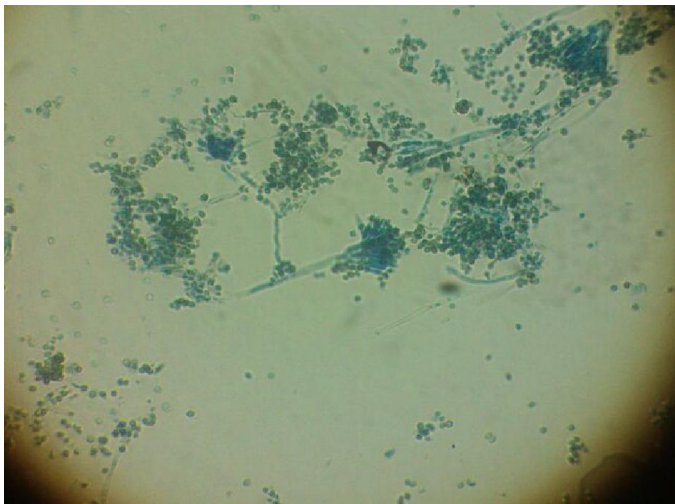
## CASE REPORTS

### CASE 1

A 40-year-old male, farmer presented with dystrophy of finger nails affecting index and ring fingers of right hand for last 6 months. He is Non HIV and nondiabetic. All systemic examinations are within normal limits. There was no localised pain at the affected site. On examination, the right finger nails were lustreless and dystrophied. The distal part of the nail appeared soft, black coloured with irregular margin. He was treated with Griseofulvin for 2-3 months for the nail infection without any improvement. Samples of the nails were examined three times in 40% KOH preparation and cultured on slopes containing (a) Sabouraud's dextrose agar (SDA) incorporating cycloheximide 0.05 mg/ml and chloramphenicol 0.5 mg/ml and (b) Sabouraud's dextrose agar incorporating chloramphenicol 0.05 mg/ml only and incubated at room temperature 24 degree C. Nail specimens on three occasions showed fungal elements in KOHpreparation. Within 2 days of time greyish-white colonies grew on SDA which subsequently became granular in texture and yellow orange in centre. The periphery of the colony was purple orange with radial folds. After 6 days the reverse characteristically became bright red coloured. On LCB preparation it was identified as the mycelia of *Penicillium sp.*



Culture tube of *P.marneffii*



*P.marneffii* LCB findings

After inoculation of the fungus further on SDA, it was incubated at 37 degree C, for 7 days. The LCB mount of the growth demonstrated pleomorphic rectangular yeast like cells with transverse septa and without budding. Only one *Penicillium sp* is having this characteristic features of dimorphism-*Penicillium marneffei*. As there was no response to Griseofulvin, he was treated with oral Ketoconazole (200 mg twice daily) for 4 months resulting in both clinical and microbiological improvement.

### Case 2

A 34 year male slum dweller presented with dystrophic finger nails of left hand of 1 year duration. He was nondiabetic and HIV -. All systemic examinations are within normal limits. No complain of pain was there. He had not given any history of trauma preceding infection. He had undergone same

investigations as of case 1 and ultimately diagnosed as having *p. marneffei* infection of nail. The treatment was shifted from Griseofulvin to Ketoconazole with clinical and microbiological improvement. Both the patients are on treatment at present showing gradual but steady recovery.

### DISCUSSION

Moulds causing nail infection are rare. Moulds are opportunistic and frequently invade altered keratin, particularly that of the big toe. (R Ramani, A Ramani) In our cases, *Penicillium marneffei* was isolated from finger nails of two patients who had no apparent immunosuppression, which is quite a rare finding as it is an AIDS defining illness and the 3<sup>rd</sup> most frequent opportunistic pathogen after tuberculosis and cryptococcosis in HIV infected patients in endemic areas. So, in epidemiological point of view, some definite immunosuppression is needed for paving the way of this mould, which is absent in these cases. Under such circumstances, diagnostic dilemma may arise whether to interpret the finding as merely a contaminant of fungal culture or as a true pathogen? After verifying several aspects, we considered the fungus not only a true pathogen but as *Penicillium marneffei*.

Convincing evidence includes a) direct microscopic examination of nail samples showing hyphae, b) repeated isolation of *Pencillium* specie on culture c) absence of dermatophytes from the nail samples d) appearance of characteristic red pigment on culture on SDA at 24 degree C e) growth of yeast like forms after 7 days of incubation at 37 degree C on SDA confirming the dimorphic nature of this fungus and distinguishing it from other red pigment producing *Penicillium sp* like *Penicillium rubrum*, *enicillium purpurogenum*, *Penicillium janthinellum* and *Penicillium citrinum*-as none other species of penicillium except penicillium marneffei are dimorphic in nature. (JagdishChander) f) LCB mount and Giemsa stain of the growth of this fungus at 37 degree C clearly shows yeast like forms with transverse fission and prominent central septum instead of budding\_ further confirming it to be *penicillium marneffei* as this fungus characteristically reproduce by fission process instead of budding.

In this fungus following nuclear division cell divides by fission to form 2 uninucleate cells. These newly formed cells can again propagate by fission. Consequently the culture consists of entirely yeast like cells. *Pencillium* species have been found as soil saprophytes, and our patients being farmer and slum dwellers, had probably acquired the infection from soil. One of them had also given the history of trauma few weeks preceding the infection, which might have facilitated the fungus to invade nails.

Griseofulvin in adequate amounts results in cure of onychomycosis, but *Penicillium sp* are not susceptible to griseofulvin. (JagdishChander) Hence Ketoconazole was used and found to be successful. Here comes the clinical importance of this fungus. Prescribing griseofulvin just after diagnosis of onychomycosis, without acquiring sufficient microbiological data regarding the causative fungal agent, may lead to

deleterious effect on treatment outcome. The most grave consequences of such injudicious prescriptions are – unnecessary exposure of the patient to antifungals having potential side effects and emergence of resistant fungal strains. So a thorough microbiological investigation is needed to exclude any unusual pathogen causing onychomycosis.

### **Conclusion**

As the organism usually causes severe systemic disease in immunocompromised individuals – in our cases the limitation of infection to nails can probably be attributed to the factors that in both the cases patients are immunocompetent preventing the systemic spread of this fungus. However, there is an urgent need to intensify the worldwide awareness programme to deal with this emerging fungal disease.

### **REFERENCES**

- Department of Dermatology, Venereology and Leprosy, Indira Gandhi Medical College, Shimla *Indian Journal of Dermatology, Venereology and Leprology, Vol. 73, No. 6, November-December, 2007, pp. 389-392*
- Mudita Gupta, NandLal Sharma, Anil K. Kanga, Vikram K. Mahajan, Gita Ram Tegta
- Onychomycosis: Clinico-mycologic study of 130 patients from Himachal Pradesh, India
- Penicillium species causing onychomycosis.
- Ramani, R., Ramani, A. and Shivananda, P.G. Dept of Microbiology, Kasturba Medical College, Manipal, Karnataka., Year : 1994 | Volume : 40 | Issue : 2 | Page: 87-8
- Textbook of Medical Microbiology 3<sup>rd</sup> edition by Jagdish Chander page 329.

\*\*\*\*\*