



ISSN: 0975-833X

## REVIEW ARTICLE

### ETIOLOGY AND PRECLUSION OF CHLORODONTIA (GREEN TEETH)

<sup>1</sup>Therraddi Muthu, R. M., <sup>2</sup> Sumathi, C. and <sup>3\*</sup>Jayantha Padmanabhan

<sup>1</sup>Department of Oral Pathology, Asan Memorial Dental College and Hospitals, Chengalpet, Tamil Nadu, India

<sup>2</sup>Department of Pharmacology, Asan Memorial Dental College and Hospitals, Chengalpet, Tamil Nadu, India

<sup>3\*</sup>Department of Periodontics, Asan Memorial Dental College and Hospitals, Chengalpet, Tamil Nadu, India

#### ARTICLE INFO

##### Article History:

Received 25<sup>th</sup> March, 2015

Received in revised form

07<sup>th</sup> April, 2015

Accepted 05<sup>th</sup> May, 2015

Published online 27<sup>th</sup> June, 2015

##### Key words:

Green teeth  
Hypenilirubinemia,  
Chromogenic bacteria,  
Metals,  
Drugs.

#### ABSTRACT

**Objectives:** The present review explores the multifactorial etiologies of Chlorodontia (Green teeth) and aims to create awareness among dentists and dental hygienist who deal with the patient directly on use of safe medicine to prevent green discoloration of teeth.

**Materials and Methods:** Data has been collected from various sources which include review and research articles published in reputed journals, (pubmed, google scholar, scopus etc) web pages and books to accomplish meaningful solutions through different treatment strategies.

**Results:** Various factors involved in green discoloration were analyzed and the appropriate management strategies have been discussed. Tooth discoloration is usually aesthetically displeasing and psychologically traumatizing which can erode the sparkle from a smile. Green teeth is an uncommon condition that is associated with bilirubin deposits, degraded products of hemoglobin and elements like calcium, sodium, magnesium, phosphorous potassium etc in dental hard tissues and the side effects of immunosuppressive drugs in patients with a liver transplant. Discoloration is mainly observed in primary dentition. Treatment of green discoloration based on the etiology has been goal to our study. This paper will be dual beneficiary as green discoloration can be prevented in patient as well will be useful for dentist to initiate the proper therapy.

Copyright © 2015 Therraddi Muthu et al.. This is an open access article distributed under the Creative Commons Attribution License, which permits unrestricted use, distribution, and reproduction in any medium, provided the original work is properly cited.

**Citation:** Therraddi Muthu R. M., Sumathi, C. and Jayantha Padmanabhan, 2015. "Etiology and preclusion of Chlorodontia (Green teeth)", *International Journal of Current Research*, 7, (6), 17054-17062.

## INTRODUCTION

The science of color is pivotal in dentistry as color perception is of great concern to a large number of people seeking dental treatment (1). The prominent layers in tooth are the enamel which covers the crown, the root cementum on the root surface and an inner layer of dentin in the crown and the root (2). The pulp, the inner part of the tooth is enriched with blood supply and nerve supply. Teeth are most susceptible to developmental disturbances during the mineralization phase of tooth formation (3). The permanent dentition is more prone to disturbances in mineralization by chemicals and drugs (4). Alterations in these structures will result in the modification of tooth appearance externally as well as its light transmitting and reflecting properties (5).

### Etiology of Tooth Discoloration

Discoloration of the tooth is one of the most frequent reasons why patients hunt for dental care. Tooth discoloration is aesthetically displeasing and psychologically traumatizing.

**\*Corresponding author: Jayantha Padmanabhan,**  
Department of Periodontics, Asan Memorial Dental College and Hospitals, Chengalpet, Tamil Nadu, India.

An understanding of the etiology of tooth discoloration is important to a dentist in order to make the accurate diagnosis. The discolorations are mainly observed on the outer surface of the tooth structure mainly caused due to the stains taken up by the enamel or dentin during tooth development (6). The developmental defects create their own color change in the tooth caused by influences on light transmission through the dentine and enamel. Furthermore, increased enamel porosity and enamel defects (dentinogenesis imperfecta) facilitate the penetration of the stains (Chromogens) through the tubular system (7). Hence, identification of the type and extent of discoloration play a key role as intervention of dentist is a must to resolve this cosmetically unsatisfactory dentition.

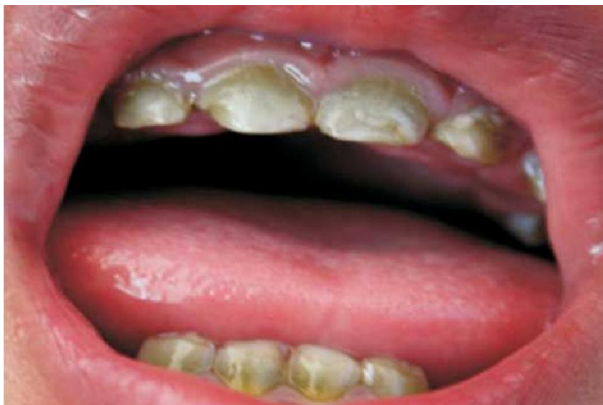### Classification of Tooth discoloration

Historically, tooth discoloration has been classified as either intrinsic or extrinsic based on the location of the stain. Internalized discoloration also is of value to consider (8). Extrinsic discoloration may be due to direct or indirect staining (9). Direct staining occurs due to penetration of chromogens into the acquired pellicle and indirect staining are the consequence of chemical reaction with metals or cations used as antiseptic (5). Nevertheless, the deposition of anionic

chromogens onto adsorbed cations is another factor that contributes to external pigmentation of the teeth (10). Conversely, the intrinsic discoloration occurs following a change to the structural composition or thickness of the dental hard tissues. Systemic diseases play a pivotal role in the development of dentition and may lead to discoloration. The causative factors of discoloration within enamel includes caries; idiopathic; injury/infection; internal resorption (local) and amelogenesis imperfect, fluorosis; drugs, eg. Tetracycline (11). The reason for discoloration within dentine includes caries; internal resorption; metallic restorative materials; necrotic pulp tissue; root canal filling materials (locally) and bilirubin (neonatal haemolytic diseases); congenital porphyria; dentinogenesis imperfecta; drugs, eg. Tetracycline (systemically) (12,13). Internalized discoloration is the incorporation of extrinsic stain within the tooth substance following dental development. It is most commonly observed in enamel defects and in the porous surface of exposed dentine. The pigments may then become internalized as developmental defects or acquired defects (14).

### Green Teeth (Chlorodontia)

Green teeth are an uncommon condition that is associated with bilirubin deposits in dental hard tissues, decomposed hemoglobin (15) and inorganic elements like calcium, sodium, magnesium, potassium, silicon, phosphorous and other elements in small amounts. Discoloration can also occur due to incomplete removal of obstructing material and sealer remnants in the pulp chamber, containing metallic components (16, 17) (fig 1). Green stain is found mainly on the cervical surface of the anterior teeth of children and is a remnant of Nasmyth's membrane and accumulated food debris (18).



**Fig 1. Green-to-black stained deciduous teeth. Green pigmentation of teeth as a consequence of metals, drugs, microorganism or diseases**

### Green teeth due to extrinsic staining

#### Metals

Extrinsic staining of teeth may be associated with occupational exposure to metallic salts, drugs containing metal salts, dissolution of metal ions from orthodontic appliances and other dental materials in artificial saliva (19-22). Mercury and lead dust causes a blue-green stain; copper and nickel, green-to-blue-green stain. Sometimes mouthrinses also cause a green stain due to copper salts (6).

Staining of the teeth by copper was reported earlier but seems to have been neglected in the recent literatures. Copper and copper containing salts produce a green tooth discoloration (23,24). Previously researchers described the development of green surface when exposed intermittently to brass fumes containing approximately 75% copper and lead upto 5%. The green pigmentation was ascribed to the absence of respiratory protection in the knock-out process accompanied by a rising level of metal concentration which served as a warning for brass foundry workers (25). In dentistry copper cements comprising of zinc phosphate and 2% to 97% copper gained popularity due to its germicidal potency. Copper ions possess antibacterial effect both *in vitro* and *in vivo* (26,27). Furthermore, it diminishes the number of bacteria on tooth surfaces (28). Contrastingly, copper cements are rendered being toxic. The adverse effect of copper is mainly due to the chemical form of copper used in the cement and its release into circulation. Solubility is directly related to released metal ie Cupric oxide > cuprous oxide > cuprous iodide. Ames black copper cement (97% cupric oxide) exhibits toxicity higher than Caulk's white copper cement with 2% cuprous oxide (29,30).

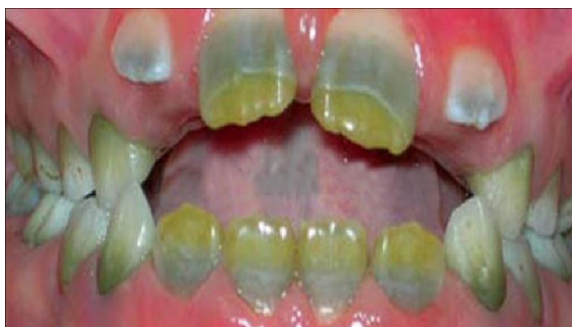It was previously thought that the mechanism of stain production was related to the production of the sulfide salt of the particular metal involved or corrosion process (31-33). This is presumed to be due to the extrinsic stain coincided with the color of the sulfide of the metal concerned. However, in proposed hypothesis chemical process necessary to produce a metal sulfide was not considered.

Subsequently, researchers evaluated the effect of color change in dental amalgam due to artificial demineralization (34-37). Detailed investigation on the surfaces of tooth under optical microscopy revealed the penetration of black pigments in dentin underneath both high copper and low copper amalgams in demineralized specimens. Furthermore, studies describe the uneven distribution of black deposits predominantly in dentin near to pulp horns and extended into the outer demineralized dentin (38). However, bluish-green discoloration was evenly distributed underneath all high-copper amalgam specimens independent of demineralization (39). Subsequently, earlier investigators probed the possible etiologies for tooth discoloration. The reasons include the amino-acids released during proteolysis as per chelation theory of cavity formation (40), the sugar-protein reaction or Maillard reaction or non-enzymatic browning (41) and presence of melanin (42).

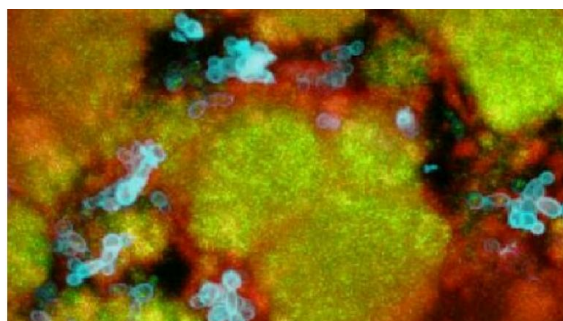
### Chromogenic bacteria

Chromogenic stains are a type of extrinsic stains of the teeth which are seen in children and these stains can sometimes be intrinsic if the bacteria affect the tooth during the stages of development. Chromogenic stains are often observed in the incisal edges. In the fig 2 the incisal edges of the teeth are green and the middle third of the teeth is black. Green pigmentation is due to chromogenic bacteria and the black stain seen in adults is as a result of accumulation of plaque, chlorhexidine, tobacco, stannous fluoride etc (43). Chromogenic bacteria cause stains mostly when the child has received liquid amoxicillin for a prolonged period of time. These bacteria stain the teeth yellow, green or orange in newly erupted teeth of the children (44).

Green strains are attributed to fluorescent bacteria as well as fungi such as *Penicillium* and *Aspergillus* species (Fig 3). The organisms grow only in light and therefore cause staining on the maxillary surface of the anterior teeth. Fusayama *et al.* (45) depicted that discoloration precedes the bacterial penetration of demineralized dentine and it seems that the discoloration is caused by compounds diffusing ahead of the bacteria. However, Kleter *et al.* (46) have suggested that it may be due to the Maillard reaction or formation of melanin or lipofuscin if there exists no relationship between the discoloration and either pigmented bacteria or metal ions. This report was validated through the evidence that bacterial irritation to the pulp may cause tissue necrosis which in turn releases disintegrated by-products that penetrate the tubule and discolor the dentine. eg. Heme, a by-product of hemolysis discolors dentine by combining with pulp tissue to form iron sulfide (15). Fungal infections are infections caused mainly by a microorganism named fungus that occurs in both young and old with weakened immune systems. The possible factors that lead to infections are immunosuppressant, HIV/AIDS, steroids and cancer chemotherapy. Due to surplus availability of glucose in diabetics they are more prone to the fungal infections as the elevated blood sugar provides nutrition for fungal overgrowth (47).



**Fig 2. Green discoloration of teeth due to chromogenic bacteria. Green and orange stains are observed due to the presence of chromogenic bacteria**



**Fig 3. A cross section of the biofilm *S. mutans* microcolonies (in green) together with *C. albicans* (in blue), surrounded and enmeshed in an extracellular polysaccharides matrix (in red). Fungi and bacteria act synergistically to cause tooth discoloration in toddlers**

Long term use of antibiotics may also pave way for fungal infections as antibiotics will cause alteration in the microbes of mouth, vagina and intestines. eg. Extracellular polysaccharides produced by exoenzymes of *S. mutans* utilizing sugar and glue like polymer produced by *Candida* contributes together to the

formation of bulk and teeth discoloration (48). *Pseudomonas* species also causes green discoloration of teeth due to the release of pyocyanin pigment and often co-exists with *Candida* and *Aspergillus* (49).

### Green teeth due to intrinsic discoloration

Intrinsic green discoloration of teeth is considered to be rare and the majority of reports are related to the primary dentition. Moreover, appearance of greenish tooth discoloration which may be as a result of immunosuppressive drugs in patients with a liver transplant, or antibiotics acts as a noxious stimuli to the patient and may lead to apprehension among the family members. Therapeutics and management of greenish discolored teeth remains unexplored and presumed to be more complicated. Herein, clear explanation is given in order to reduce the anxiety in the patient and to aid the dentist with appropriate dental management techniques.

### Intrinsic Green Teeth discoloration due to Drugs

Triple antibiotic paste (TAP), a mixture of ciprofloxacin, metronidazole and minocycline first used by Sato *et al.* (1996) is very effective in eliminating endodontic pathogens in vitro and in vivo. TAP is commercially available as 3 MIX MP (metronidazole (500 mg), minocycline (100 mg) and ciprofloxacin (200 mg) at a ratio of 1:1:1 (50). Minocycline is a semisynthetic analogue, and a second-generation derivative of tetracycline introduced into clinical practice during 1967 for tetracycline resistant inflammatory acne in adolescents and adults (51-54). Evidences suggest that the ingestion of minocycline leads to a green-gray intrinsic staining of teeth in the erupted permanent dentition and bone (55). Minocycline 100 mg/day can cause discoloration within one month after initiation of therapy in 3-6% of patients. Pigmentation occurs in bone due to accumulation of an insoluble quinone released due to the degradation of aromatic ring of the drug. However, the exact mechanism of staining in erupted teeth remains unclear. Contrastingly, greenish discoloration due to minocycline is localized to the middle or middle and incisal thirds of the crown in comparison with other tetracyclines (56). Additionally, Minocycline is a poor chelator of calcium ions but bind to iron ions. This interaction causes the formation of insoluble salts that are exuded from gingival crevicular fluid to either extrinsically stain the enamel or intrinsically. The affected teeth do not fluoresce under ultraviolet light, suggesting that the drug may be present as an iron-binding oxidized polymer, rather than as the calcium-bound, unchanged drug (57-59).

### Mechanism of teeth discoloration by Minocycline

Four theories that explains the mechanism of discoloration includes

- Extrinsic theory, minocycline attaches to the glycoprotein in acquired pellicle, oxidizes on exposure to air or as a result of bacterial activity resulting in the degradation of the aromatic ring forming insoluble black complex. The pigment then gets incorporated into the dentin by a demineralization/remineralization phenomenon.
- Intrinsic theory, minocycline bound to the plasma proteins gets deposited in collagen-rich matrix, such as the teeth

which then oxidizes slowly over time with exposure to light.

- Chelation, minocycline binds specifically with iron and forms insoluble complex.
- Deposition in dentine, minocycline deposits in dentin during secondary dentinogenesis and process gets accelerated in bruxists (60-63)

Ciprofloxacin, a fluoroquinolone is a broad spectrum, bactericidal antibiotic given intravenously to infants at dosages of 10 to 40 mg/kg/day to treat infections with *Klebsiella* (64). The drug targets topoisomerases in bacteria. Ciprofloxacin causes greenish discoloration of the teeth (65,66). Discoloration or staining is directly related to the age of patient, dose and duration of the drug administered. Nevertheless, mechanism involved in greenish discoloration remains uncertain (67).

### Green teeth as a complication of hyperbilirubinemia - Metabolic disorders

#### Hyperbilirubinemia

The elevated bilirubin in neonates due to certain diseases gets incorporated into developing teeth and causes yellow-green discoloration within the dental hard tissue (68-69). Bilirubin (haematoidin) is the yellow breakdown product of normal heme catabolism. Heme in hemoglobin is a prime component of red blood cells. The elevated level of bilirubin is indication of diseases. Normally, bilirubin is excreted in bile and urine, and is responsible for the background straw-yellow color of urine and the brown color of feces due to its end products urobilin and stercobilin. Hyperbilirubinemia causes accumulation of bilirubin pigment within the skin and mucous membranes that manifests as yellow pigmentation (70). In the newborn, jaundice is visible on the face at a serum bilirubin level of about 5 mg/dL; it progresses caudally as the level increases. When bilirubin levels are elevated for numerous days, bilirubin pigments gets deposited all over the body, including the teeth. Histological evaluation of green-stained deciduous teeth from patients with hyperbilirubinemia has confirmed the deposition of bilirubin. Intrinsic staining of primary teeth may vary in color from yellow to green. The removal of stain in the soft tissues takes place gradually. Nevertheless, in the hard dental tissues, the pigment becomes entangled due to deficient metabolic activity producing permanent staining (71) (Fig. 4).

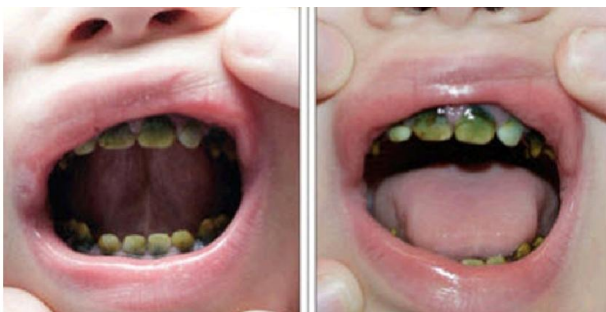

Fig 4. Green Teeth in a Child with Hyperbilirubinemia.

Neonatal hyperbilirubinemia occurs in about 60% of newborns during the first week of life. On the contrary, the prevalence of green-stained teeth associated with hyperbilirubinemia remains

unidentified. So far, 50 cases of green discoloration of teeth have been reported, mostly in the dental literature. Most of these cases occurred in children with hyperbilirubinemia secondary to biliary atresia. This clearly indicates the possible role of direct hyperbilirubinemia in the pathogenesis of green-stained teeth. The conjugated bilirubin being water soluble gets incorporated into the developing dentition (72,73). Less common causes of green-stained teeth associated with hyperbilirubinemia include Rh and ABO incompatibilities. About 48 children with green-stained teeth secondary to hyperbilirubinemia were diagnosed, the mean duration of jaundice and maximum serum total bilirubin level were found to be 24.6 weeks and 20- 90 mg/dL, respectively. Although discoloration was observed in permanent dentition primary teeth remained mostly affected. Often, a sharp dividing line separated the normal-colored tooth from the green discolored tooth (68,71,72). The eruption of the first tooth is a much anticipated milestone in the developing child and green discolored tooth can result in mental agony for parents. Thus, it becomes mandatory to provide proper guidance to families of children with severe hyperbilirubinemia. The evidences strongly support the fact that hyperbilirubinemia causes reversible staining of all tissues except the teeth (73). Treatment options include bleaching techniques; composite resin restorations and transillumination with UV light (74).

#### Chronic liver disease

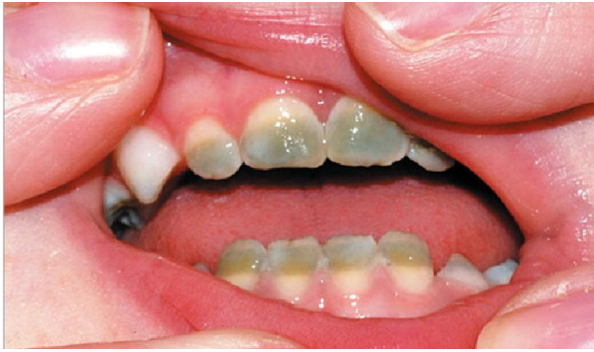Liver transplantation is becoming a widely accepted treatment for children with end-stage liver disease that have vastly improved as a consequence of advances in surgical techniques, improved postoperative care, and mostly due to the use of cyclosporine as an effective immunosuppressant drug. The primary causes for liver transplantation include chronic liver diseases like metabolic disorders, biliary hypoplasia, atresia and acute liver failure. The green-stained tooth is commonly observed in the oral cavity of these patients. Additionally, intrinsic tooth discoloration is reported in patients with blood dyscrasias such as sickle cell anemia, thalassemia, and hemolytic disease of the newborn. These diseases have the potential to cause hemolysis and the subsequent dose-dependent incorporation of biliverdin (by-product pigment of bilirubin) into developing teeth that leads to jaundice like yellow-green tint on the tooth surfaces (73-75).

#### Pathogenesis

The acquired pellicle is a microscopically thin layer of salivary glycoproteins that forms the surface coating of erupted tooth and offers acid resistance, lubrication and remineralization, which in turn facilitates the adherence of chromogenic (or colour-producing) materials to the tooth's surface (76). During odontogenesis, teeth may become discolored from the changes in the quality or quantity of enamel or dentin, or from the incorporation of discoloring agent into the hard tissues. Post-eruption discoloration occurs when the discoloring agent enters the hard tissues and originates from the pulp or the tooth surface (77).

The diseases that have the potential to cause neonatal hyperbilirubinemia or sepsis due to severe infections may cause green discoloration due to the incorporation of bilirubin/

pathogenic microorganisms into developing teeth (fig 5) within the dental hard tissue known as chlorodontia (75,76).



**Fig 5. Chlorodontia due to sepsis. Green Teeth due to severe infection (Neonatal Sepsis).**

The calcification of primary teeth starts during second trimester of intrauterine life and continues until the calcification of second molars. If there are too much bilirubin and biliverdin pigments in the blood, a change in tooth color might occur due to its invasion in the dentin and/or enamel formation. Many specific reciprocal interactions govern dentin and enamel formation which differs in mechanism. The odontoblast usually synthesizes and secretes the organic collagen-rich dentin matrix that subsequently mineralizes while the ameloblasts secretes a poorly mineralized matrix until the end of the secretory phase of amelogenesis. Subsequently, ameloblasts degrades its entire organic matrix to allow the increasing of the enamel mineral content during the maturation phase of amelogenesis. Thus, it is conceivable that the green pigment was deposited into dentin as it was secreted by odontoblasts (77-78,112).

#### **Treatment of Green Teeth discoloration**

Treatment of green pigmented teeth is mainly cosmetic. Recently, esthetics is considered as essential as function. The appearance of discoloration in dentition is of major concern to mankind and craves for dental treatments. Hence, deterrence of preventable causes of tooth discoloration must be a priority issue for the dentist. Appropriate therapy of discolored primary dentition will eventually lead to the normal permanent teeth. As children's age advances dental management improves self-esteem and confidence. Treatment options include vital and non-vital bleaching, micro abrasion, composite and porcelain veneers, and porcelain crowns. These treatments are combined at times for a more successful effect. Bleaching and composites /crowns are the techniques used for stained primary or permanent dentition (79-81).

#### **Bleaching**

Dental bleaching or tooth whitening is a most commonly used method in dentistry (82-83). Whitening restores natural tooth color and bleaching whitens and improves the natural color (FDA). Tooth bleaching has been an age old remedy. In ancient days Romans utilized milk and urine of goat to brighten and whiten the teeth. Bleaching is followed with bleaching gel, pen, strips or laser bleaching (84-85). Bleaching methods contains carbamides which react with water to form hydrogen peroxide. The peroxides remove

the stain by perforating the pores of the enamel. Power bleaching uses light to accelerate the process of bleaching in a dental office. Nowadays, 6-phthalimido peroxy hexanoic acid (PAP) is being used as bleaching agent (86). The mechanism of bleaching by hydrogen peroxide is unclear. The possible mechanism includes hemolytic cleavage of O-H or O-O bond in hydrogen peroxides to release hydroxyl radical (HO), perhydroxyl radicals (HOO-), perhydroxyl anions (HOO-), and superoxide anions (OO-). The photochemical reactions due to light or lasers, augments the release of these radicals from hydrogen peroxide(87-89). Hydrogen peroxide being an oxidizing agent releases oxygen in the form of unstable free radicals and causes disintegration of the conjugated double bonds in the chromophore to form a single bond that is flushed out by water which thereby facilitates the removal of pigments that cause tooth discoloration(90-91). The entire process will in turn lead to a shift in the absorption spectrum of pigment and results in tooth whitening( 92 -93). Bleaching can be either carried out externally (night guard bleaching or vital tooth bleaching), or intracoronally in root-filled teeth (non-vital tooth bleaching) (94).

#### **Non-Vital bleaching**

Non-Vital bleaching dates back to 19<sup>th</sup> century using chloride of lime. The non-vital bleaching procedures commonly practiced are i) 'walking bleach and modified walking bleach'; ii) non-vital power bleaching, also known as 'thermo/photo bleaching'; and iii) 'Inside/outside bleaching (79,80,95). This technique is indicated for non-vital, endodontically treated teeth that are discoloured due to the deposition of blood degradation products in the dentinal tubules and is based on usage of either hydrogen peroxide or both hydrogen peroxide and sodium perborate (*Bocasan*) (96).

#### **Vital Bleaching**

Vital Bleaching involves the external application of hydrogen peroxide to the surface of the tooth followed by thermal stimulation(93,97). It is primarily used for mild tetracycline staining without obvious banding and single teeth with sclerosed pulp chambers and root canals(98-99).Tetracycline stained teeth can be bleached with 10% Carbamide peroxide that ensures stability even after 3 months of treatment(100). *In vitro* studies imply that accumulation of blood forming pigments hemoglobin and/or hematin molecules precipitates discoloration of teeth. Bleaching agents have demonstrable benefits in the removal of teeth stain specifically caused by blood pigment (101).

#### **Veneers**

Dental veneers (sometimes called porcelain veneers or dental porcelain laminates) are wafer-thin, customized shells of tooth-color materials designed to cover the front surface of teeth to improve the appearance. These shells are bonded to the front of the teeth changing their color, shape, size, or length (102). The advantages of veneers includes: a natural tooth appearance, Gum tissue tolerance and resistant to the stains. The color of a veneer can be chosen such that it makes dark teeth appear whiter and offer a conservative approach to changing a tooth's color and shape; veneers generally don't

require the extensive shaping prior to the procedure that crowns do and is most preferred aesthetic alternative (103). However, there are demerits as the process is irreversible, and irreparable. Veneers are expensive than composite resin bonding. Due to the removal of enamel, tooth may become more sensitive to hot and cold foods and beverages. Sometimes, veneers may not exactly match the color of the other teeth and cannot be altered once it is placed. Veneers will have to be replaced every 5 years as it does not last longer (104). Veneers are used in tetracycline staining (105).

### Porcelain Veneers

Porcelain veneers are indicated for hypoplastic and discoloured teeth in patients aged 16 years and above, when techniques such as microabrasion, non-vital bleaching and composite resins have failed to produce a satisfactory clinical results (105).

### Microabrasion

Microabrasion is based on the elimination of a considerable amount of surface enamel and incorporating 'abrasion' and 'erosion' together with dental instrument and an acid mixture. The two main techniques available for microabrading discolored or hypoplastic teeth are hydrochloric acid/pumice technique, which requires very careful isolation of the affected teeth, and the phosphoric acid/pumice technique. Microabrasion is mostly indicated for fluorosis, post-orthodontic demineralization, localized hypoplasia due to infection or trauma, and idiopathic hypoplasia wherein the discoloration is limited to the outer enamel layer (106-107). Tetracycline discoloration is removed by combined treatment modality in which the teeth are bleached after the preparation for porcelain laminate veneers (108). However, for minocycline staining a wide variety of treatment options is available. The different modalities of esthetic treatment available for managing such discolored teeth include vital bleaching, microabrasion, composite/ceramic veneers or ceramic crown (109-112).

### Conclusion

Identification of the possible etiologies of green discoloration of teeth is prime need to achieve the satisfactory cosmetic outcome. A detail investigation was carried out to enumerate the pathological processes involved in green discoloration of teeth. The evidences from previous literatures suggest that possible factors involved in green staining are hyperbilirubinemia, drugs, metals and heme products. Hence, it is vital to consider these aforementioned factors for a complete evaluation of the impact of the chromogens on the teeth. Based on the causes appropriate dental management techniques are referred in this review which may render useful to dentist and patient.

### REFERENCES

1. Sruthy Prathap, H. Rajesh, Vinitha. A. Bolor and Anupama. S. Rao. Extrinsic stains and management: A new insight. *JAIR*, 2013; 1(8) 435-442.
2. Wright JT. Anatomy and development of the teeth. Up-To-Date [electronic database]. Rose BD, editor. Waltham (MA); 2007.
3. Kwno SR, Ko SH, Greenwall LH, Goldstein RE, Haywood VB. Tooth whitening in esthetic dentistry: principles and techniques. 1ST Ed. London: Quintessence Publishing Co; 2009.
4. Sulieman MA. An overview of tooth-bleaching techniques: chemistry, safety and efficacy. *J Periodontol.*, 2000; 48:148-169.
5. Watts A, Addy M. Tooth discoloration and staining: a review of the literature. *Brit Dent J.*, 2001; 190:309-16.
6. Manuel ST, Abhishek P, Kundabala, S. Etiology of tooth discoloration-a review. *Bioinformatics and Data Mining Studies in Oral Genomics and Proteomics. Open Dent J.*, 2010; 18(2): 56-63.
7. Thylstrup A, Ferjerskov O. Clinical and pathological features of dental caries. In: Textbook of clinical cariology. 2nd ed. pp 130-136. Copenhagen: Munksgaard, 1995.
8. Addy M, Moran J. Mechanisms of stain formation on teeth, in particular associated with metal ions and antiseptics. *Adv Dent Res.*, 1995; 9: 450-456.
9. Hattab FN, Qudeimat MA, al-Rimawi HS. Dental discoloration: an overview. *Int J Esthet Dent*, 1999; 11(6):291-310.
10. Addy M, Roberts WR. Comparison of the bisbiguanide antiseptics alexidine and chlorhexidine. II: Clinical and in vitro staining properties. *J Clin Periodontol.*, 1981; 8: 220-23.
11. Kadam A, Ganachari M, Mahendra Kumar B, Gurunath S. Drug Induced Tooth Discolouration. *IJDS*. 2008; 7.
12. Link J. Discolouration of the teeth in alkaptonuria and Parkinsonism. *The Chronicle: The Omaha District Dental Society Journal*, 1973; 36: 136.
13. Fayle SA, Pollard M A. Congenital erythropietic porphyria-oral manifestations and dental treatment in childhood: a case report. *Quintessence Int.*, 1994; 25: 551-554.
14. Joseph A, Regezi James, Sciubba J, Richard C.K, Jordan S. Oral Pathology: Clinical Pathology correlations. Sixth Edition, 2012.
15. Marin PD, Bartold PM, Heithersay GS. Tooth discoloration by blood: An in vitro histochemical study. *Endod Dent Traumatol* 1997; 13:132-138.
16. Parsons JR, Walton RE, Ricks-Williamson L. In vitro longitudinal assessment of coronal discoloration from endodontic sealers. *J Endod.*, 2001; 27:699-702.
17. Partovi M, Al-Havvaz AH, Soleimani B. In vitro computer analysis of crown discoloration from commonly used endodontic sealers. *Australian Endodontic Journal*, 2006; 32:116-119.
18. Rakauskaitė A, Juodzbalys G, Pauza DH, Cicciu M. Green pigmentation in human teeth. A stereomicroscopic study. *J Clin Pediatr Dent*, 2014;38(4):355-61
19. Hwang CJ, Shin JS, Cha JY. Metal release from simulated fixed orthodontic appliances. *Am J Orthod Dentofacial Orthop.*, 2001; 120:383-391.
20. Schmalz G, Garhammer P. Biological interactions of dental cast alloys with oral tissues. *Dent Mater*, 2002; 18(5):396-406.

21. Kerosuo H, Moe G, Kleven E. In vitro release of nickel and chromium from different types of simulated orthodontic appliances. *Angle Orthod.*, 1995;65: 111–116.
22. Marcin Mikulewicz, Katarzyna Chojnacka, Barbara Woźniak, Patrycja Downarowicz. Release of Metal Ions from Orthodontic Appliances: An In Vitro Study. *Biological Trace Element Research*, 2012; 146:272–280.
23. Kuhta M, Pavlin D, Slaj M, Varga S, Lapter-Varga M, Slaj M. Type of archwire and level of acidity: effects on the release of metal ions from orthodontic appliances. *The Angle Orthodontist* 2009; 79:102–110.
24. Gursoy S, Acar AG, Seşen C Comparison of metal release from new and recycled bracket–archwire combinations. *The Angle Orthodontist* 2004; 75:92–94
25. Donoghue AM, Ferguson MM. Superficial copper staining of the teeth in a brass foundry worker. *Occupational Medicine (Lond)* 1996; 46(3):233-4.
26. Orstavik D. Antibacterial properties and element release from some dental amalgams. *Acta Odontology of Scandnavia*, 1985; 43(4) 231-239.
27. Morrier J J, Suchett-Kaye G, Nguyen D, Rocca JP, Blanc- Benon J, Barsotti O. Antimicrobial activity of amalgams, alloys and their elements and phases. *Dental Materials*1998; 14(2) ;150-157.
28. Foley J, Blackwell A. In vivo cariostatic effect of black copper cement on carious dentine. *Caries Research*, 2003;37(4): 254-260.
29. Christensen, Gordon J, Achieving optimum retention for restorations. *The Journal of American Dental Association*, 2004; 135(8):1143-45.
30. Rosalen PI, Bowen WH, Pearson SK. Effect of copper co-crystallized with sugar on caries development in desalivated rats. *Caries Research*, 1996; 30(5): 367-372
31. Ludek Joska, Zora Venclikova, Macela Poddana, Oldrich Benada. The mechanism of gingiva metallic pigmentations formation. *Clinical Oral Investigations* 2009; 13(1): 1-7.
32. Venclikova Z, Benada O, Bartova j, Joska L, Mrklas L, Prochazkova J, Stejskal V, Podzimek S. In vivo effects of dental casting alloys. *Neuro Endocrinology Letters*, 2006; 27:61-8.
33. Szykowska MI, Sokolowski J, Rogowski J, Nagrodzka A, Leśniewska E, Albińska J, Pawlacyk A, Samlik-Fronc I. ICP-TOF-MS, TOF-SIMS and AAS studies of corrosion resistance of dental alloys. *Przemysł Chemiczny*, 2010; 89:554–557.
34. Osborne JW. Dental amalgam and mercury vapor release. *Advances in Dental Research*, 1992; 6:135–138.
35. Lorscheider FL, Vimy MJ, Summers AO. Mercury exposure from “silver” tooth fillings: emerging evidence questions a traditional dental paradigm. *Federation of American Societies for Experimental Biology*, 1995; 9:504–508
36. Dental Amalgam: A Scientific Review and Recommended Public Health Service Strategy for Research, Education, and Regulation. Washington, DC. US Department of Health and Human Services, Committee to Coordinate Environmental Health and related Programs, US Public Health Service; 1993
37. Lenherr P, Allgayer N, Weiger R, Filippi A, Attin T, Krastl G. Tooth discoloration induced by endodontic materials: A laboratory study. *International Endodontic Journal*, 2012; 45:942-9.
38. Kidd EAM, Joyston-Bechal S, Smith MM. Staining of residual caries under freshly packed amalgam restorations exposed to tea/chlorhexidine in vitro. *International Dental Journal*, 1990; 40: 219-224.
39. Livingston HM, Dellinger TM. Intrinsic staining of teeth secondary to tetracycline. *Annals of Pharmacotherapy*, 1998; 32:607.
40. Banting D W. Management of dental caries in the older patient. In: Geriatric dentistry. pp 141-167. Chicago: Mosby Year Book, 1991.
41. Driezen S, Spies T D. A note on the production of a yellow-brown pigment in the organic matrices of noncarious human teeth by oral lactobacilli. *Oral Surgery Oral Medicine Oral Pathology*, 1950; 3: 686-691.
42. Kleter GA, Damen JJM, Buijs MJ, Ten Cate JM. Modification of amino acid residues in carious dentin matrix. *J Dent Res.*, 1998; 77: 488-495.
43. Hattab F N, Qudeimat M A, al- Rimawi H S. Dental discoloration: an overview. *Journal of Esthetic Dentistry*, 1999;11(6):291-310.
44. Varun. Green and Orange stains on teeth due to chromogenic Bacteria: [www.juniordentist.com](http://www.juniordentist.com). December 23, 2012.
45. Fusayama T, Okuse K, Hosoda H. Relationship between hardness, discoloration, and microbial invasion in carious dentine. *J Dent Res.*, 1996;45: 1033-1046.
46. Kleter GA, Damen JJM, Buigus MJ. Modification of amino acid residues in carious dentine matrix, *J Dent Res.*, 1998; 77: 488-495.
47. Marijke Vroomen-Durning, <http://www.everydayhealth.com/type-2-diabetes/type-2-diabetes-and-fast-food.aspx>. 2014
48. Washington DC. Bacterium and fungus team up to cause virulent tooth decay in toddlers. <http://www.asm.org/index.php/journal>. March 12, 2014.
49. Harmon T, Burkhardt G, Applebaum H. Perforated pseudomembranous colitis in the breast-fed infant. *Journal of Pediatric Surgery*, 1992; 27: 744-746
50. Sato I, Ando-Kurihara N, Kota K, Iwaku M, Hoshino E. Sterilization of infected root-canal dentine by topical application of a mixture of ciprofloxacin, metronidazole and minocycline in situ. *International Endodontic Journal*, 1996; 29: 118-24.
51. Setien VJ, Roshan S, Nelson PW. Clinical management of discolored teeth. *General Dentistry*, 2008; 56(3):294-300.
52. Shetty AK. Tetracycline in pediatrics revisited. *Clinical Pediatrics*, 2001, 41: 203-209.
53. Siller GM, TOD MA, Savage NW. Minocycline induced pigmentation. *Journal of the American Academy of Dermatology*, 1994; 30: 350-54.
54. Josephine M. Cockings, Neil W. Savage. Minocycline and oral pigmentation. *Australian Dental Journal*, 1998;43(1):14-16
55. Parkins FM, Furnish G, Bernstein M. Minocycline use discolours teeth. *Journal of the American Dental Association*, 1992; 123: 87-89.

56. Kim JH, Kim Y, Shin SJ, Park JW, Jung IY. Tooth discoloration of immature permanent incisor associated with triple antibiotic therapy: A case report. *J Endod.*, 2010; 36: 1086-911.
57. Kirchhoff AL, Raldi DP, Salles AC, Cunha RS, Mello I. Tooth discoloration and internal bleaching after the use of triple antibiotic paste. *International Endodontic Journal*, 2014 Dec 17. doi: 10.1111/iej.12423. [Epub ahead of print]
58. Odell EW, Hodgson RP. Oral presentation of minocycline induced black bone disease. *Oral Medicine Oral Pathology Oral Radiology*, 1995; 79: 459-61.
59. Kelly RG, Kanegis LA. Metabolism and tissue distribution of radioisotopically labeled minocycline. *Toxicology and applied Pharmacology* 1967; 11:171-83.
60. Ayanco L, Sheridan PJ. Minocycline-induced staining of torus palatines and alveolar bone, *J Periodontol.*, 2003; 74:669- 77.
61. Patel K, Cheshire D, Vance A. Oral and systemic effects of prolonged minocycline therapy. *Br Dent J.*, 1998; 185:560-562.
62. McKenna BE, Lamey PJ, Kennedy JG, Bateson J. Minocycline-induced staining of the adult permanent dentition: a review of the literature and report of a case. *Dental Update* 1999; 26:160-162.
63. Good ML, Hussey DL. Minocycline: stain devil? *British Journal of Dermatology* 2003; 149:237-239.
64. Gendrel D, Chalumeau M, Moulin F. Fluoroquinolones in paediatrics: a risk for the patient or for the community? *Lancet Infectious Disease* 2003; 3: 537 – 46
65. Abiodun Adefurin, Helen Sammons, Evelyne Jacqz-Aigrain, Imti Choonara. Ciprofloxacin safety in paediatrics: A systematic review. *Archives of Diseases in Childhood* 2011; 96:874–880.
66. Tredvin CJ, Scully C, Bagan- Sebastian JV. Drug induced disorders of teeth: *J Dent Res.*, 2005; 84(7) :596-602.
67. Mandras N, Roana J, Allizond V, Pasqualini D, Crosasso P, Burlando M, Banche G, Denisova T, Berutti E, Cuffini AM. Antibacterial efficacy and drug-induced tooth discoloration of antibiotic combinations for endodontic regenerative procedures. *International Journal of Immunopathology and Pharmacology*, 2013; 26(2):557-63.
68. Amaral TH, Guerra C de S, Bombonato-Prado KF, Garcia de Paula E Silva FW, de Queiroz AM. Tooth pigmentation caused by bilirubin: a case report and histological evaluation. *Special Care in Dentistry*, 2008; 28(6): 254-57.
69. Guimarães LP, Silva TA. Green teeth associated with cholestasis caused by sepsis: a case report and review of the literature. *Oral Surg Oral Med Oral Pathol.*, 2003; 95:446-451.
70. Rosenthal P, Ramos A, Mungo R. Management of children with hyperbilirubinemia and green teeth. *J Pediatr.*, 1986; 108:103-105.
71. Watanabe K, Shibata T, Kurosawa T, Morisaki I, Kinehara M, Igarashi S, Arisue M. Bilirubin pigmentation of human teeth caused by hyperbilirubinaemia. *J Oral Pathol Med.*, 1999; 28: 128-30.
72. Battineni S, Clarke P. Green teeth are a late complication of prolonged conjugated hyperbilirubinemia in extremely low birth weight infants. *J Pediatr dent*, 2012 ;34(4):103-6.
73. Sommer S, Magagnin K, Kramer PF, Tovo MF, Bervian J. Green teeth associated with neonatal hyperbilirubinemia caused by biliary atresia: review and case report. *J Clin Pediatr Dent*, 2010; 35(2):199-202
74. Kamaldeep Arora, Rashmi Ranjan Das. Ramesh Agarwal. Green Pigmented Teeth. *Indian Pediatrician Journal*, 2012; 49:1015
75. Baerg J, Zuppan C, Klooster M. Biliary atresia- a fifteen-year review of clinical and pathologic factors associated with liver transplantation. *J Pediatr Surg.*, 2004;39(6):800-3.
76. Cohen ES, Burns R. *Pathways of the Pulp*. 7<sup>th</sup> ed. Mosby: St. Louis, Mo; 1998.
77. Farmer ED, Lawton FE. Stains and Discoloration of the Teeth. In: *Stones oral and dental diseases*. 5th ed. pp511-527. Edinburgh and London: ES. Livingstone, 1966.
78. Alfredo Carrillo, Karla Mayra Pinto E, Carvalho Rezende, Shirley Rodas de Carrillo, Victor E, Arana-Chavez, Marcelo Bonecker. Hyperbilirubinemia and intrinsic pigmentation in primary teeth: a case report and histological findings. *Pediatr Dev Pathol.*, 2011; 14(2):155-6.
79. Haywood Van, B., Houck, V.M., Heymann, H.O. Nightguard Vital Bleaching. Effects of Various Solutions on Enamel Surface Texture and Colour. *Quintessence Int* 1991; 22: 775-782
80. Haywood Van, B., Houck, V.M., Heymann, H.O. Effects of Various Nightguard Bleaching Solutions on Enamel Surfaces and Colour Change. *J Dent Res* 1991; 70: 377.
81. Leith R, Moore A, O'Connell AC. An effective bleaching technique for non-vital, discoloured teeth in children and adolescents. *Journal of the Irish Dental Association*, 2009; 55:184–9.
82. Keller M. *Dental bleaching*, 1ST Ed, London: Quintessence Publishing Co; 2008.
83. Plotino G, Buono L, Grande NM, Pameijer CH, Somma F. Nonvital tooth bleaching: a review of the literature and clinical procedures. *J Endod.*, 2008; 34: 394-407.
84. Nathanson, D. Bleaching Vital Teeth: A Review and Clinical Study. *Compendium of continuing education in dentistry VIII*, No. 7: 400-497
85. Pearson HH. Bleaching of the Discoloured Pulpless Teeth. *J Am Dent Assoc* 1958; 56: 64-68
86. Kellegher MGD, Roe FJC. The safety-in-use of 10% carbamide peroxide (Opalescence) for bleaching teeth under the supervision of a dentist. *Br Dent J.*, 1999; 187: 190-194.
87. Holmstrup, G., Palm, A.M., Lambjerg-Hansen, H. Bleaching of Discoloured Root-Filled Teeth. *Endod Dent Traumatol.*, 1988; 4: 197-201
88. Joiner 2006. The bleaching of teeth: a review of literature. *J Dent.*, 34, 412-19.
89. Tredwin CJ, Naik S, Lewis NJ, Scully C. Hydrogen peroxide tooth-whitening (bleaching) products: review of adverse effects and safety issues. *Br Dent J.*, 2006; 200:371-6.



90. Minoux and Serfaty. Vital tooth bleaching: biologic adverse effects – a review. *Quintessence Int* 2008; 39: 645-659
91. Dahl and Pallesen. Tooth bleaching- a critical review of the biological aspects. *Critical Reviews in Oral Biology & Medicine*, 2003; 14: 292-304.
92. Titley, K. The Effect of Concentration of Hydrogen Peroxide Solutions on the Surface Morphology of Human Tooth Enamel. *J Endod.*, 1998; 14(2): 69-73.
93. Robertson WB, Melfi RC. Pulpal Response to Vital Bleaching Procedures. *J Endod.*, 1980; 6: 645-649
94. Sulieman M. An overview of tooth discoloration: extrinsic, intrinsic and internalized stains. *Dental Update* 2005; 32:463-4
95. Haywood VB. History, safety and effectiveness of current bleaching techniques and application of the night guard vital bleaching technique. *Quintessence Int* 1992; 27: 471-488
96. Macey-Dove LV, Williams B. Bleaching of a Discoloured Non-Vital Tooth: Use of Sodium Perborate/Water Paste as the Bleaching Agent. *Int J Paediatr Dent.*, 1997; 7:35-38.
97. Cvitki E, Swift EJ, Denehy GE. Improved Esthetics with a Combined Bleaching Technique: A Case Report. *Quintessence Int* 1992; 23: 91-93.
98. Sciaky H, Drimmer. *Oral Surgery, Oral Medicine, and Oral Pathology* 1962; 15 (1): 91-98.
99. American Dental Hygienists Association. 1999. Oral Health Information: Tooth Whitening Systems. Retrieved from [http://www.adha.org/oral health/ whitening.htm](http://www.adha.org/oral%20health/whitening.htm).
100. Ayasilioglu E, Erkek, Oba AA, Cabeciogly E. Doxycycline-induced staining of permanent adult dentition. *Australian Dental Journal* 2005; 50(4): 273-75.
101. Anandhkumar G. Patil, Vinaykumar Hiremath R. Sheetal Kumar, Aparna Sheetal, Suresh Nagaral. Bleaching of a non-vital anterior tooth to remove the intrinsic discoloration. *Journal of Natural Science, Biology and Medicine*, 2014; 5(2): 476-479.
102. Kermanshah H, Borougeni AT, Bitaraf T. Comparison of the microshear bond strength of feldspathic porcelain to enamel with three ring resins. *Journal of Prosthodontic Research*, 2011; 55:110-6.
103. Barceleiro Mde O, De Miranda MS, Dias KR, Sekito T Jr. Shear bond strength of porcelain laminate veneer bonded with flowable composite. *Operative Dentistry*, 2003; 28:423-8.
104. Khatri A, Nandlal B. An indirect veneer technique for simple and esthetic treatment of anterior hypoplastic teeth. *Contemporary Clinical Dentistry*, 2010; 1:288-90.
105. Restorative indications for Porcelain Veneer Restoration. In 'National Clinical Guidelines' Royal College of Surgeons of England 1997.
106. Donly KJ, O'Neill MO, Cross TP. Enamel Microabrasion: A Microscopic Evaluation of the 'Abrasion Effect'. *Quintessence Int* 1992; 23: 175-178.
107. Fisher NL, Radford JR. Internal Bleaching of Discoloured Teeth. *Dental Update*, 1990; 110-114.
108. Sadan A, Lemon RR. Combining treatment modalities for tetracycline-discolored teeth. *International Journal of periodontics and Restorative Dentistry*, 1998; 18(6): 564-71.
109. ADA Council on Scientific Affairs. Antibiotic use in dentistry. *The Journal of American Dental Association*, 1997; 128:648. T
110. Ayasilioglu E, Erkek, ObaAA, Cabeciogly E, Doxycycline- induced staining of permanent adult dentition, *Australian Dental Journal*, 2005; 50(4) :273-75
111. Leonard RH Jr, Van Haywood B, Caplan DJ, Tart ND. Nightguard vital bleaching of tetracycline-stained teeth: 90 months post treatment. *Journal of Esthetic Restorative Dentistry*, 2003; 15(3):142-52.
112. Andraesen FM. Transient apical breakdown and its relation to colour and sensibility changes after luxation injuries to teeth. *Endodontics and Dental Traumatology*, 1986; 2: 9-19.

\*\*\*\*\*